



# 4<sup>th</sup> INDERCOS

**Dermatology and Cosmetology Congress  
with International Participants**

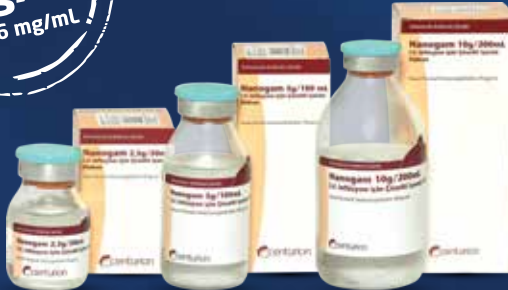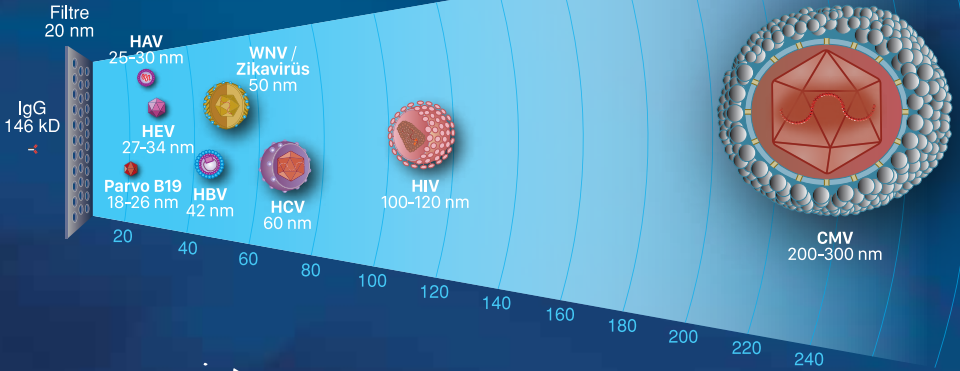
**27 - 30 MARCH, 2019**

**HILTON ISTANBUL BOSPHORUS HOTEL  
ISTANBUL, TURKEY**

***Botanical and Dietary Anti-aging Approaches in Dermatology***



*Scientific Program  
Lecture Summaries  
Oral Presentations  
Poster Presentations*





# 4<sup>th</sup> INDERCOS

## Dermatology and Cosmetology Congress with International Participants

27 - 30 MARCH, 2019  
HILTON ISTANBUL BOSPHORUS HOTEL  
ISTANBUL, TURKEY



### **Botanical and Dietary Anti-aging Approaches in Dermatology**

**Dear Colleagues,**

We are pleased to announce the 4th INDERCOS Congress, taking place 27-30 March 2019 in İstanbul - TURKEY. The main topics of this meeting will be "Botanical and Dietary Anti-aging Approaches in Dermatology". Through plenaries and parallel workshop sessions, we aim to share insights and experiences and discuss how advances in aesthetic dermatology. In order to success this, we have very distinctive international speakers with extensive experience and a range of expertise across aesthetic dermatology and dermatology. Cosmetic dermatology is growing increasingly common in today's society. The question "Are botanical and dietary anti-aging approaches effective in dermatology?" will be debated. Botanical extracts that support the health, texture, and integrity of the skin, hair, and nails are widely used in cosmetic formulations. New botanical skin care treatments are emerging, presenting dermatologists and their patients the challenge of understanding the science behind these cosmeceuticals. In some cases, dietary approaches can influence the course of the skin disease, as in acne. In others, dietary change could serve as one aspect of prevention, such as in skin cancer and aging of the skin. In others, dermatological disease may be linked to systemic disease, and dietary changes may affect health outcomes, as in psoriasis. Lastly, systemic medications prescribed for dermatological disease, such as steroids, retinoids are known to raise the risk of other diseases, and dietary change may reduce this risk. We hope you will be together with us in this fascinating, high quality scientifically educational congress and we look forward to your precious participation and feedback.

**Prof. Ümit Türsen**

*Co-President*

**Prof. Mustafa Atasoy**

*Co-President*



# 4<sup>th</sup> INDERCOS

Dermatology and Cosmetology Congress  
with International Participants  
27 - 30 MARCH, 2019  
HILTON ISTANBUL BOSPHORUS HOTEL  
ISTANBUL, TURKEY



## Organising Committees

**Ümit TÜRSEN (TR)**

*Co-President*

**Mustafa ATASOY (TR)**

*Co-President*

**Torello LOTTI (IT)**

*Vice President*

**Kemal ÖZYURT (TR)**

*Vice President*

**Ulaş GÜVENÇ (TR)**

*Secretary General*

**Belma TÜRSEN (TR)**

*Secretary General*

## Social Committees

**Ayşegül USTA GÜNEY (TR)**

*Chair*

**Hale APİ (TR)**

*Member*

**Koray ÖZKAN (TR)**

*Member*

## Oral Presentation and Poster Review Committees

*Chair*

**Mehmet Salih GÜREL (TR)**

*Members*

**Habibullah AKTAŞ (TR)**

**Necmettin AKDENİZ (TR)**

**Anıl Gülsel BAHALI (TR)**

**Deniz DEMİR SEREN (TR)**

**Özgür GÜNDÜZ (TR)**

**Emek KOCATÜRK GÖNCÜ (TR)**

**Mehmet MELİKOĞLU (TR)**

**Gaye SARIKAN (TR)**

**Erdiç TERZİ (TR)**

**Özgür TİMURKAYNAK (TR)**

**Zeynep TOPKARCI (TR)**

**Tuğba Kevser ÜSTÜNBAŞ (TR)**



# 4<sup>th</sup> INDERCOs

**Dermatology and Cosmetology Congress**  
**with International Participants**

27 - 30 MARCH, 2019  
HILTON ISTANBUL BOSPHORUS HOTEL  
ISTANBUL, TURKEY



## Scientific Committees

### *Chair*

**Torello LOTTI (IT)**

### *Members*

**Tilemachos ANTHOPOULOS (GR)**

**Ivana BINIC (CS)**

**Pertevniyal BODAMYALI (TRNC)**

**Valentina BROSHTILOVA (TR)**

**Victor Gabriel CLATICI (ROU)**

**Recep DURSUN (TR)**

**Katlein FRANÇA (USA)**

**Thomas HAWRO (GER)**

**Serhat İNALÖZ (TR)**

**Ayşe Serap KARADAĞ (TR)**

**Andreas KATSAMBAS (GR)**

**John KATSANTONIS (GR)**

**Tamer İrfan KAYA (TR)**

**Amor KHACHEMOUNE (USA)**

**Leon KIRCIK (USA)**

**Gudula KIRTSCHIG (DE)**

**Milanka LJUBENOVIC (SER)**

**Assel MARKABAYEVA (KZK)**

**Marcus MAURER (GER)**

**Bodo MELNIK (GER)**

**Martin METZ (GER)**

**Konstantin NEAMONITOS (GR)**

**Zoran NEDIC (CS)**

**Milos NIKOLIC (CS)**

**Kemal ÖZYURT (TR)**

**Mihael SKERLEV (CRO)**

**Hok Bing THIO (NL)**

**Ines VERNER (GER)**

**Alexandra VOJVODIC (SRB)**

**Omid ZARGARI (CA)**



SCIENTIFIC  
PROGRAM





# 4<sup>th</sup> INDERCOS

## Dermatology and Cosmetology Congress with International Participants

27 - 30 MARCH, 2019  
HILTON ISTANBUL BOSPHORUS HOTEL  
ISTANBUL, TURKEY



27 March 2019, Wednesday

Hall 1

08:30 - 08:45 Welcome speeches *Mustafa Atasoy, Ümit Türsen*

### Clinical Dermatology

08:45 - 10:00 Psoriasis

*Chairs: Omid Zargari, Sibel Alper*

08:45 - 09:00 Psoriasis and hidradenitis suppurativa: What they have in common? *Omid Zargari*

09:00 - 09:15 Psoriatic plaque and atheroma plaque. Is it possible to kill two birds with one stone? *Omid Zargari*

09:15 - 09:30 Nail psoriasis: Whats new? *Sibel Alper*

09:30 - 09:45 Integrative approach to psoriasis vulgaris *Milanca Lijubenovici*

09:45 - 10:00 Psoriasis and comorbidities: Links and risks *Erkan Alpsoy*

10:00 - 10:30 Coffee Break

10:30 - 12:00 General Dermatology -1

*Chairs: Milos Nikolic, Berna Aksoy*

10:30 - 10:45 Hamartomas in dermatology *Berna Aksoy*

10:45 - 10:55 Phantom sign on skin *Aslı Tatlıparmak*

10:55 - 11:10 Doping related skin diseases *Gül Yıldırım*

11:10 - 11:20 Urocanic acid in the skin: A mixed blessing *Aslı Tatlıparmak*

11:20 - 11:35 Treatment of severe forms of alopecia areata in children and adolescents *Milos Nikolic*

11:35 - 11:50 Systemic lupus erythematosus in children and adolescents *Milos Nikolic*

11:50 - 12:00 The metabolic syndrome related skin diseases *Ayşe Serap Karadağ*

12:00 - 13:30 Lunch



# 4<sup>th</sup> INDERCOS

## Dermatology and Cosmetology Congress with International Participants

27 - 30 MARCH, 2019  
HILTON ISTANBUL BOSPHORUS HOTEL  
ISTANBUL, TURKEY



27 March 2019, Wednesday

Hall 1

### 13:30 - 15:00 Treatment In Dermatology

*Chairs: Mehmet Melikoğlu, Zoran Nedic*

13:30 - 13:45	Azelaic acid in dermatology	Işıl Bulur
13:45 - 14:00	BCG/PPD/IFN $\gamma$ release assay in dermatology	Mehmet Melikoğlu
14:00 - 14:15	SADBE/DCP in dermatology	Murat Durdu
14:15 - 14:30	Use of podophyllin (podophyllum resin) and podophyllotoxin in dermatology	Zoran Nedic
14:30 - 14:45	Sirolimus and skin	Nida Gelincik Kaçar
14:45 - 15:00	Lentigo maligna; What's new in the treatment?	Gudula Kirtschig

### 15:00 - 15:15 Coffee Break

### 15:15 - 17:00 General Dermatology -2

*Chairs: Gamze Erfan, Zeynep Topkarcı*

15:15 - 15:30	Skin manifestations of eating disorders and drug addictions	Zeynep Topkarcı
15:30 - 15:45	Technology related skin diseases	Gamze Erfan
15:45 - 16:00	Cutaneous findings in the elderly	Ayşe Ferzan Aytağ
16:00 - 16:15	Patterns of hyperhidrosis and dermatological approaches	Pelin Kuteyla Can
16:15 - 16:30	Gustatory skin problems	Pelin Kuteyla Can
16:30 - 16:45	Sexual abuse: How can we know?	Özalp Ekinci
16:45 - 17:00	Discussion	

### 17:00 - 17:35 Oral Presentation - 1

*Chairs: Mehmet Melikoğlu, Zeynep Topkarcı*

17:00 - 17:05	<b>OP-01</b> Skin diseases in rural Nyala, Sudan (in a rural hospital, in 12 orphanages and in 2 refugee camps)	Melike Kibar Öztürk
17:05 - 17:10	<b>OP-02</b> A rare variant of cicatricial pemphigoid: Brunsting-perry type	Yunus Özcan
17:10 - 17:15	<b>OP-03</b> Camellia sinensis, the tea plant, exerts anabolic effects on extracellular matrix components of skin	Erkin Pekmezci
17:15 - 17:20	<b>OP-04</b> Sweet's syndrome associated with brucellosis and uriner tract infection	Mehmet Melikoğlu
17:20 - 17:25	<b>OP-05</b> Evaluation of patch test results in patients with allergic contact dermatitis: a single-center retrospective study	Tayfun Batan
17:25 - 17:30	<b>OP-06</b> Extraction of essential oils of nigelle seed; application to the formulation an anti-inflammatory cream	Djedri Bani Safia
17:30 - 17:35	<b>OP-05</b> Regression of vitiligo lesions after DPCP treatment in alopecia areata	Mehmet Melikoğlu





# 4<sup>th</sup> INDERCOS

## Dermatology and Cosmetology Congress with International Participants

27 - 30 MARCH, 2019  
HILTON ISTANBUL BOSPHORUS HOTEL  
ISTANBUL, TURKEY



27 March 2019, Wednesday

Hall 2

### Clinical Dermatology

#### 08:45 - 10:00 Pain and Dermatology

*Chairs: Pelin Üstüner, Nagihan Sahillioğlu*

08:45 - 09:00	Pain related skin diseases	<i>Bachar Memet</i>
09:00 - 09:15	Cephalalgia in alopecia	<i>Bachar Memet</i>
09:15 - 09:30	Paresthesia related skin diseases	<i>Pelin Üstüner</i>
09:30 - 09:45	Neurological itch management	<i>Pelin Üstüner</i>
09:45 - 10:00	Serotonin antagonists, anti-CGRP monoclonal antibodies, cannaboid agonist, opiate antagonists, $\alpha$ - adrenergic agonist and skin	<i>Nagihan Sahillioğlu</i>

#### 10:00 - 10:30 Coffee Break

#### 10:30 - 12:00 General Dermatology -3

*Chairs: Kenan Aydoğan, Ivana Binic*

10:30 - 10:45	Natural sunlight therapy in dermatology	<i>Kenan Aydoğan</i>
10:45 - 11:00	Colchicine, dapson/sulphapyridine for skin diseases	<i>Fatma Aslı Hapa</i>
11:00 - 11:15	Guidelines for the management of vulvodynia	<i>Gudula Kirtschig</i>
11:15 - 11:30	Lichen planus of the mucosae: Symptoms, diagnosis, therapeutic procedures	<i>Gudula Kirtschig</i>
11:30 - 11:45	Hormon replacement therapy in therapy of aging skin	<i>Ivana Binic</i>
11:45 - 12:00	Dermoscopy : What's new?	<i>Mustafa Turhan Şahin</i>

#### 12:00 - 13:30 Lunch



# 4<sup>th</sup> INDERCOS

## Dermatology and Cosmetology Congress with International Participants

27 - 30 MARCH, 2019  
HILTON ISTANBUL BOSPHORUS HOTEL  
ISTANBUL, TURKEY



27 March 2019, Wednesday

Hall 2

### 13:30 - 15:00 What's New In Dermatology ?

**Chairs: Emel Bülbül Başkan, Hok Bing Thio**

13:30 - 13:45	Wnt modulation in dermatology	Emel Bülbül Başkan
13:45 - 14:00	DNA methylation in dermatology	Aslı Tatlıpırmak
14:00 - 14:15	Ion channels in dermatology	Özgür Gündüz
14:15 - 14:30	Nanotechnology in dermatology	Özgür Gündüz
14:30 - 14:45	Immunosenescence in ageing	Hok Bing Thio
14:45 - 15:00	Microencapsulation technology in dermatology	Eda Tiftikçi

### 15:00 - 15:15 Coffee Break

### 15:15 - 17:00 Allergy and Immunology

**Chairs: Valentina Broshtilova, Rafet Koca**

15:15 - 15:25	Acetylcholine related skin diseases	Erdoğan Terzi
15:25 - 15:35	Adrenaline noradrenaline related skin diseases	Erdoğan Terzi
15:35 - 15:50	Exercises-induced skin diseases	Gül Yıldırım
15:50 - 16:05	Herbal drug interactions and new horizons in dermatology	Ahmet Metin
16:05 - 16:20	Botanical dermatology: Plants and plant products injurious to the skin	Rafet Koca
16:20 - 16:35	Leukotriene receptor antagonists in the treatment of skin diseases	Valentina Broshtilova
16:35 - 16:50	Emergency IVIG management in dermatology	Hilal Gökçalp
16:50 - 17:00	Discussion	

### 17:00 - 17:30 Oral Presentation - 2

**Chairs: Özgür Gündüz, Erdoğan Terzi**

17:00 - 17:05	<b>OP-07</b> Picosure laser in the treatment of different skin disorders	Mohammed Abdul Qader Al Malmi
17:10 - 17:15	<b>OP-09</b> Assessment of quality of life, depression and anxiety levels of patients with mycosis fungoides and comparison with healthy controls	Ayşegül Sevim Keçici
17:15 - 17:20	<b>OP-10</b> Evaluation of psychosocial effects of long-term genital HPV infection	Nermin Karaosmanoğlu
17:20 - 17:25	<b>OP-11</b> combined intense pulsed light and long-pulsed 1064-nm nd: YAG laser for the treatment of nevus flammeus	Leyla Baykal Selcuk
17:25 - 17:30	Discussion	



# 4<sup>th</sup> INDERCOS

## Dermatology and Cosmetology Congress with International Participants

27 - 30 MARCH, 2019  
HILTON ISTANBUL BOSPHORUS HOTEL  
ISTANBUL, TURKEY



28 March 2019, Thursday

Hall 1

### 08:00 - 08:30 Oral Presentation-3

*Chairs: Emin Özlü, Ömer Faruk Elmas*

- 08:00 - 08:05 **OP-13** Dermatological side effects of targeted antineoplastic drugs: Prospective study *Şenay Ağırgöl*
- 08:05 - 08:10 **OP-14** How I use sport products in dermatologic surgery *Patricia Liana Cristodor*
- 08:10 - 08:15 **OP-15** Comparing the efficacy of metronidazole 1% gel versus low-dose oral isotretinoin in the treatment of moderate to severe seborrheic dermatitis *Mohamad Goldust*
- 08:15 - 08:20 **OP-16** Dermatofibrosarcoma protuberans: clinical and histopathological features of 9 cases *Asude Kara Polat*
- 08:20 - 08:25 **OP-17** Long-term efficacy and safety of infliximab for psoriasis: Twelve-year experience in a single tertiary center *Armağan Kutlay*
- 08:25 - 08:30 Discussion

### 08:30 - 10:00 Psychodermatology

*Chairs: İlnur Kivanç Altunay, Katlein Franca*

- 08:30 - 08:45 Steroid phobia: What can we do? *Hilal Kaya Erdoğan*
- 08:45 - 09:00 Somatoform disorders and treatment options in dermatology (Biofeedback, hypnosis, psychotherapy in dermatology) *Banu Ertekin Taşkın*
- 09:00 - 09:15 The impact of psychosocial stress on healthy skin *Berna Aksoy*
- 09:15 - 09:30 Dysmorphic disorders and Munchausen syndrome in dermatology *İlnur Kivanç Altunay*
- 09:30 - 09:45 Post-finasteride syndrome: What to tell our patients? *Katlein Franca*
- 09:45 - 10:00 Psychobiology for the beginners: Selected concepts for the dermatologists *Torello Lotti*

### 10:00 - 10:15 Coffee Break


### 10:15 - 11:00 Rational Use Of Medicines (Akılcı İlaç Oturumu)

*Chairs: Gülden Ersöz, Torello Lotti*

- 10:15 - 10:30 Staphylococcus aureus eradication therapies *Gülden Ersöz*
- 10:30 - 10:45 Autoimplantation therapy for skin diseases *Emin Özlü*
- 10:45 - 11:00 Sun protection in Integrative Dermatology - from cosmetic purposes to skin cancer prevention *Alexandra Vojvodic*

### 11:00 - 11:45 Satellite Symposium

*Chair: Kemal Özyurt*

-  America experiences of tazaroten, expected retinoid used for the treatment of acne and psoriasis *Leon Kırıcık*

### 11:45 - 12:00 Break



# 4<sup>th</sup> INDERCOS

## Dermatology and Cosmetology Congress with International Participants

27 - 30 MARCH, 2019  
HILTON ISTANBUL BOSPHORUS HOTEL  
ISTANBUL, TURKEY



28 March 2019, Thursday

Hall 1

### 12:00 - 13:30 Pruritus in All Aspects: Interactive and Integrated Session

<b>Chairs: Marcus Maurer, Sinan Canan</b>		
12:00 - 12:15	Itch in chronic urticaria and recurrent angioedema – prevalence, relevance and how to treat	Marcus Maurer
12:15 - 12:30	Chronic pruritus – pathomechanisms, mediators, cells and neurophysiology	Sinan Canan
12:30 - 12:45	Chronic pruritus – definition, classification, assessment, impact	Martin Metz
12:45 - 13:00	Itch in psoriasis, atopic dermatitis, and Beyond – what to know and how to treat?	Tomasz Hawro
13:00 - 13:15	Chronic pruritus due to extracutaneous causes - gastrointestinal, endocrine, nephrology, hematology/oncology and treatment	Ragıp Ertaş
13:15 - 13:30	Current and future treatments for pruritus – targets and compounds	Zekai Halıcı

### 13:30 - 14:15 Lunch

### 14:15 - 15:45 Essential Knowledge About Psoriasis Management Besides Prescribing Some Creams or Drugs

<b>Chairs: Mustafa Atasoy, Kemal Özyurt</b>		
14:15 - 14:30	Psoriasis registries	Kemal Özyurt
14:30 - 14:45	Comorbidities and quality of life of psoriatic disease	Leon Kırıcık
14:45 - 15:00	Essential laboratory procedures and consultations before and during treatment of psoriasis	Ömer Faruk Elmas
15:00 - 15:15	Latent tuberculosis, diagnosis and management	Tülin Çağatay
15:15 - 15:30	Long term safety profiles of systemic therapies in psoriasis	Zafer Türkoğlu
15:30 - 15:45	Economical and social burden of psoriasis	Tomasz Hawro

### 15:45 - 16:30 Satellite Symposium

<b>FARMANOVA</b>		
	Comprehensive and Innovative Treatment Approach in Psoriasis	Kemal Özyurt
	New Target in Psoriasis: IL-17A Inhibition and Secukinumab	Bengü Gerçeker Türk
	Real Life Experience with Secukinumab	Kemal Özyurt

### 16:30 - 16:45 Coffee Break

### 16:45 - 18:30 Dermato - Surgery

<b>Chairs: Amor Khachemoune, Pelin Koçyiğit</b>		
16:45 - 17:00	Injection phobia: What can we do in aesthetic dermatology?	Ömer Faruk Elmas
17:00 - 17:15	Medical gloves for dermatologists	Ömer Faruk Elmas
17:15 - 17:30	Topical anesthetics, nerve blocks and anesthesia of oral mucosa in aesthetic dermatology	Tuğrul Dereli
17:30 - 17:45	Surgical myths in dermatology	Amor Khachemoune
17:45 - 18:00	Nail biopsy: Indications and methods	Pelin Koçyiğit
18:00 - 18:15	Surgical approaches of nail unit tumours	Fatih Göktay
18:15 - 18:30	Punch and shave excisions in dermatology	Necmettin Akdeniz



# 4<sup>th</sup> INDERCOs

Dermatology and Cosmetology Congress  
with International Participants

27 - 30 MARCH, 2019  
HILTON ISTANBUL BOSPHORUS HOTEL  
ISTANBUL, TURKEY



28 March 2019, Thursday

Hall 1

18:30 - 19:00 Oral Presentation - 5

*Chairs: Ömer Faruk Elmas, Necmettin Akdeniz*

- |               |                                                                                                                                                                                                                        |                         |
|---------------|------------------------------------------------------------------------------------------------------------------------------------------------------------------------------------------------------------------------|-------------------------|
| 18:30 - 18:35 | <b>OP-24</b> A brief report about treatment compliance in patients with psoriasis according to three-year data of PSORTAKSIS                                                                                           | <i>Kemal Özyurt</i>     |
| 18:35 - 18:40 | <b>OP-25</b> Investigation of latent tuberculosis infection before TNF inhibitors treatment in patients with psoriasis: Significance of clinical properties, QuantiFERON-TB gold in-tube test and tuberculin skin test | <i>Kemal Özyurt</i>     |
| 18:40 - 18:45 | <b>OP-26</b> Onychoscopy in the diagnosis of the distal subungual onychomycosis and traumatic onycholysis                                                                                                              | <i>Ömer Faruk Elmas</i> |
| 18:45 - 18:50 | <b>OP-27</b> The role of borrelia burgdorferi in the etiology of localized scleroderma (morphea)                                                                                                                       | <i>Baran Cayhan</i>     |
| 18:50 - 18:55 | <b>OP-28</b> Vitiligo camouflage: Emerging trend in dermatology                                                                                                                                                        | <i>Aditya Favade</i>    |
| 18:55 - 19:00 | Discussion                                                                                                                                                                                                             |                         |





# 4<sup>th</sup> INDERCOS

## Dermatology and Cosmetology Congress with International Participants

27 - 30 MARCH, 2019  
HILTON ISTANBUL BOSPHORUS HOTEL  
ISTANBUL, TURKEY



28 March 2019, Thursday

Hall 2

### 08:00 - 08:30 Oral Presentation - 4

**Chairs:** *Alev Babuş, Hilal Gökalp*

- 08:00 - 08:05 **OP-19** The efficacy of adding low-level light therapy to minoxidil 5% solution in the treatment of androgenetic alopecia *Mohamad Goldust*
- 08:05 - 08:10 **OP-20** Treatment of angiokeratoma of fordyce with long-pulse neodymium-doped yttrium aluminium garnet laser *Neslihan Fişek Izci*
- 08:10 - 08:15 **OP-21** Clinical and demographic characteristics of pediatric morphea: a study of 37 cases *Sertaç Şener*
- 08:15 - 08:20 **OP-22** Leukocytoclastic vasculitis: A retrospective analysis of 57 patients *Nermin Karaosmanoğlu*
- 08:20 - 08:25 **OP-23** Accuracy rates of initial diagnosis of eleven patients with milker's nodule after religious sacrifice feast *Ecem Zeliha Ergün*
- 08:25 - 08:30 Discussion

### 08:30 - 10:00 Aesthetic Dermatology -1

**Chairs:** *Ivana Binic, Hilal Gökalp*

- 08:30 - 08:45 Morphological and ethnic differences between men and women for aesthetic procedures *Alev Bobuş*
- 08:45 - 09:00 Guidelines of chemical peel *Ivana Binic*
- 09:00 - 09:15 Aesthetic dermatology in connective tissue diseases *Hilal Gökalp*
- 09:15 - 09:30 Hair loss in elderly women *Tuğba Özkök Akbulut*
- 09:30 - 09:45 Estradiol/progesteron related skin diseases *Filiz Topaloğlu Demir*
- 09:45 - 10:00 Discussion

### 10:00 - 10:30 Coffee Break

### 10:30 - 12:00 General Dermatology -4

**Chairs:** *Emel Fetil, Valentina Broshtilova*

- 10:30 - 10:45 Silver, glizigen and glutathione treatment in dermatology *Yeşim Akpınar Kara*
- 10:45 - 11:00 Salicylic acid in dermatology *Emel Fetil*
- 11:00 - 11:15 Polyamine metabolism changes in dermatology *Valentina Broshtilova*
- 11:15 - 11:30 Possibilities and prospects for acupuncture in dermatology *Valentina Broshtilova*
- 11:30 - 12:00 Discussion

### 12:00 - 13:30 Integrative Dermatology

**Chairs:** *Katlein Franca, Torello Lotti*

- 12:00 - 12:15 Ayurveda, cupping, moxibustion, hirudotherapy for skin diseases *Habibullah Aktaş*
- 12:15 - 12:30 Probiotics and the skin *Katlein Franca*
- 12:30 - 12:45 Herbal oils in dermatology *Ayşin Köktürk*
- 12:45 - 13:00 Natural weapons and strategies for melasma *Milanka Ljubenicovic*
- 13:00 - 13:15 Antiviral herbs (echinacea etc) botanical protection against viruses *Ahmet Metin*
- 13:15 - 13:30 Is avoiding sun as dangerous as smoking? *Sedat Akdeniz*



# 4<sup>th</sup> INDERCOS

## Dermatology and Cosmetology Congress with International Participants

27 - 30 MARCH, 2019  
HILTON ISTANBUL BOSPHORUS HOTEL  
ISTANBUL, TURKEY



28 March 2019, Thursday

Hall 2

13:30 - 14:15 Lunch

14:15 - 16:00 Botulinum Toxins in Dermatology

*Chairs: Zekai Kutlubay, Andreas Katsambas*

14:15 - 14:30	Botulinum toxin treatment concepts	Zekai Kutlubay
14:30 - 14:45	Body contouring with botulinum toxins	Filiz Kuşak
14:45 - 15:00	Botulinum toxins for facial palsy/asymmetric smile	Filiz Kuşak
15:00 - 15:15	Botulinum toxins: As a pain killer- anti-aging properties-topical botulinum toxins	Hüray Hügül
15:15 - 15:30	Combination therapy of botulinum toxin with other nonsurgical procedures	Hüray Hügül
15:30 - 15:45	Botulinum toxin-a: Mid and lower face, what's new?	Andreas Katsambas
15:45 - 16:00	Discussion	

16:00 - 16:30 Coffee Break

16:30 - 18:30 Aesthetic Dermatology -2

*Chairs: Pertevniyal Bodamyali, Assel Markabayeva*

16:30 - 16:45	Combination therapy of PRP with other nonsurgical procedures in dermatology	Zahide Eriş
16:45 - 17:00	Combination therapies in aesthetic dermatology how long should we wait?	Recep Dursun
17:00 - 17:15	Same day combination therapies in aesthetic dermatology	Recep Dursun
17:15 - 17:30	Herbal stem cells for anti-aging	Özgür Timurkaynak
17:30 - 17:45	Stromal cells for the face rejuvenation	Assel Markabayeva
17:45 - 18:00	Secrets of fillers	Pertevniyal Bodamyali
18:00 - 18:15	How to combine injectables with EBDS	Ines Verner
18:15 - 18:30	Skin care and ageing - the 3R concept	Victor Clatici

18:30 - 18:45 Oral Presentation - 6

*Chairs: Zahide Eriş, Pertevniyal Bodamyali*

18:30 - 18:35	<b>OP-29</b> A case of recalcitrant linear IgA dermatosis: Successfully treated with rituximab	Zeynep Gizem Kaya İslamoğlu
18:35 - 18:40	<b>OP-30</b> Efficacy and safety of secukinumab in the treatment of moderate-severe psoriasis in our clinic	Zeynep Gizem Kaya İslamoğlu
18:40 - 18:45	<b>OP-31</b> Secukinumab therapy for palmoplantar pustulosis	Meltem Türkmen



# 4<sup>th</sup> INDERCOS

## Dermatology and Cosmetology Congress with International Participants

27 - 30 MARCH, 2019  
HILTON ISTANBUL BOSPHORUS HOTEL  
ISTANBUL, TURKEY



29 March 2019, Friday

Hall 1

### 08:00 - 08:30 Oral Presentation - 7

*Chairs: Ömer Kutlu, Tuğba Kevser Üstünbaş*

- 08:00 - 08:05 **OP-32** Is really association lichen planus and hepatitis-C? *Fatma Tunçez Akyürek*
- 08:05 - 08:10 **OP-33** Image recording with handheld dermatoscope without adapter and improving the quality of recorded image by mobile photo editor application *Erhan Ayhan*
- 08:10 - 08:15 **OP-35** A case of acquired scrotal lymphangioma circumscriptum *Gökhan Çeker*
- 08:15 - 08:20 **OP-36** Surprising evolution in the treatment of a hypertrophic scar *Iustin Hancu*
- 08:20 - 08:25 **OP-38** A case of inverse klippel-trenaunay syndrome with no mutation in PIK3CA gene *Sezin Fıçıcıoğlu*
- 08:25 - 08:30 Discussion

### 08:30 - 10:15 Aesthetic Dermatology - 3

*Chairs: Assel Markabayeva, Kansu Büyükaşar*

- 08:30 - 08:45 Skin complications of injectable agents *Tuğba Kevser Üstünbaş*
- 08:45 - 09:00 Telomerase activators for antiaging *Kansu Büyükaşar*
- 09:00 - 09:15 New tattoo approaches in dermatology *Zehra Aşiran Serdar*
- 09:15 - 09:30 Ultratherapy for skin ageing *Gaye Sarıkan*
- 09:30 - 09:45 Hyperbaric oxygen therapy in dermatology *Burhan Engin*
- 09:45 - 10:00 Hair transplantation in dermatology *Assel Markabayeva*
- 10:00 - 10:15 Assessment of intralesional injection of botulinum toxin for hypertrophic scars *Hasan Mete Aksoy*

### 10:15 - 10:30 Coffee Break

### 10:30 - 12:00 Sebaceous Gland Diseases And Hormones In Dermatology

*Chairs: Bodo Melnik, Ivana Binic*

- 10:30 - 10:45 The role of metabolomics in the pathogenesis of hidradenitis suppurativa *Bodo Melnik*
- 10:45 - 11:00 Acne nutrigenomics *Bodo Melnik*
- 11:00 - 11:15 Oily skin: What can we do? *Aslı Kaptanoğlu*
- 11:15 - 11:30 Propionibacterium in dermatology *Emin Özlü*
- 11:30 - 11:45 Oral contraceptives in dermatology *Burçe Can Kuru*
- 11:45 - 12:00 Testosterone and dihydrotestosterone in the pathogenesis of skin diseases *Züleyha Özgen*

### 12:00 - 13:30 Lunch



# 4<sup>th</sup> INDERCOS

## Dermatology and Cosmetology Congress with International Participants

27 - 30 MARCH, 2019  
HILTON ISTANBUL BOSPHORUS HOTEL  
ISTANBUL, TURKEY



29 March 2019, Friday

Hall 1

**13:30 - 15:15 Escad / Indercos - 1**

*Chairs: Andreas Katsambas, Ines Verner*

13:30 - 13:45	Pharmacological profile of botulinum toxins	<i>Kansu Büyükaşar</i>
13:45 - 14:00	8 Points lift with fillers	<i>Andreas Katsambas</i>
14:00 - 14:15	Skin tightening & rejuvenation - what's new?	<i>Ines Verner</i>
14:15 - 14:30	Long pulse NdYag lasers in aesthetic dermatology	<i>Tamer İrfan Kaya</i>
14:30 - 14:45	Holistic approach to antiaging	<i>Aylin Kuyumcuoğlu</i>
14:45 - 15:00	"Small Molecule Wnt Pathway Modulator (SM04554) - Potential Topical Treatment for Androgenetic Alopecia"	<i>İsmail Şimşek</i>
15:00 - 15:15	Discussion	

**15:15 - 15:45 Coffee Break**

**15:45 - 18:00 Escad / Indercos - 2**

*Chairs: Andreas Katsambas, Ines Verner*

15:45 - 16:00	Nasal filler augmentation: Technical consideration and complications	<i>Tilemachos Anthopoulos</i>
16:00 - 16:15	Combination therapies of injectable fillers for facial soft tissue enhancement with other nonsurgical procedures	<i>Pertevniyal Bodamyalı</i>
16:15 - 16:30	Adipose tissue stem cells and anti-ageing	<i>John Katsantonis</i>
16:30 - 16:45	Pulsed dye laser in aesthetic dermatology	<i>Yasemin Oram</i>
16:45 - 17:00	Full ablative resurfacing: Pros and cons	<i>Konstantin Neamonitos</i>
17:00 - 17:15	Q switched lasers in dermatology	<i>Belma Türsen</i>
17:15 - 17:30	Hair growth stimulation by EBDS	<i>Ines Verner</i>
17:30 - 17:45	FDA approved cosmetical procedures (botulinum toxins, fillers, laser etc)	<i>Ömür Tekeli</i>
17:45 - 18:00	Butterfly Effect and Ageing - where is the link?	<i>Victor Clatici</i>





# 4<sup>th</sup> INDERCOS

## Dermatology and Cosmetology Congress with International Participants

27 - 30 MARCH, 2019  
HILTON ISTANBUL BOSPHORUS HOTEL  
ISTANBUL, TURKEY



29 March 2019, Friday

Hall 2

### 08:00 - 08:30 Oral Presentation - 8

*Chairs: Göknur Kalkan, Zennure Takcı*

- 08:00 - 08:05 **OP-39** "Clinical phenotype, disease severity and trigger factors of patients with rosacea in southeastern of Turkey" *Semahat Alp Erdal*
- 08:05 - 08:10 **OP-40** Linear atrophoderma of moulin: A case report *Betül Macit*
- 08:10 - 08:15 **OP-42** Comparison of changes in serum IgE levels before and after omalizumab treatment of 127 patients with chronic spontaneous urticaria *Mehmet Demirel*
- 08:15 - 08:20 **OP-43** Dermoscopy for the diagnosis of bowenoid papulosis *Yıldız Gürsel Ürün*
- 08:20 - 08:25 **OP-44** Intralesional tranexamic acid in treatment of telangiectasia: Reversible effect and resistance to therapy *Erhan Ayhan*
- 08:25 - 08:30 Discussion

### 08:30 - 10:00 Diet And Aesthetic Dermatology - 4

*Chairs: Yasemin Oram, Ekrem Civaş*

- 08:30 - 08:45 Acne, psoriasis, autoimmune bullous diseases, skin cancers, systemic medication and diet, gluten in dermatology *İlkin Zındancı*
- 08:45 - 09:00 Biotin, folic acid, and coenzyme Q for skin health *Göknur Kalkan*
- 09:00 - 09:15 Vitamin A/B/C/D in dermatology *Zennure Takcı*
- 09:15 - 09:30 Rejuvenation of skin with lasers *Yasemin Oram*
- 09:30 - 09:45 Laser treatment for vascular lesions *Ekrem Civaş*
- 09:45 - 10:00 Complementary medicine for skin cancers *Ömer Kutlu*

### 10:00 - 10:30 Coffee Break

### 10:30 - 12:00 Investigative Dermatology

*Chairs: Hok Bing Thio, Özgür Timurkaynak*

- 10:30 - 10:45 Basic sciences for the clinician; (Epi)genetics *Hok Bing Thio*
- 10:45 - 11:00 Microbiota, immune system and skin *Hok Bing Thio*
- 11:00 - 11:15 Immunotherapy cancer and skin *Hok Bing Thio*
- 11:15 - 11:30 Stem cell modulation in dermatology *Özgür Timurkaynak*
- 11:30 - 11:45 Circadian rhythm and skin diseases *Berna Aksoy*
- 11:45 - 12:00 Autophagy in dermatology *Devrim Gözüaçık*

### 12:00 - 13:30 Lunch

### 13:30 - 16:00 Meet the Expert *(Presentation of this session will be in Turkish)*

- 13:30 - 14:00 LeShape: Hyperthermic laser lypolysis **SICAK LAZER LİPOLİZ** *Ulaş Güvenç*
- 14:10 - 14:40 Botulinum toxin pen juvapen **mezoklinik** *Ali Şahan*
- 14:50 - 15:20 Candela elos plus optic energy and radiofrecuenc association: What give us? **SYNERON CANDELA** *Ulaş Güvenç*
- 15:30 - 16:00 Agassi non-surgical cheek slimming and tightening method **ESTETİK TREND** *Ali Şahan*
- 15:30 - 16:00 Dynamic face lifting with spring thread **EKSONFARMA SAĞLIK ÜRÜNLERİ** *Naci Çelik*





# 4<sup>th</sup> INDERCOS

Dermatology and Cosmetology Congress  
with International Participants

27 - 30 MARCH, 2019  
HILTON ISTANBUL BOSPHORUS HOTEL  
ISTANBUL, TURKEY



30 March 2019, Saturday

Hall 1

08:00 - 08:30 Oral Presentation - 9

*Chairs: Deniz Demirseren, Aylin Türel Ermertcan*

- 08:00 - 08:05 **OP-45** Foveal thinning in patients with recurrent aphthous ulcer *Betül Şerefliçan*  
08:05 - 08:10 **OP-46** Dermoscopic profile of pigmented purpuric dermatosis: New observations *Ömer Faruk Elmas*  
08:10 - 08:15 **OP-47** Giant cell tumor of the tendon sheath: A clinicopathologic study of 31 cases *Ömer Faruk Elmas*  
08:15 - 08:20 **OP-48** Stop sweating and start living *K Prem Anand*  
08:20 - 08:30 Discussion

08:30 - 10:00 STD, Sexual Disorders and Forensic Medicine in Dermatology

*Chairs: Mihael Skerlev, Soner Uzun*

- 08:30 - 08:45 Sexual function disorders in dermatology *Aylin Türel Ermertcan*  
08:45 - 09:00 Skin manifestations in forensic medicine and sexual abuse *Hakan Kar*  
09:00 - 09:15 STDs related to orosexual contact *Soner Uzun*  
09:15 - 09:30 The importance of prophylaxis and partner treatments for STDs *Mihael Skerlev*  
09:30 - 09:45 Surgical and non-surgical managements of women's sexual dysfunctions *Ayten Olgun*  
09:45 - 10:00 Discussion

10:00 - 10:15 Coffee Break

10:15 - 12:30 What's New? -2

*Chairs: Mustafa Tunca, Amor Khachemoune*

- 10:15 - 10:30 Vibration and nitrous oxide anesthesia in cosmetic procedures, sympathectomy in dermatology *Mustafa Tunca*  
10:30 - 10:45 Topical anti-cholinergics and anti-androgens in dermatology *Betül Şerefliçan*  
10:45 - 11:00 Amputee problems in dermatology *Ercan Arca*  
11:00 - 11:15 Egg, nuts and milk in dermatology *Deniz Demirseren*  
11:15 - 11:30 PDL1, BTK/ITK and proteosome pathways for skin diseases *Ezgi Erdal*  
11:30 - 11:45 Honey and propolis in dermatology *Amor Khachemoune*  
11:45 - 12:00 Camellia sinensis, flavonoids and tea tree oil in dermatology *Ufuk Kavuzlu*  
12:00 - 12:15 Secondary skin manifestations after internal surgery (bariatric surgery, mastectomy) *Cahit Yavuz*

12:15 - 12:30 Closing Speech and Lecture

*Chairs : Ümit Türsen, Aleksandra Vojvodic, Belma Türsen, Torello Lotti*

An unexpected multimedia lecture between myth, science and beauty *Torello Lotti*



# 4<sup>th</sup> INDERCOS

## Dermatology and Cosmetology Congress with International Participants

27 - 30 MARCH, 2019  
HILTON ISTANBUL BOSPHORUS HOTEL  
ISTANBUL, TURKEY



30 March 2019, Saturday

Hall 2

### 08:05 - 08:30 Oral Presentation - 10

*Chairs: Gaye Sarıkan, Sadiye Kuş*

08:05 - 08:10	<b>OP-08</b> Vitamin D levels and its impact on the quality of life in patients with chronic spontaneous urticaria	<i>Ragıp Ertaş</i>
08:10 - 08:15	<b>OP-50</b> Oral ofacitinib in the treatment of alopecia areata: A single-centre experience of 4 cases	<i>Begüm Ünlü</i>
08:15 - 08:20	<b>OP-51</b> Use of pilates mats in dermal filler injection training	<i>Begüm Ünlü</i>
08:20 - 08:25	<b>OP-53</b> The effectiveness of two original liquid crystal formulation with retinol in randomized parallel control trial	<i>Malwina Zasada</i>
08:25 - 08:30	Discussion	

### 08:30 - 10:00 Aesthetic Dermatology - 5

*Chairs: Sadiye Kuş, Gaye Sarıkan*

08:30 - 08:45	The life cycles and biological end pathways of dermal fillers	<i>Dilek Başaran</i>
08:45 - 09:00	Treatment of cellulit	<i>Eneida Kote</i>
09:00 - 09:15	Is there a right way for treating temporal region with fillers?	<i>Sadiye Kuş</i>
09:15 - 09:30	The perioral beautification	<i>Gaye Sarıkan</i>
09:30 - 09:45	IPL in treatment of facial erythema	<i>Zeynep Demirçay</i>
09:45 - 10:00	Turkey's contribution to the dermatology literature	<i>Emel Çalkoğlu</i>

### 10:00 - 10:15 Coffee Break

### 10:15 - 12:15 Dermatological Surgery -2

*Chairs: Konstantin Neamonitos, Ines Verner*

10:15 - 10:30	Blepharoplasty techniques & combination treatments	<i>Konstantin Neamonitos</i>
10:30 - 10:45	Persistent adverse side effects of ha fillers	<i>John Katsantonis</i>
10:45 - 11:00	Aesthetic ear reconstruction for dermatologist	<i>Hasan Mete Aksoy</i>
11:00 - 11:15	Cosmetical camouflage in dermatology	<i>Serap Öztürkcan</i>
11:15 - 11:30	Truths and myths about injectable threads	<i>Tilemachos Anthopoulos</i>
11:30 - 11:45	Ablative fractional Rf -better than lasers? Current & future indications	<i>Ines Verner</i>
11:45 - 12:00	Cosmetical procedures for children	<i>Zennure Takcı</i>
12:00 - 12:15	Lipofilling in periorbital area	<i>Assel Markabayeva</i>

LECTURE  
SUMMARIES





# 4<sup>th</sup> INDERCOS

## Dermatology and Cosmetology Congress with International Participants

27 - 30 MARCH, 2019  
HILTON ISTANBUL BOSPHORUS HOTEL  
ISTANBUL, TURKEY



### **PSORIASIS AND HIDRADENITIS SUPPURATIVA; WHAT DO THEY HAVE IN COMMON?**

**Omid Zargari**

Psoriasis and Hidradenitis Suppurativa (HS) seem like very different diseases at first glance. Our understanding of pathogenesis of psoriasis has changed dramatically during the past decades. I believe that the same thing is happening for HS; years ago it was considered merely an infectious disease. Then, the importance of follicular occlusion in the pathogenesis of HS was discovered. Now, many speculate that HS may be a disease of aberrant immunity. Here, I will compare these two diseases side by side and demonstrate that their similarities are more apparent than what we think.



# 4<sup>th</sup> Indercos

## Dermatology and Cosmetology Congress with International Participants

27 - 30 MARCH, 2019  
HILTON ISTANBUL BOSPHORUS HOTEL  
ISTANBUL, TURKEY



### **PSORIATIC PLAQUES AND ATHEROMA PLAQUES - IS IT POSSIBLE TO KILL TWO BIRDS WITH ONE STONE?**

**Omid Zargari**

Our understanding of the pathophysiology of psoriasis and atherosclerosis has evolved during the past decades. It is now known that there are some common pathologic pathways involved in the development of both psoriatic and atheroma plaques. Indeed, the primary inflammatory cytokines implicated in the pathogenesis of psoriasis (TNF-alpha, IL-17, and IL-23) also contribute to atheroma formation.

Although the link between psoriasis and cardiovascular risk factors is considered to be a well-established phenomenon by now, there are still many unanswered questions regarding the co-occurrence of these conditions.

In this presentation, I present current literature on this topic and touch on the implications for clinical practice.





# 4<sup>th</sup> INDERCOS

## Dermatology and Cosmetology Congress with International Participants

27 - 30 MARCH, 2019  
HILTON ISTANBUL BOSPHORUS HOTEL  
ISTANBUL, TURKEY



### INTEGRATIVE APPROACH TO PSORIASIS VULGARIS

Milanka Ljubenovic

Psoriasis is a chronic, systemic, inflammatory disease whose skin changes are its most visible sign. It covers approximately 1 - 3% of the world population, and the National Psoriasis Foundation (NPF) in the United States estimated the number of patients in the whole world at about 125 millions.

Psoriasis primarily affects the skin, burdening patients with inflamed, pruritic, sometimes painful lesions covered with whitish scales, that last for years.

Because of the disease prevalence in general population, the diversity of the clinical picture (from a minimal and localized lesions without subjective symptoms to life-threatening conditions), disease duration (practically a lifetime), psoriasis is a disease in the focus of modern medicine, and the therapeutic options for the treatment of psoriasis are currently very numerous and diverse.

Conventional treatment of psoriasis is carried by the so-called principle of "steps", where treatment options are applied according to the severity of illness, assessed by a physician.

Apart from the official therapy for psoriasis, as it is defined and understood in modern developed societies, today in modern world exists in parallel a great number of traditional, complementary and alternative psoriasis treatments, which are based on the beliefs, experiences and theories inherent to different cultures.

The list of procedures that pertain to the area of Complementary and Alternative Medicine (CAM) is very wide and constantly changing. CAM therapeutic procedures can be classified into one of the following groups:

**Alternative medical systems;**

**Biologically based therapy** that involves the use of substances from nature;

**The mind - body interventions**, aiming to increase the ability of human mind to influence body functions, and the symptoms of illness;

**Manipulative and body - based methods** which are based on the manipulation and / or movement of one or more parts of the body;

**Energy therapies**, that use the action of the energy field .

In this paper we present the most popular and commonly used therapeutic procedures in the treatment of psoriasis belonging to complementary and alternative medicine.



# 4<sup>th</sup> INDERCOS

## Dermatology and Cosmetology Congress with International Participants

27 - 30 MARCH, 2019  
HILTON ISTANBUL BOSPHORUS HOTEL  
ISTANBUL, TURKEY



### PSORIASIS AND COMORBIDITIES: LINKS AND RISKS

Erkan Alpsoy

Psoriasis is a chronic, immune-mediated, inflammatory disease affecting 2% of the world's population. It usually starts between the ages of 20-30. Genetic and environmental factors are considered important in the development of the disease (1,2). Several *co-morbidities* may accompany psoriasis. Thus, patients need long-term and careful follow-up at appropriate intervals, and they should be treated with the most appropriate options. The main cause of co-morbidities associated with psoriasis is long-term systemic inflammation and common inflammatory pathways, genetic factors, drugs used for psoriasis and common risk factors (cigarette, alcohol, etc.).

#### I-Cardiovascular diseases and risk factors

Cardiovascular (CV) risk factors have been reported to be increased in patients with psoriasis. Hypertension, Type 2 diabetes, dyslipidemia, obesity, and metabolic syndrome (MS), a consequence of previous 4 situations, are known as the main CV risk factors. The life expectancy in severe psoriasis cases has been reported approximately 5 years shorter than healthy controls, and the CV diseases (CVD) are the most important reason for this situation (3). In the same study, stroke, atherosclerosis, myocardial infarction (MI), coronary artery disease and endothelial dysfunction were found to be increased in patients with psoriasis even when the risk factors for CVD were corrected.

As with other chronic inflammatory diseases, inflammatory cells and cytokines mediating inflammation can lead to the development of both psoriasis and atherosclerotic plaques. Helper T cell type 1 and 17 pathways are common pathways in the development of psoriasis and atherosclerosis. TNF- $\alpha$  is the common cytokine involved in the development of these 2 conditions. In addition, CRP, VEGF and homocysteine levels which were reported to be associated with CVD increase in psoriasis (1,2).

Armstrong et al., in a systematic review and meta-analysis for CVD risk, evaluated a total of 201 239 mild and 17 415 severe psoriasis patients. They reported increased MI (RR, 1.29; RR, 1.70, respectively) and stroke risk (RR, 1.12; RR, 1.56, respectively) in mild and severe psoriasis. In addition, an increased CV mortality rate (RR, 1.39) was found in severe psoriasis (4).

In our study, the relationship between psoriasis and subclinical atherosclerosis was investigated by using pulse wave velocity (NDD) and carotid intima media thickness (CIMT) measurements. In addition to NDH and CIMT values, Total/HDL cholesterol and LDL/HDL cholesterol ratios were higher in the psoriasis group. A positive correlation was also observed between the PASI score and the NDH. In conclusion, the risk of developing atherosclerosis was found to be higher in patients with psoriasis without classical atherosclerotic risk factors. In addition to damage to the arterial wall caused by systemic inflammation, disorders of lipid metabolism may also contribute to the development of atherosclerosis (5).

CVD associated with psoriasis is important because of its high morbidity and increased mortality rate. Dermatologists should be careful and educate their patients on this subject. In the case of suspected CVD, the patient should be referred to the specialist. Healthy life (diet, exercise, smoking cessation, etc.) may be important to reduce the risk of CVD development. Studies have shown that the use of methotrexate and biological agents significantly reduces CVD risk (6).

#### II-Obesity

Obesity can be defined as a long-term and low-grade inflammatory condition. The mediators of inflammatory type macrophages in adipose tissue, adipocytokines (TNF- $\alpha$ , IL-6, and leptin) are the main source of inflammation. Current data indicate that obesity an independent risk factor for psoriasis, and psoriasis increases obesity and obesity increases psoriasis. A meta-analysis study found that the likelihood of obesity was 1.6-fold higher in psoriasis patients compared to controls (OR: 1.46 in mild psoriasis



# 4<sup>th</sup> INDERCOS

## Dermatology and Cosmetology Congress with International Participants

27 - 30 MARCH, 2019  
HILTON ISTANBUL BOSPHORUS HOTEL  
ISTANBUL, TURKEY



patients; OR: 2.23 in severe patients) (7).

The above-mentioned general measures for CVS are valid here. PASI scores were decreased in patients who have an appropriate diet and weight loss (6).

### III-Diabetes Mellitus

Type 2 DM is a metabolic disease characterized by increased insulin resistance and hyperglycemia. Psoriasis may be an independent risk factor for Type 2 DM, especially in severe forms (2). Al-Mutari et al. in 1835 patients, reported the frequency of type 2 DM to be 37.4% in mild psoriasis, 41% in severe psoriasis and 16% in controls (8).

TNF is one of the major cytokines involved in insulin resistance. Patients with type 2 DM with psoriasis require high doses of insulin due to insulin resistance. In patients receiving anti-TNF- $\alpha$  therapy, insulin resistance is improved and naturally, the need for insulin is reduced. Dermatologists should be aware of this issue and warn their patients against possible hypoglycemia (6).

### IV- Hypertension

Psoriasis may be an independent risk factor for hypertension. Both diseases have common risk factors such as smoking and obesity. In the meta-analysis, Armstrong et al. found that the frequency of hypertension was more frequent in psoriasis patients than in the normal population (9). Cohen et al. in 12 502 patients with psoriasis, reported this frequency 38.8% and 29.1%, respectively (10).

Patients with psoriasis should be counseled for healthy lifestyle habits (appropriate diet, exercise, and smoking cessation, etc.) and regular follow-up of blood pressure. Cyclosporine increases blood pressure in a dose-dependent manner. More frequent psoriasis attacks have been reported in patients using beta-blockers (6).

### V-Dyslipidemia

It is a well-known risk factor for coronary artery disease, stroke, MI and CV mortality. Dyslipidemia is typically defined by an increase in LDL, VLDL and TG levels, and a decrease in HDL levels. Th1-type cytokines (IL-1, 6 and TNF- $\alpha$ ), autoantibodies recognizing oxidized LDL, and acitretin and cyclosporin are suspected in the pathogenesis. In a meta-analysis, Ma et al. reported that dyslipidemia was associated with psoriasis and show a parallel relationship between the severity of the disease and the severity of dyslipidemia (11). Treatment of psoriasis with anti-TNF- $\alpha$  reduces inflammation markers (CRP) and lipid peroxidation products while increasing serum antioxidant capacity. Retinoids increase TG, Total, LDL and VLDL cholesterol levels. Cyclosporine may cause hypertriglyceridemia (2).

### VI-Metabolic Syndrome

Metabolic syndrome is used to identify a group of risk factors for CVD. These risk factors include diabetes mellitus (impaired glucose tolerance), hypertension, obesity, and dyslipidemia. MS increases the risk of coronary artery disease, increased risk of stroke, fatty liver, and cancer (2). In a meta-analysis study, the prevalence of MS was found to be higher in psoriasis patients than in the general population (OR: 2.26) (3). In our country, Günaydin et al. (7) reported that the prevalence of MS was significantly higher in psoriasis patients compared to controls (62% and 24%, respectively,  $p < 0.001$ ). In addition, PASI scores were higher in patients with MS than patients without MS (13.6 and 11.2,  $p = 0.04$ , respectively). When there is a suspicion, the MS parameters should be investigated and the patient should be referred to the specialist.

### VII-Nonalcoholic fatty liver disease (NAFLD)

NAFLD is defined as a high amount of TG accumulation in liver cells in patients without a history of excessive alcohol consumption. Fatty liver disease is considered as the expression of MS in the liver and is associated with type 2 DM and dyslipidemia. Prolonged inflammation, inflammatory type adipokines, and skin-derived cytokines increase insulin resistance and cause lipid accumulation in the liver (2). Gisondi et al. found fatty liver disease in 47% of patients. The persistence of this significance after controlling for BMI indicates that NAFLD is linked to psoriasis independently of obesity (14).



# 4<sup>th</sup> INDERCOS

## Dermatology and Cosmetology Congress with International Participants

27 - 30 MARCH, 2019  
HILTON ISTANBUL BOSPHORUS HOTEL  
ISTANBUL, TURKEY



Patients with psoriasis associated with MS, obesity, DM, dyslipidemia or HT should be suspected of a possible NAFLD and should be referred to the specialist. Methotrexate is a hepatotoxic drug and has been linked to the development of NAFLD. Oral folic acid supplementation decreases serum transaminase levels in patients taking this drug.

### **VIII- Cancer**

As with other chronic inflammatory diseases, psoriasis is thought to increase the risk of lymphoma. Other factors that support the hypothesis of increased cancer development can be defined as follow. Methotrexate, cyclosporine, and PUVA are frequently used in psoriasis patients and may play a role in cancer development. Additionally, smoking and alcohol use, which are important risk factors for cancer, is seen more frequently in psoriasis patients than in the general population (2).

Especially in severe forms of psoriasis, the risk of cancer, especially lymphoma, is increased. Upper aerodigestive tract, respiratory tract, liver, pancreas, and urinary tract cancers are also increased. It is well-known that PUVA treatment (more than 350 sessions) increases the risk of squamous cell carcinoma.

There is a moderate increase in the risk of basal cell carcinoma development. The risk of melanoma increases after long years from more than 250 sessions of PUVA treatment (2). Cyclosporine use also increases the incidence of SCC development (2). Cyclosporin should not be used in patients with a history of SCC, with phototherapy and before or after PUVA treatment.

### **IX- Psychosocial morbidity**

Psoriasis has long been reported to be in association with an increased risk of depression, anxiety, and suicidal ideation. Gupta et al., in a comparative study, found that depression was higher in patients with severe psoriasis than in other groups (acne, atopic dermatitis, alopecia areata). The highest rate of suicidal ideation was observed in patients with psoriasis (7.2% in psoriasis, 4% in group) (15).

The skin and adnexa, as significant features of our external appearance, contribute to our social standing. Diseases localized to the visible or special body parts (e.g. genitalia) can lead to significant psychosocial problems, including stigmatization. Psoriatic lesions often affect visible parts of the body that may discriminate the individual from others, in other words, stigmatize the patient. Internalized stigma, another dimension of the stigma, is the feeling of stigma experienced by the individual even though he/she is not stigmatized by society. The individual accepts negative stereotypes about the illness created by society and withdraws himself/herself from society with emotions such as worthlessness and shame. The patient presumes that other people have a reaction towards his/her illness and eventually withdraws him/herself from the social life ending up with decreased self-esteem and life-satisfaction, increased depression and suicidality as well as difficulty in coping with the illness. The internalized stigma may affect the quality of life and treatment response negatively. Our recent study (16) has shown that psoriasis patients experience high levels of internalized stigma, which is associated with disease severity, poorer quality of life, negative perceptions of general health and psychological illnesses. The internalized stigma was more pronounced in patients with involvement of visible body parts, genital organs, folds or joints.

Psychosocial influences such as depression, anxiety and stigmatization should be investigated and psychiatric consultation should be requested when necessary.

### **X- Inflammatory Bowel Disease**

Systemic inflammatory response plays an important role in the development of both psoriasis and inflammatory bowel diseases (Crohn's disease and ulcerative colitis). Th17 cells that play an important role in psoriasis produce IL-23. This cytokine plays a key role in intestinal inflammation. Cohen et al. in 12 502 psoriasis patients reported an increase in the frequency of Crohn's disease (0.5% and 0.2%;  $p < 0.001$ ) and ulcerative colitis (0.5% and 0.3%;  $p = 0.002$ ) in psoriasis (17). It should be kept in mind that infliximab, adalimumab, ustekinumab, methotrexate, acitretin, and cyclosporine used to treat psoriasis have gastrointestinal side effects and may mimic inflammatory bowel diseases.





# 4<sup>th</sup> INDERCOS

## Dermatology and Cosmetology Congress with International Participants

27 - 30 MARCH, 2019  
HILTON ISTANBUL BOSPHORUS HOTEL  
ISTANBUL, TURKEY



Additionally, recent evidence suggests that psoriasis may be associated with an increased risk of infection, and an independent risk factor for chronic kidney disease (2).

### References

- 1- Yilmaz, SB, Cicek N, Coskun M, Yegin O, Alpsoy E. Serum and tissue levels of IL-17 in different clinical subtypes of psoriasis. *Arch Dermatol Res* 2012;304(6):465-9.
- 2- Takeshita J, Grewal S, Langan SM, et al. Psoriasis and comorbid diseases: Epidemiology. *J Am Acad Dermatol.* 2017;76(3):377-390.
- 3- Mehta NN, Yu Y, Pinnelas R, et al. Attributable risk estimate of severe psoriasis on major cardiovascular events. *Am J Med.* 2011;124(8):775.e1-e6.
- 4- Armstrong EJ, Harskamp CT, Armstrong AW. Psoriasis and major adverse cardiovascular events: a systematic review and meta-analysis of observational studies. *J Am Heart Assoc.* 2013;2(2):e000062.
- 5- Altekin ER, Koç S, Karakaş MS, Yanıkoğlu A, Başarıcı I, Demir I, Alpsoy E. Determination of subclinical atherosclerosis in plaque type psoriasis patients without traditional risk factors for atherosclerosis. *Türk Kardiyol Dern Ars.* 2012;40(7):574-80.
- 6- Takeshita J, Grewal S, Langan SM, et al. Psoriasis and comorbid diseases: Implications for management. *J Am Acad Dermatol.* 2017;76(3):393-403.
- 7- Armstrong AW, Harskamp CT, Armstrong EJ. The association between psoriasis and obesity: a systematic review and meta-analysis of observational studies. *Nutr Diabetes.* 2012;2:e54.
- 8- Al-Mutairi N, Al-Farag S, Al-Mutairi A, Al-Shiltawy M. Comorbidities associated with psoriasis: an experience from the Middle East. *J Dermatol.* 2010;37(2):146-155.
- 9- Armstrong AW, Harskamp CT, Armstrong EJ. The association between psoriasis and hypertension: a systematic review and meta-analysis of observational studies *J Hypertens.* 2013 Mar;31(3):433-42.
- 10- Cohen AD, Weitzman D, Dreiherr J. Psoriasis and hypertension: a case-control study. *Acta Derm Venereol.* 2010;90(1):23-26.
- 11- Ma C, Harskamp CT, Armstrong EJ, Armstrong AW. The association between psoriasis and dyslipidaemia: a systematic review. *Br J Dermatol.* 2013;168(3):486-495.
- 12- Armstrong AW, Harskamp CT, Armstrong EJ. Psoriasis and metabolic syndrome: a systematic review and meta-analysis of observational studies. *J Am Acad Dermatol.* 2013;68(4):654-662.
- 13- Günaydın A, Aytımur D, Özdemir F. Psoriasis ve metabolik sendrom. *Türkderm* 2014; 48: 95-9.
- 14- Gisondi P, Targher G, Zoppini G, Girolomoni G. Non-alcoholic fatty liver disease in patients with chronic plaque psoriasis. *J Hepatol.* 2009;51(4):758-764.
- 15- Gupta MA, Gupta AK. Depression and suicidal ideation in dermatology patients with acne, alopecia areata, atopic dermatitis and psoriasis. *Br J Dermatol.* 1998;139(5):846-850.
- 16- Alpsoy E, Polat M, Fettahlioglu Karaman B, et al. Internalized stigma in psoriasis; a multicenter study. *J Dermatol.* 2017 Aug;44(8):885-891.
- 17- Cohen AD, Dreiherr J, Birkenfeld S. Psoriasis associated with ulcerative colitis and Crohn's disease. *J Eur Acad Dermatol Venereol.* 2009;23(5):561-565.





# 4<sup>th</sup> INDERCOs

## Dermatology and Cosmetology Congress with International Participants

27 - 30 MARCH, 2019  
HILTON ISTANBUL BOSPHORUS HOTEL  
ISTANBUL, TURKEY



### HAMARTOMAS IN DERMATOLOGY

**Berna Aksoy**

Cutaneous hamartomas comprise an abnormal mixture of a tissue's usual components and it is derived from Greek word hamartia ('to err'). Cutaneous hamartoma is synonymous with naevus which is the Latin word for 'maternal impression' or 'birthmark'. Cutaneous hamartomas are non-neoplastic skin or mucosal lesions and are usually present at or develop soon after birth. Many hamartomas represent genetically altered clones of cells arising from cutaneous mosaicism. Cutaneous hamartomas are usually classified according to the affected cells or tissue component. Epidermal hamartomas are subclassified into keratinocyte hamartomas of epidermal naevi, sebaceous, eccrine and apocrine hamartomas and Becker's naevus. Epidermal hamartomas may be syndromic and affect non-cutaneous tissues or organ systems. Dermal and subcutaneous hamartomas comprise various types of connective tissue hamartomas. Some hamartomas carry a risk of malignant transformation or development of systemic malignancy. If any kind of treatment is needed, most hamartomas can be managed via surgical procedures or laser operations.



# 4<sup>th</sup> INDERCOS

## Dermatology and Cosmetology Congress with International Participants

27 - 30 MARCH, 2019  
HILTON ISTANBUL BOSPHORUS HOTEL  
ISTANBUL, TURKEY



### PHANTOM SIGN ON SKIN

#### Aslı Tatlıparmak

The phenomenon of phantom pain was first associated to amputation of injured limbs during the war. Individuals who had lost a limb consistently reported a feeling that it still existed, associated in some cases, to severe pain. Amputees invariably continue to perceive a ghost of their amputated limb as a phantom also. The phantom limb is often plagued by unpleasant, annoying, or distressing phantom pain, but may also retain other features that suggest it is still highly represented in proprioceptive body maps. These include (a) the perception of bodily aspects of phantom limbs including the size (e.g., compared to the intact limb, thinner, or thicker/swollen), shape, posture, and telescoping (or shortening) of the phantom; (b) exteroceptive and proprioceptive sensations (e.g., touch, pressure, temperature, itching, vibration, pins, and needles, 'electric'/shooting); and (c) prosthesis embodiment. Embodiment involves the perception that one's sense of self is localized within one's bodily borders but may extend to a habitually used tool or prosthesis that effectively extends the body's area of influence. After surgery, patients frequently report a series of abnormal sensations, especially a perceptual alteration of limb position. These abnormal sensations have been named, perhaps incorrectly, phantom limb syndrome (PLS), as they are reminiscent of the symptoms reported by amputees who still report sensations in their missing limb. PLS is seldom serious nor is it life threatening. Nevertheless, it can be unpleasant and distressing to patients, lengthen the time to recovery and resumption of normal activity, and, in some cases, may increase the intensity of other postoperative symptoms and complications. Kinaesthetic illusions may result from changes in neuronal activity and/or topographic reorganization within the somatosensory cortex. Phantom sign about ears (vibration/ringing), eyes, rectum, breast, are also defined.



# 4<sup>th</sup> INDERCOS

## Dermatology and Cosmetology Congress with International Participants

27 - 30 MARCH, 2019  
HILTON ISTANBUL BOSPHORUS HOTEL  
ISTANBUL, TURKEY



### DOPING RELATED SKIN DISEASES

Gül Yıldırım

Doping in sport is a widespread problem not just among elite athletes, but even more so in recreational sports. Athletes use prohibited drugs or methods for improving their performance and sporting results. In earliest Olympic Games cocaine, heroin and morphine were used to get better race results. Today anabolic agents, steroids, hormones, diuretics, narcotics, cannabinoids are used for doping purposes. In scientific literature major emphasis is placed on doping detection. Detrimental effects of doping agents on athletes health are seldom discussed. Here we will have a look side effects of doping agents on skin.

#### References:

1. Intern Med J 2015 Mar; 45(3): 239-48.
2. Sports Med 2004; 34: 513-54.
3. Br J Sports Med 1997;31: 54-58.
4. N Engl J Med 351; 9, 2004.
5. Acta Dermatoven APA Vol 16, 2007 No:3
6. Clin Exp Dermatol. 2006 Jan; 31(1): 134-6.



# 4<sup>th</sup> INDERCOS

## Dermatology and Cosmetology Congress with International Participants

27 - 30 MARCH, 2019  
HILTON ISTANBUL BOSPHORUS HOTEL  
ISTANBUL, TURKEY



### UROCANIC ACID IN THE SKIN: A MIXED BLESSING

**Aslı Tatlıparmak**

The presence of epidermal urocanic acid (UCA) was first proven in the 1950s. UCA is a major epidermal chromophore formed in the epidermis and absorbs ultraviolet (UV) B radiation. The trans-isomer of UCA (T-UCA) is a natural component of stratum corneum that can be detected in suction blister fluid from normal skin. It is formed from histidine and effectively absorbs UVB resulting in its transformation into cis-UCA (C-UCA). C-UCA has been implicated in the suppression of several different immune processes. These include the downregulation of contact sensitization and delayed-type hypersensitivity responses, reduction in natural killer cell activity, inhibition in the antigen presenting function of epidermal cells and the prolonged survival of organ transplants.

Its photoprotective effect against DNA damage and apoptosis has been demonstrated in mice lacking T-UCA. Mice lacking histidase are unable to synthesize T-UCA from histidine and do not become immunosuppressed after UV radiation exposure. Also, pretreatment of mice with C-UCA, but not T-UCA, results in prolonged skin graft survival. It has long been hypothesized that the effects of cis-UCA are mediated through a membrane receptor. Although a specific keratinocyte receptor for cis-UCA has not been identified.

Since keratinocytes represent the site of synthesis of UCA, and can produce a variety of cytokines following UVB irradiation, it is possible that C-UCA could exert its modulating effects by inducing the expression of an immunosuppressive cytokine such as interleukin -10, TNF alpha or transforming growth factor beta. It also acts on macrophages to downregulate MHC Class-II expression, resulting in the inhibition of cytokine synthesis by activated T cells and natural killer cells. IL-10 is upregulated in murine keratinocytes by UVB irradiation and is known to be one mediator of the UVB-induced reduction in delayed-type hypersensitivity responses.



# 4<sup>th</sup> INDERCOS

## Dermatology and Cosmetology Congress with International Participants

27 - 30 MARCH, 2019  
HILTON ISTANBUL BOSPHORUS HOTEL  
ISTANBUL, TURKEY



### THE METABOLIC SYNDROME RELATED SKIN DISEASES

Ayşe Serap Karadağ

The metabolic syndrome (MetS) consists of such risk factors as abdominal obesity, dyslipidemia, glucose intolerance, and hypertension—which develop further issues for health. The rate of the world's population affected by MetS is about 25%, which includes a subpopulation associated with inflammatory skin diseases (1). Scientific interest about comorbidities linked with the MetS is still ongoing. Also, the existence of high numbers of oxidative stress and inflammatory markers in many skin diseases observed on the MetS has been shown in several studies. Indeed, pathophysiological dysfunctions resulting in losing metabolic body control may lead to cutaneous disease. Inflammatory markers such as TNF- $\alpha$ , IL-17, IL-23 and oxidative stress is observed in various autoimmune and inflammatory issues on the skin that are certainly present in both conditions (2,3).

Some skin diseases such as psoriasis, hidradenitis suppurativa, acne and acanthosis nigricans are strongly associated with MetS. The others have shown moderate relation with MetS components; eg androgenetic alopecia, atopic dermatitis, skin tags, and necrobiotic lipoidika. Some diseases represent some components of Met S in a few patients and the association with Met S is very weak and needs clarification with new studies over time. To illustrate, Behçet's disease, chronic urticaria, granuloma annulare, lupus erythematosus, recurrent aphthous stomatitis, rosacea, eruptive xanthomas, scleredema diabeticorum, lichen planus, Sjögren syndrome, vasculitis and vitiligo were among them (1). In this speech, skin diseases strongly associated with Met S will be discussed.

#### **Psoriasis and Met Syndrome**

Chronic plaque psoriasis is an inflammatory and an immune-mediated skin disease which significantly links with the clinical features of the MetS consisting abdominal obesity, hypertension, type 2 diabetes, insulin resistance, atherogenic dyslipidemia, and non-alcoholic fatty liver disease. The prevalence of MetS in patients who have psoriasis varies from 20% to 50%, and the risk to have MetS is two times higher at least in psoriatic patients when compared to nonpsoriatic person. Evidence now shows that psoriasis and MetS have common genetic baseline, metabolic risk factors and pathogenic mechanism (4,5).

Systemic conventional treatments need to be applied cautiously in psoriatic patients who have MetS, since coexisting metabolic disorders can be adversely affected, specifically in chronic use cases. Biologics seem to have a changing safety profile when compared to conventional treatments, thus they are generally tolerated, except the increased risk for obesity with anti-TNF agents (4).

Studies revealed that MetS is more frequently observed in female psoriasis patients than in males. It is more frequent in patients above 40 years of age. MetS is more widespread in patients who have severe psoriasis than in the ones who have mild skin disease as well (4,6).

#### **Should we check all Psoriasis patients for MetS?**

To uncover the ones that are at high risk and managed suboptimally, screening patients that are psoriatic for CVD risk elements might be helpful. Recent algorithm for patients with psoriasis and MetS was published by Radtke et al. (7). Algorithm suggests that patients with psoriasis and MetS are required referral for further management when three of these criteria are developed:

visceral obesity (waist circumference > 94 cm in men or > 80 cm in women),  
triglycerides > 150 mg/dl or on specific therapy,  
HDL < 40 mg/dl in men or < 50 mg/dl in women or on specific treatment,  
systolic pressure > 130 mmHg or diastolic > 85 mmHg or on treatment,  
fasting plasma glucose > 100 mg/dl.

While follow up is needed every 6 months for severe psoriasis (or for the ones on systemic medication), annual follow up is required for milder cases. Also, changing the way of life, like smoking and alcohol cessation, eating habits and exercise ought to be followed (4,7).

#### **Hidradenitis suppurativa and Metabolic Syndrome**

Hidradenitis suppurativa (HS) has a chronic inflammatory nature, so its relation with MetS have been tried to explain by many studies. (8).

A strong association of HS and MetS was found in a largest case control study from the Israeli Health Service database. In these study, the data from 3207 HS patients and 6412 control individuals were screened for MetS





# 4<sup>th</sup> INDERCOS

## Dermatology and Cosmetology Congress with International Participants

27 - 30 MARCH, 2019  
HILTON ISTANBUL BOSPHORUS HOTEL  
ISTANBUL, TURKEY



and the risk of MetS in the HS group increased by 2.08-3.89 times. The obesity, hypertriglyceridemia, and glucose intolerance risk was crucially higher in the HS group than in the control as well (9).

The relation of MetS with HS may not be restricted to severe ones. No association of the rate of MetS and HS severity and the time length and the number of MetS elements are found. The result in a HS population is contrasting with the ones found in patients who have psoriasis, where MetS has been resulted to be directly linked with the duration and severity of the disease, showing that metabolic changes come later than cutaneous inflammation (9,10).

### **Should we check all HS patients for MetS?**

Current data requires screening HS patients for elements of MetS regardless of age and severity. With the goal of avoiding cardiovascular disease and improving life expectancy, managing HS cases needs to contain an evaluation for MetS and patient awareness that includes lifestyle modifications, losing weight, being physically more active, avoiding the consumption of tobacco, as well as medical therapy, as a part of routine treatment (8-10).

### **Acne Vulgaris and Metabolic Syndrome**

Acne is most commonly seen disease in the adolescent population. Acne and the association with MetS has been recently discussed in the literature. One of the discussing points is acne and hyperglycemic diet as well as the other subject acne and related hormonal problems and syndromes related to MetS components (2).

In Westernized populations, acne vulgaris is affecting 85% of adolescents. Epidemiologic studies showed that high glycemic load and milk consumption are the two main nutrients of Western diet promoting or aggravating acne vulgaris. Acne has not been detected in non-Westernized populations who still live on Paleolithic diets restricting hyperglycemic carbohydrates, dairy products and milk (11).

Acne vulgaris, has been recognised as a member of mTORC1-driven metabolic illnesses family. Higher mTORC1 signaling is characterized with insulin resistance, type 2 diabetes mellitus, cancer, obesity, and neurodegenerative illnesses. Higher mTORC1 activity has been seen in patients with lesional skin and sebaceous glands of acne. Higher mTORC1/SREBP1 signaling induced by a Western diet, is superimposed on IGF 1-mediated mTORC1 activation during puberty (11).

Acne is a widespread component of seborrhea-acne-hirsutism-androgenetic alopecia (SAHA) syndrome, polycystic ovary syndrome, and hyperandrogenism, insulin resistance, and acanthosis nigricans (HAIR-AN) syndrome, all of which are linked to insulin resistance (12). An increase is seen in the prevalence of Met S in acne which is linked with polycystic ovary syndrome. Fasting insulin levels and HOMA are significantly higher among patients with acne compared with non-acne controls.

### **Should we check all acne patients for MetS?**

It is not clear yet, but the hormonal status, and diet is needed to be revised for acne patients. As a result, drugs and treatment alternatives that attenuate mTORC1/SREBP1-mediated sebum production by regulation of mTORC1- and FoxO1- dependent signaling pathways need to be found. There has been current interest in the use of metformin for the treatment of dermatologic disorders that displays insulin resistance including acne vulgaris. Metformin is also a perfect substitute and has been detected to function as an mTORC1 inhibitor. A low glycemic load diet reduced SREBP expression in the sebaceous glands of acne patients. Vitamin D substitution in acne via attenuation of mTORC1 signaling might decrease the production of sebum and raise the expression of the antimicrobial peptide cathelicidin, which can kill *P.acnes* (11).

The dermatologist considering the impact of exacerbated mTORC1 signaling in the pathogenesis of acne has a great opportunity of reverting the adolescent patient from the proceeding march to the MetS (11).

### **Acanthosis nigricans and Metabolic Syndrome**

Acanthosis nigricans (AN) which is a reactive cutaneous change is closely linked with obesity, and hyperinsulinemia; insulin resistance, or malignancy. Evidence reveals that AN is a helpful clinical signal to detect patients that are prone to insulin resistance, and type 2 diabetes. It is ambiguous if AN can be accepted as a risk element for the diagnosis of MetS, like large waist circumference and elevated blood pressure. Correlation between AN and degree of insulin resistance, and dyslipidemia needs confirmation (13).

### **Should we check all acanthosis nigricans patients for MetS?**

Yes, obesity and insulin resistance are most significant reasons of AN. All patients should be evaluated for diabetes, and obesity. Insulin sensitizers, e.g. metformin is promising. Modifying lifestyle to reduce the manifestations of MetS is useful. Eliminating insulin resistance or obesity may be beneficial in the first phases of the disorder (13,14).

### **Androgenetic Alopecia and Met S**

The interest in androgenetic alopecia (AGA) and its association with the MetS have increased since 1972, when the



# 4<sup>th</sup> INDERCOS

## Dermatology and Cosmetology Congress with International Participants

27 - 30 MARCH, 2019  
HILTON ISTANBUL BOSPHORUS HOTEL  
ISTANBUL, TURKEY



initial association between cardiovascular risk elements and hair loss was suggested. Among the several types of hair loss, AGA is most strongly linked with the MetS and metabolic-related conditions (15).

Some other metabolic-related conditions are associated with AGA as well, including coronary artery disease, polycystic ovary syndrome, several nutritional deficiencies, which all have caused many observed in 22.4% of the patients with AGA and 9.4% of the controls. Abdominal obesity, hypertension and lowered high-density lipoprotein were significantly higher in patients with androgenic alopecia versus their respective controls (16).

Even though certain guidelines have not been set up for the screening of AGA patients for MetS together with cardiovascular risk factors, it is worth considering that would support the bigger picture—preventing cardiovascular morbidity and mortality (15).

### The Other Skin Diseases and Metabolic Syndrome

Some inflammatory skin diseases, such as atopic dermatitis, skin tags, necrobiotic lipoidika, vitiligo, scleredema, recurrent aphthous stomatitis, Behçet disease, rosacea, necrobiosis lipoidica, granuloma annulare, skin tags, knuckle pads, and eruptive xanthomas, are possibly associated with MetS, or some of the MetS compounds (17). But more studies are required to prove this association.

### REFERENCES

- Karadağ AS, Lavery MJ. Skin and the metabolic syndrome. *Clin Dermatol.* 2018;36(1):1-2.
- Stefanadi EC, Dimitrakakis G, Antoniou CK, et al. Metabolic syndrome and the skin: a more than superficial association. Reviewing the association between skin diseases and metabolic syndrome and a clinical decision algorithm for high risk patients. *Diabetol Metab Syndr.* 2018 Feb 21;10:9.
- Engin B, Özkoca D, Kutlubay Z, Serdaroğlu S. Metabolic Syndrome in Dermatology: Treatment and Management for Dermatologists. *Dermatol Ther.* 2019 Jan 8:e12812.
- Gisoni P, Fostini AC, Fossà I, Girolomoni G, Targher G. Psoriasis and the metabolic syndrome. *Clin Dermatol.* 2018 Jan - Feb;36(1):21-28.
- Rodríguez-Zúñiga MJM, García-Perdomo HA. Systematic review and meta-analysis of the association between psoriasis and metabolic syndrome. *J Am Acad Dermatol.* 2017 Oct;77(4):657-666.e8.
- Singh S, Young P, Armstrong AW. An update on psoriasis and metabolic syndrome: A meta-analysis of observational studies. *PLoS One.* 2017;12(7):e0181039.
- Radtke MA, Mrowietz U, Feuerhahn J, et al. Early detection of comorbidity in psoriasis: recommendations of the National Conference on Healthcare in Psoriasis. *J Dtsch Dermatol Ges.* 2015;13(7):674-690.
- Ergun T. Hidradenitis suppurativa and the metabolic syndrome. *Clin Dermatol.* 2018;36(1):41-47.
- Shalom G, Freud T, Harman-Boehm I, Polishchuk I, Cohen AD. Hidradenitis suppurativa and metabolic syndrome: a comparative cross-sectional study of 3207 patients. *Br J Dermatol.* 2015 Aug;173(2):464-70.
- Vossen ARJV, van der Zee HH, Onderdijk AJ, Boer J, Prens EP. Hidradenitis suppurativa is not associated with the metabolic syndrome based on body type: A cross-sectional study. *J Dermatol.* 2017 Feb;44(2):154-159.
- Melnik BC. Acne vulgaris: The metabolic syndrome of the pilosebaceous follicle. *Clin Dermatol.* 2018;36(1):29-40.
- Chen W, Obermayer-Pietsch B, Hong JB, et al. Acne-associated syndromes: models for better understanding of acne pathogenesis. *J Eur Acad Dermatol Venereol.* 2011;25(6):637-46.
- Karadağ AS, You Y, Danarti R, Al-Khuzaei S, Chen W. Acanthosis nigricans and the metabolic syndrome. *Clin Dermatol.* 2018;36(1):48-53.
- Panda S, Das A, Lahiri K, Chatterjee M, Padhi T, Rathi S, Dhar S, Sarma N. Facial Acanthosis Nigricans: A Morphological Marker of Metabolic Syndrome. *Indian J Dermatol.* 2017;62(6):591-597.
- Lie C, Liew CF, Oon HH. Alopecia and the metabolic syndrome. *Clin Dermatol.* 2018;36(1):54-61.
- Dharam Kumar KC, Kishan Kumar YH, Neladimmanahally V. Association of Androgenetic Alopecia with Metabolic Syndrome: A Case-control Study on 100 Patients in a Tertiary Care Hospital in South India. *Indian J Endocrinol Metab.* 2018;22(2):196-199.
- Seremet S, Gurel MS. Miscellaneous skin disease and the metabolic syndrome. *Clin Dermatol.* 2018;36(1):94-100.



# 4<sup>th</sup> INDERCOS

## Dermatology and Cosmetology Congress with International Participants

27 - 30 MARCH, 2019  
HILTON ISTANBUL BOSPHORUS HOTEL  
ISTANBUL, TURKEY



### AZELAIC ACID IN DERMATOLOGY

#### Işıl Bulur

Azelaic acid (AzA) is a medium chain dicarboxylic acid derivative found in whole grain cereals and animal products, and it is normally present in human plasma. AzA inhibits the production of free radical oxygen, reduces expression of kallikrein-5 (KLK-5) and pro-inflammatory cathelicidins such as LL-37, as well as inhibits toll-like receptor 2 (TLR-2) (1-5). In addition anti-inflammatory properties, azelaic acid has antimicrobial activity against *Propionibacterium acnes* and *Staphylococcus epidermidis* as well as moderate anti-comedogenic properties via modification of epidermal keratinization. It also inhibits the pigment producing enzyme tyrosinase (1-5).

Azelaic acid with this effects is used in the treatment of rosacea, acne vulgaris, melasma and postinflammatory hyperpigmentation in dermatology (6-7). This dicarboxylic acid is a relatively safe, although mildly irritant. It is available in a 10–20 % concentration gel-cream, and applied twice daily.

Sieber MA, Hegel JK. Azelaic acid: Properties and mode of action. *Skin Pharmacol Physiol*. 2014;27 Suppl 1:9-17.

Thiboutot D: Versatility of azelaic acid 15% gel in treatment of inflammatory acne vulgaris. *J Drugs Dermatol* 2008; 7: 13–16.

Mastrofrancesco A, Ottaviani M, Aspite N, Cardinali G, Izzo E, Graupe K, Zouboulis CC, Camera E, Picardo M: Azelaic acid modulates the inflammatory response in normal human keratinocytes through PPAR $\gamma$  activation. *Exp Dermatol* 2010; 19: 813–820.

Briganti S, Flori E, Mastrofrancesco A, Kovacs D, Camera E, Ludovici M, Cardinali G, Picardo M: Azelaic acid reduced senescence like phenotype in photo-irradiated human dermal fibroblasts: possible implication of PPAR $\gamma$ . *Exp Dermatol* 2013; 22: 41–47.

Yamasaki Y, Gallo RL: Azelaic acid gel alters kallikrein 5 and cathelicidin expression in epidermal keratinocytes, critical elements in the pathogenesis of rosacea.

Del Rosso JQ. The use of topical azelaic acid for common skin disorders other than inflammatory rosacea. *Cutis*. 2006 Feb;77(2 Suppl):22-4.

Elewski B, Thiboutot D. A clinical overview of azelaic acid. *Cutis*. 2006 Feb;77(2 Suppl):12-6.





# 4<sup>th</sup> INDERCOS

## Dermatology and Cosmetology Congress with International Participants

27 - 30 MARCH, 2019  
HILTON ISTANBUL BOSPHORUS HOTEL  
ISTANBUL, TURKEY



### SADBE/DCP IN DERMATOLOGY

**Murat Durdu**

Topical immunotherapy involves the therapeutic use of contact sensitizers on the skin. This treatment has been tried in a wide variety of disorders including alopecia areata, warts and cutaneous malignancy. This presentation will focus on alopecia areata and recalcitrant viral warts. Alopecia areata constitutes 1-4% of the patients admitted to dermatology clinics. Of patients with alopecia areata, 80% have only a single patch. In 1-5% of the patients, the disease affect the whole body and scalp. There is no problem in the treatment of localized forms. Alopecia areata, which is a problem in treatment, are multifocal alopecia areata, ophiasis pattern alopecia areata, alopecia patients with more than 50% hair loss, alopecia totalis ve alopecia universalis. In recent years, topical immunotherapy is the first recommended in such resistant cases. During the past four decades, four different sensitizing agents have been used. Since the mutagenic effects of the first two substances (triethyleneiminobenzoquinone, dinitrochlorobenzene) were determined, they are not used today. Nowadays, the most commonly used sensitizing agents are squaric acid dibutylester (SADBE) and diphencyprone (DCP). DCP is available as 1 and 5 g powder in amber-colored glass bottles. DCP dissolves better in acetone. Initial sensitization is carried out with a 2% solution, which is made by dissolving 20 mg in 1 ml of acetone. Further dilution can be prepared by making a stock solution of 2% and diluting with acetone taken in a pipette as per the concentration. To prepare a 0.001% solution, 0.1 ml of stock solution is mixed with 200 ml of acetone.

For sensitization, DCP 2% solution is applied to a 4x4 cm area of scalp. Application area should be protected from light and sun for two days. Application area should be covered with hat, headscarf, beret or wig. Two days later, application area is checked for vesicle and bulla formation. If the blisters develop, topical corticosteroid should be applied to the affected area. Two weeks later, a 0.001% DPCP solution is applied to one side of the scalp. Application is made with a cotton swab or brush. The concentration of DCP is increased gradually each week until a mild dermatitis reaction is obtained. The goal is to achieve a low-grade erythema and pruritus on the treated area for 48 hours after application. When terminal hair regrowth is noted on application area of scalp the entire scalp is treated with DCP. If hair regrowth is not observed after the first 30 weeks, the patient is considered a "non-responder. There is no fully accepted maintenance protocol. However, maintenance therapy is recommended for 6-12 months. If alopecia recurs after treatment, immunotherapy can be started once a week again. If the patient does not develop an allergic reaction to 2% DCP, SADBE can be used. To avoid the development of tolerance, patients should avoid exposure to ultraviolet. The combination therapy with DCP and anthralin is superior to the DCP therapy in terms of efficacy, the time to onset of hair regrowth, and the time to complete hair regrowth. Adverse effects include hypopigmentation, hyperpigmentation, vitiligo, urticaria, angioedema, vesicular or bullous reaction, generalised eczema, erythema multiforme, pruritus, cervical and occipital lymphadenopathy and flu-like symptoms. In alopecia areata, response rate to topical immunotherapy with DCP and SADBE varies between 50% and 80% DPCP.

For the immunotherapy of warts, the sensitizing agent is applied on the arm with 2% DPC or SADBE. After 3 weeks, the patient may be treated with rechallenge, and treatments should be repeated every 2 to 3 weeks. The patient then continues at this dose until clearance. Response to treatment varies between 8% and 88%.



# 4<sup>th</sup> INDERCOS

## Dermatology and Cosmetology Congress with International Participants

27 - 30 MARCH, 2019  
HILTON ISTANBUL BOSPHORUS HOTEL  
ISTANBUL, TURKEY



### USE OF PODOPHYLLIN AND PODOPHYLLOTOXIN IN DERMATOLOGY

**Zoran Nedic**

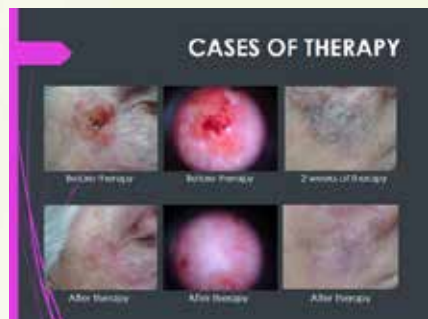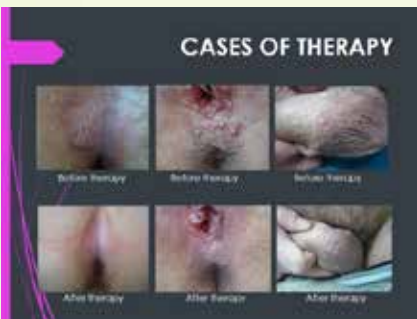Podophyllin is the dried resin, extracted from the roots and rhizomes of Podophyllum plants. That is an amorphous powder, light brown to green yellow in color, which turns darker when exposed to light. The first report on the use of podophyllin was given by Kaplan 1942.

It is an antimitotic and caustic agent. That easily cross cell membranes leads to inhibit cell mitosis and DNA synthesis. It often causes local necrosis and death of tumor cells and erosion of the tissues.

Long considered the therapy of first choice against condylomata acuminata. Works on the use of podophyllin in the treatment of BCC were published. Podophyllin must be applied only under medical supervision. Once weekly, in order to accomplish a cumulative antiwart effect. To leave to 6 hours and carefully washed. Maximum six weeks in one cycle. Relapse rates have varied within in the range of 20–74%. May cause unpredictable and sometimes severe local side effects such as pronounced burns and ulcerations associated with painful tissue reactions.

Podophyllotoxin is the purified biologically active ingredient of podophyllin. Products are available as 0.5% ethanol and 0.15% cream. Applied twice daily for 3 consecutive days, followed by 4 days break, four or more cycles. Complete remission in patients with podophyllotoxin was achieved in 78-81%. Risk of local and systemic toxicity is regarded as minimal. The procedure is convenient, safe, highly effective, and cost-effective treatment than podophyllin.

Podophyllin and podophyllotoxin are one of therapy modalities of condylomas and sBCC. Advantage of topical therapy with podophyllin and podophyllotoxin are targeted lesion therapy, simple and easy application, good cosmetic effect. This types of therapy maybe recommended in the case when impossibility of surgical operation, in elderly patients and patients who have surgical phobia.







# 4<sup>th</sup> INDERCOS

## Dermatology and Cosmetology Congress with International Participants

27 - 30 MARCH, 2019  
HILTON ISTANBUL BOSPHORUS HOTEL  
ISTANBUL, TURKEY



### GUIDELINES FOR THE MANAGEMENT OF VULVODYNIA

Gudula Kirtschig

According to the 2003 International Society for the Study of Vulvovaginal Diseases (ISSVD) terminology, vulvodynia is defined as 'vulval discomfort, most often described as burning pain, occurring in the absence of relevant visible findings or a specific, clinically identifiable, neurological disorder'. Vulvodynia is also categorized by the ISSVD, as generalized or localized, provoked, unprovoked or mixed (both provoked and unprovoked).

Differential diagnoses are vulval conditions either inflammatory, infectious or neoplastic responsible for vulval discomfort detectable by inspection or neurological conditions responsible for perineal pain suspected on sphincter disturbances and objective neurological abnormalities. Imaging (pelvic and lumbosacral MRI) is indicated in cases of spontaneous generalized vulval pain resistant to treatments. Patients should be given a full explanation of their condition verbally, and then reinforced with written information. Do not cast doubt about the reality of the pain (not 'in the head') and acknowledge its significant impact on all aspects of the quality of life. Explain simply the current knowledge about mechanisms, contributing factors, treatment and prognosis. A multidisciplinary approach to patients with vulvodynia is widely recommended. However, the levels of evidence are poor. Topical and systemic analgesic treatments are first line treatment, surgical interventions are indicated only rarely.

Andrews JC. Vulvodynia interventions—systematic review and evidence grading. *Obstet Gynecol Surv* 2011; 66: 299–315.

W.I. van der Meijden, 1,\* M.J. Boffa, 2 W.A. ter Harmsel et al. 2016 European guideline for the management of vulval conditions. *J Eur Acad Dermatol Venereol* 2017 ;31:925-941.

#### **Lichen planus of the mucosae: Symptoms, diagnosis, therapeutic procedures**

Mucosal lichen planus (LP) affecting the oral and genital mucosa is a painful and disabling inflammatory skin disease that is highly resistant to treatment. There is paucity of evidence regarding therapy, randomized controlled trials (RCTs) for the treatment of oral disease exist but are lacking for genital mucosal LP. (Suresh; Cheng; Simpson) A systematic review on treatment for oral LP (OLP) concludes that there is no strong evidence suggesting superiority of any specific intervention in reducing pain and clinical signs of OLP. Authors request future RCTs on a larger scale using standardized outcome measures. (Suresh) However, core outcome sets for clinical trials in vulvovaginal disease have to be developed. (Foster 2017) A recently conducted RCT on genital LP failed to recruit the required number of patients but concluded that patients with vulval LP are reluctant to receive systemic treatment for their disease. (Simpson)

Therefore topical steroids remain the recommended first line treatment for both OLP and genital LP even though they fail in at least 25% of treated patients. (Laeijendecker; vd Meijden) Topical calcineurin inhibitors, e.g. tacrolimus, are recommended second line only in treatment resistant patients even though small studies indicate a better treatment effect. There are several reasons for them not to be used first line: (a) they are not licensed for the treatment of LP, (b) they are associated with a burning sensation at the site of application leading to treatment cessation, (c) practical aspects of the application at mucosal sites, and (d) the potential risk of increased cancer development. (Morita)

However, painful mucosal LP is associated with a decreased quality of life and therefore requests treatment. (Radwan-Oczko)



# 4<sup>th</sup> INDERCOS

## Dermatology and Cosmetology Congress with International Participants

27 - 30 MARCH, 2019  
HILTON ISTANBUL BOSPHORUS HOTEL  
ISTANBUL, TURKEY



The combination of topical tacrolimus and potent topical corticosteroids was used in single cases for the treatment of cutaneous lupus erythematosus (Madan) and for mucosal LP of the oesophagus.(Keate) The combined application of potent steroids and tacrolimus is thought to be more effective than each agent on its own, clinical trials to proof this are needed.

Suresh SS, Chokshi K, Desai S, et al. Medical Management of Oral Lichen Planus: A Systematic Review. *J Clin Diagn Res.* 2016;10:ZE10–ZE15.

Cheng S, Kirtschig G, Cooper S, Thornhill M, Leonardi-Bee J, Murphy R. Interventions for erosive lichen planus affecting mucosal sites. *Cochrane Database Syst Rev.* 2012;2.

Simpson RC, Murphy R, Bratton DJ, et al. Systemic therapy for vulval Erosive Lichen Planus (the, hELP' trial): study protocol for a randomised controlled trial. *Trials.* 2016;17:2.

Foster DC, Stockdale CK, Simpson R, Kirtschig G. Core Outcome Sets for Clinical Trials and Observational Studies in Vulvovaginal Disease. *J Low Genit Tract Dis.* 2017;21:163-5

Keate RF, Williams JW, Connolly SM. Lichen planus esophagitis: report of three patients treated with oral tacrolimus or intraesophageal corticosteroid injections or both. *Dis Esophagus.* 2003;16:47-53.

Radwan-Oczko M, Zwyrtek E, Owczarek JE, Szczesniak D. Profile and quality of life of patients with oral lichen planus. *J Appl Oral Sci.* 2018; 26: e20170146.

van der Meijden WJ, Boffa MJ, Ter Harmsel WA, et al. 2016 European guideline for the management of vulval conditions. *J Eur Acad Dermatol Venereol.* 2017 Jun;31(6):925-941.

Laeijendecker R, Tank B, Dekker SK, Neumann HA. A comparison of treatment of oral lichen planus with topical tacrolimus and triamcinolone acetonide ointment. *Acta Derm Venereol.* 2006;86:227-9.

Vente C, Reich K, Rupprecht R, Neumann C. Göttingen Erosive mucosal lichen planus: response to topical treatment with tacrolimus. *Br J Dermatol.* 1999;140:338-42.

Morita M, Asoda S, Tsunoda K, Soma T, Nakagawa T, Shirakawa M, Shoji H, Yagishita H, Nishikawa T, Kawana H. The onset risk of carcinoma in patients continuing tacrolimus topical treatment for oral lichen planus: a case report. *Odontology.* 2017;105:262-266

Madan V, August PJ, Chalmers RJ. Efficacy of topical tacrolimus 0.3% in clobetasol propionate 0.05% ointment in therapy-resistant cutaneous lupus erythematosus: a cohort study. *Clin Exp Dermatol.* 2010;35:27-30.

### **Lentigo maligna: What's new in its treatment?**

Lentigo maligna (LM) is considered a type of melanoma in situ, which occurs in the elderly population with a fair skin type. It typically occurs on chronic sun-exposed skin such as the head and neck area. Lentigo maligna (LM) is treated to prevent progression to lentigo maligna melanoma (LMM). It was reported that the cumulative risk of LMM after a LM is 2.0-2.6% after 25 years. According to the current European consensus guideline surgery is the gold standard of treatment, radiotherapy, cryotherapy, topical imiquimod or watchful waiting are mentioned in the guideline, but there is no treatment algorithm. Surgical excision of larger lesions can lead to disfiguring scars or functional impairment and radiotherapy can potentially cause secondary malignancies, radiodermatitis, as well as disfiguring scars. An alternative option is off-label 5% topical imiquimod application. The response rate of off-label topical imiquimod for LM has been reported to vary between 37-79%.

Work Group, Swetter SM, et al. Guidelines of care for the management of primary cutaneous melanoma. *J Am Acad Dermatol.* 2019;80:208-250.



# 4<sup>th</sup> INDERCOS

## Dermatology and Cosmetology Congress with International Participants



27 - 30 MARCH, 2019  
HILTON ISTANBUL BOSPHORUS HOTEL  
ISTANBUL, TURKEY

Tio D, Prinsen CAC, Dréno B, et al. Variation in the diagnosis and clinical management of lentigo maligna across Europe: a survey study among European Association of Dermatologists and Venereologists members. *J Eur Acad Dermatol Venereol.* 2018;32:1476-1484.

Tio D, van der Woude J, Prinsen CAC, et al. systematic review on the role of imiquimod in lentigo maligna and lentigo maligna melanoma: need for standardization of treatment schedule and outcome measures. *J Eur Acad Dermatol Venereol.* 2017;31:616-624.

Read T, Noonan C, David M, et al. A systematic review of non-surgical treatments for lentigo maligna. *J Eur Acad Dermatol Venereol.* 2016;30:748-53.

Garbe C, Peris K, Hauschild A *et al.* Diagnosis and treatment of melanoma. European consensus-based interdisciplinary guideline - Update 2016. *Eur J Cancer* 2016; 63: 201-17

Mora AN, Karia PS, Nguyen BM. A quantitative systematic review of the efficacy of imiquimod monotherapy for lentigo maligna and an analysis of factors that affect tumor clearance. *J Am Acad Dermatol.* 2015;73:205-12.



# 4<sup>th</sup> INDERCOS

## Dermatology and Cosmetology Congress with International Participants

27 - 30 MARCH, 2019  
HILTON ISTANBUL BOSPHORUS HOTEL  
ISTANBUL, TURKEY



### CUTANEOUS FINDINGS IN THE ELDERLY

**Ayşe Ferzan Aytuğ**

Ageing is a complex process affecting every organ. It is a natural, inevitable and continuous process. According to ethnic concerns and overpopulation; Should we cure ageing?

The International League of Dermatological Societies (2013) identified and prioritized skin ageing and its consequences as one of the most important grand challenges in global skin health.

As life expectancy increases, age related diseases, lifestyle habits, and environmental factors have a cumulative and synergistic effects on skin aging.

The goal of biomedical research is to help people be as healthy as possible for as long as possible. Slowing ageing is possible by reversing age related degenerative changes and diseases. To promote "healthy ageing" is the goal of challenge.

The current perception of ageing is to accept the temporary nature of life, while differing as long as possible the appearance of the signs of ageing.

Maintaining the functional and anatomical integrity of the skin is essential. The challenge goes beyond maintaining appearance. The physical appearance in advanced age is important for emotional, mental and psychosocial well-being.

Ageing is associated with physiological (structural and functional) changes in the skin; Thinning of epidermis and dermis, fragmentation of collagen and elastic fibres, decreased cell healing and DNA repair, decrease in melanocytes, reduced function of sebaceous glands, decrease in skin lipids, vascularity and supporting structures.

The most common skin conditions in the elderly are pruritus, eczematous dermatoses, infections and skin malignancies.

There should be a full dermatological examination in admitted elderly patients looking for undiagnosed dermatoses, infections, skin cancers and manifestations of underlying systemic diseases.

Skin problems have a huge impact on working ability in the aged and microeconomics. Prevention is far more effective and less costly than treatment!

Simple supportive and cosmetic approaches are life enhancing treatments important for healthier and more active ageing.





# 4<sup>th</sup> INDERCOS

## Dermatology and Cosmetology Congress with International Participants

27 - 30 MARCH, 2019  
HILTON ISTANBUL BOSPHORUS HOTEL  
ISTANBUL, TURKEY



### PATTERNS OF HYPERHIDROSIS AND DERMATOLOGIC APPROACHES

Pelin Kuteyla Can

The term of hyperhidrosis is pathological sweating that exceeds the requirements of thermoregulation (1). The symptoms of hyperhidrosis can significantly affect a patient's quality of life, and can lead to social embarrassment, loneliness, anxiety and depression (1,2). Hyperhidrosis can be primary or secondary and may have general, regional, or focal manifestations (3). Excessive sweating restricted to specific parts of the body is termed as focal hyperhidrosis. Primary focal hyperhidrosis is a disorder of excessive, bilateral, and relatively symmetric sweating occurring in the axillae, palms, soles, or craniofacial region (1,3,4). The diagnostic criteria for primary focal hyperhidrosis have been defined in 2004 (4). Secondary focal hyperhidrosis is excessive sweating in typical anatomic sites or well defined anatomic distributions link to definitive underlying conditions like social anxiety disorder, neurologic disorders, eccrine nevus, Frey syndrome, Harlequin syndrome, and some of the tumors (3,5). Secondary regional hyperhidrosis is characterized by anhidrosis in one area with compensatory hyperhidrosis in another area. It is most commonly iatrogenic and it is compensatory sweating following surgical treatment of primary focal hyperhidrosis. Secondary regional hyperhidrosis may also be related to stroke, spinal cord lesion, neoplasm, or peripheral neuropathies, syringomyelia and other central nervous system diseases (3). Secondary generalized hyperhidrosis is excessive sweating that is caused by a medical condition or medication (6). Various treatment modalities are available: topical, oral, and injectable drugs, tap water iontophoresis, and more or less invasive medical treatments (e.g., suction curettage, microwave thermolysis, laser therapy, endoscopic transthoracic sympathectomy) (1,5,6). Topical treatments are antiperspirants, especially aluminium salts; the assumed mechanism of action is the mechanical obstruction of the sweat gland ducts or after longer term therapy, atrophy of the secretory cells (7). Palmar hyperhidrosis is less responsive to aluminium chloride therapy than axillary hyperhidrosis. Glycopyrrolate is an anticholinergic agent that is used off-label systemically for the treatment of hyperhidrosis. Topical glycopyrrolate may also be effective for focal hyperhidrosis. A new generation of OTC antiperspirants includes aluminium zirconium trichlorohydrate and may be an option for non-axillary as well as axillary hyperhidrosis (7). Iontophoresis is the second line of treatment for palmo-plantar hyperhidrosis following topical treatment (8). For people with hyperhidrosis of the hands and/or feet, iontophoresis treatments has been shown to dramatically decrease sweating. Although its mechanism of action is still not entirely understood, iontophoresis has proved to provide reliable, effective treatment when practiced with appropriate technique, and timing (8). Botulinum toxin type A is a safe and effective method for treating focal hyperhidrosis, providing longer-lasting results than topical treatments without the necessity of invasive surgical procedures (1,9). The most commonly used medications for managing excessive sweating are anticholinergics. These include medicines such as propantheline, glycopyrrolate, oxybutynin, benztrapine, and others (10).

#### References

1. Rzyan B, Bechara FG, Feise K, Heckmann M, Rappich S, Wörle B. Update of the S1 guidelines on the definition and treatment of primary hyperhidrosis. *J Dtsch Dermatol Ges.* 2018 Jul;16(7):945-952.
2. Wade R, Jones-Diette J, Wright K, Layton AM, Woolacott N. Hyperhidrosis quality of life measures: review and patient perspective. *J Dermatolog Treat.* 2018 Sep 12:1-6.
3. Moraites E, Vaughn OA, Hill S. Incidence and prevalence of hyperhidrosis. *Dermatol Clin.* 2014





# 4<sup>th</sup> INDERCOS

## Dermatology and Cosmetology Congress with International Participants

27 - 30 MARCH, 2019  
HILTON ISTANBUL BOSPHORUS HOTEL  
ISTANBUL, TURKEY



Oct;32(4):457-65.

4.Hornberger J, Grimes K, Naumann M et al. Multi-Specialty Working Group on the Recognition, Diagnosis and Treatment of Primary Focal Hyperhidrosis. Recognition, diagnosis, and treatment of primary focal hyperhidrosis. *J Am Acad Dermatol* 2004;51:274-86.

5.Schlereth T, Dieterich M, Birklein F. Hyperhidrosis--causes and treatment of enhanced sweating.*Dtsch Arztebl Int.* 2009 Jan; 106(3): 32–37.

6. Sito G. *Hyperhidrosis Clinician's Guide to Diagnosis and Treatment.* Springer, 2016

7.Pariser DM, Ballard A.Topical therapies in hyperhidrosis care.*Dermatol Clin.* 2014 Oct;32(4):485-90.

8.Pariser DM, Ballard A. Iontophoresis for Palmar and Plantar Hyperhidrosis. *Dermatol Clin.* 2014 Oct;32(4):491-4

9.Doft MA, Hardy KL, Ascherman JA. Treatment of hyperhidrosis with botulinum toxin.*Aesthet Surg J.* 2012 Feb;32(2):238-44.

10.Hosp C, Hamm H. Safety of available and emerging drug therapies for hyperhidrosis. *Expert Opin Drug Saf.* 2017 Sep;16(9):1039-1049



# 4<sup>th</sup> INDERCOS

## Dermatology and Cosmetology Congress with International Participants

27 - 30 MARCH, 2019  
HILTON ISTANBUL BOSPHORUS HOTEL  
ISTANBUL, TURKEY



### GUSTATORY SKIN PROBLEMS

Pelin Kuteyla Can

The roles of dietary factors in aggravating, or causing skin diseases are common questions in dermatology practice. The role of dietary factors in dermatological disease is a frequent source of patient inquiry and physician's uncertainty (1). The most relevant gustatory skin problems are; gustatory sweating (Frey syndrome), food-dependent exercise-induced anaphylaxis (FDEIA), food allergy presented as atopic dermatitis or urticaria/angioedema, cholinergic urticaria, rosacea, acne and melanoma-nonmelanoma skin cancer. Gustatory sweating (Frey syndrome) is sweating and flushing that occurs on the forehead, scalp, neck, and upper lip while eating, talking, or thinking about food. Frey syndrome is mostly a postoperative phenomenon following salivary gland surgery, but it can also be associated with diabetes mellitus, herpes zoster and congenital malformations which is usually seen in infants (2). Exercise-induced anaphylaxis (EIA) is a rare disorder in which individuals develop immunoglobulin E (IgE)-mediated hypersensitivity in conjunction with exercise, causing anaphylaxis, and about 30% to 50% of EIA is food dependent, only occurring with the combination of a specific food and exercise (3). Shellfish, tomatoes and alcoholic drinks were the most frequent causes of the FDEIA (4). In food allergy, while immediate symptoms are urticaria, angioedema and sudden erythema (flush), delayed symptoms which can be observed are exanthema and exacerbation or worsening of eczema (most often atopic dermatitis) (5). Although the role of pseudoallergens is not universally accepted and controversial, pseudoallergens can induce or aggravate chronic urticaria in a subset of patients (1). Cholinergic urticaria may also be triggered by emotional and gustatory sweating due to the intake of spicy foods (6). Certain foods may act as triggers for rosacea. These may be divided into heat-related, alcohol-related, capsaicin-related, and cinnamaldehyde-related. In one survey over 400 patients, 78% had altered their diet due to rosacea and of this group, 95% reported reduction in flares (7). The current status of the relationship of diet and acne is not clear but two most commonly addressed ones are glycemic index/load and milk (8). Several studies have found a positive association between alcohol consumption and melanoma risk. Animal studies suggest that dietary fat intake significantly influences the occurrence of non-melanoma skin cancer (1).

### References

1. Murzaku EC, Bronsnick T, Rao K. Diet in dermatology: Part II. Melanoma, chronic urticaria, and psoriasis. *J Am Acad Dermatol.* 2014 Dec;71(6): 1053.e1-1053.e16
2. Humphrey J, Black G, Wild L. Facial flushing with food: the auriculotemporal syndrome. *J Gen Intern Med.* 2013 Mar;28(3):475-6
3. Barg W, Medrala W, Wolanczyk-Medrala A. Exercise-induced anaphylaxis: an update on diagnosis and treatment. *Curr Allergy Asthma Rep.* 2011 Feb; 11(1):45-51
4. Kounis NG, Kounis GN, Soufras GD. Exercise-induced urticaria, cholinergic urticaria, and Kounis syndrome. *J Pharmacol Pharmacother.* 2016 Jan-Mar;7(1):48-50.
5. Werfel T. Skin manifestations in food allergy. *Allergy.* 2001;56 Suppl 67:98-101
6. Torabi B, Ben-Shoshan M. The association of cholinergic and cold-induced urticaria: diagnosis and management. *BMJ Case Rep.* 2015 Feb 18; 2015.
7. Weiss E, Katta R. Diet and rosacea: the role of dietary change in the management of rosacea. *Dermatol Pract Concept.* 2017 Oct; 7(4): 31-37.
8. Bronsnick T, Murzaku EC, Rao BK. Diet in dermatology: Part I. Atopic dermatitis, acne, and nonmelanoma skin cancer. *J Am Acad Dermatol.* 2014 Dec;71(6):1039.e1-1039.e12.



# 4<sup>th</sup> INDERCOS

## Dermatology and Cosmetology Congress with International Participants

27 - 30 MARCH, 2019  
HILTON ISTANBUL BOSPHORUS HOTEL  
ISTANBUL, TURKEY



### SEXUAL ABUSE: HOW CAN WE KNOW?

#### Ozalp Ekinci

Sexual abuse is defined as any activity with a child, before the age of legal consent, that is for the sexual gratification of an adult or a significantly older child.

Sexual abuse includes:

- The contacts of oral-genital-rectal sites
- Vivid or virtual exposure of any sexual content including pornography
- Forced viewing of sexual anatomy of adults/forced hearing of sexual words
- Using a child in pornography.

Sexual mistreatment of children by family members is referred to as incest. Incest and sexual abuse by nonrelatives known to the victim are among the most common types.

The presenting complaints of sexual abuse may include nonspecific behavioral changes and psychiatric symptoms:

Unexplained anxiety symptoms: separation anxiety, phobias, night fears (in a child of older age)

Increased interest in sexuality: playing games with sexual content and themes

Regression to an older developmental level in the child: enuresis, encopresis

Loss of interest in games and peer activities

Loss of interest in school

decline in academic performance

Irritability, anger outbursts

depressed mood

Attention difficulties, hyperactivity

Changes in the toilet habits

Sleep disturbances such as nightmares- parasomnias

Somatic symptom such as abdominal pain, headache

Obsessive-compulsive behaviors: cleaning, controlling, sexual and religious obsessions

Psychotic symptoms such as pseudo-hallucinations: voices talking in the head

Sexual abuse may lead to **post traumatic stress disorder** if the abuse is

\*Severe/direct

\*Recurrent

\*Includes harm to body sites

\* Is by a close family member

Some of the diagnostic criteria of post traumatic stress disorder (PTSD) are as follows:

**The traumatic event is persistently re-experienced in the following way(s):**

\*Unwanted upsetting memories

\*Nightmares

\*Flashbacks

\*Emotional distress/physical reactivity after exposure to traumatic reminders

**Avoidance of trauma-related stimuli after the trauma, in the following way(s):**

\*Trauma-related thoughts or feelings

\*Trauma-related external reminders



# 4<sup>th</sup> INDERCOS

## Dermatology and Cosmetology Congress with International Participants

27 - 30 MARCH, 2019  
HILTON ISTANBUL BOSPHORUS HOTEL  
ISTANBUL, TURKEY



### **Negative thoughts or feelings that began or worsened after the trauma, in the following way(s):**

- \*Inability to recall key features of the trauma
- \*Overly negative thoughts and assumptions about oneself or the world
- \*Exaggerated blame of self or others for causing the trauma
- \*Negative affect
- \*Decreased interest in activities
- \*Feeling isolated

### **Trauma-related arousal and reactivity that began or worsened after the trauma, in the following way(s):**

- \*Irritability or aggression
- \*Risky or destructive behavior
- \*Heightened startle reaction
- \*Difficulty concentrating
- \*Difficulty sleeping

Criterion F: duration (required)

### **Dermatologic and medical findings of sexual abuse**

1. The presence of semen/sperm/acid phosphatase/foreign DNA in the anus or external genitalia
2. Positive evidence of Chlamydia trachomatis, gonorrhoea or syphilis in the absence of perinatal transmission
3. HIV infection not perinatally acquired or via transfusion of blood products
4. Clear evidence of penetrating anogenital trauma without accidental explanation, namely acute hymenal injury
5. Laceration/bruising, transection, absence of tissue in the posterior sector
6. Perianal lacerations or scarring extending deep to the external sphincter or beyond the anal margin
7. Oral cavity: Erythema/petechiae of the palate which are related with an organic condition may be evidence of forced oral sex.

### **Physical abuse**

For clinicians working with children who are victims of sexual abuse, there are some red flags in the history. In a significant proportion of cases, physical abuse accompanies sexual abuse so, the findings of physical abuse should also be recognized. Main findings of physical abuse are as follows:

#### **History**

1. Lack of a convincing explanation for an injury
2. History that changes with time
3. Obvious differences between the histories of caregivers and child
3. Unexplained delays in seeking medical care
4. History of repeated emergency room visits and/or repeated fractures and injuries
5. A history inconsistent with the physical findings

#### **Dermatologic findings**

May include bruises, lacerations, abrasions, burns, oral trauma, bite marks, and traumatic alopecia.

1. Accidental bruising most commonly occurs over the knees and anterior tibial area and may be seen over the forehead, hips, lower arms, and spine.
2. Bruising over **relatively protected body** sites such as the upper arms, upper and posterior thighs, hands, trunk, cheeks, ears, neck, genitalia, and buttocks should raise suspicion of abuse





# 4<sup>th</sup> INDERCOS

## Dermatology and Cosmetology Congress with International Participants

27 - 30 MARCH, 2019  
HILTON ISTANBUL BOSPHORUS HOTEL  
ISTANBUL, TURKEY



3. For the bruises which are **extensive, irregular and of varying age**, abuse should be suspected.
4. One of the red flags is **pattern bruising; linear bruises** are commonly produced by objects such as rods, switches, or wires.
5. **The shape of the bruises** also may be suggestive of an abuse. Bruises in the **shape of finger marks and bite marks** often seen on the upper arm, may be signs that the child was grabbed forcefully.
6. **Spanking the child on the buttocks** may result with characteristic vertical bruises along the gluteal cleft secondary to the shearing damage to the vessels along the convex curvature of the buttocks.



# 4<sup>th</sup> INDERCOS

## Dermatology and Cosmetology Congress with International Participants

27 - 30 MARCH, 2019  
HILTON ISTANBUL BOSPHORUS HOTEL  
ISTANBUL, TURKEY



### PAIN RELATED SKIN DISEASES

**Bachar Memet**

Skin pain is a common symptom of neuropathic pain, a pins-and-needles (prickling) sensation sometimes referred to as paresthesia, or of different types of burns to the skin.

Painful skin is the result of injury to or pressure on a nerve in the skin. Other causes include damage to nerves in the skin from exposure to extreme heat or cold or to toxic compounds. Neuropathic pain may be caused by peripheral neuropathy, a disorder in which the peripheral nerves that relay signals between the body, the brain, and the spinal cord lose function. Peripheral neuropathy can be due to a number of specific diseases and disorders, including alcoholism, diabetes, HIV infection, and Guillain-Barre syndrome, an autoimmune nerve disorder. Depending on the cause, skin pain may occur in a specific location on the skin or in a number of locations, and may be accompanied by redness, itching or swelling, or by other skin symptoms (1).

Burns, such as from the sun, heat, radiation and chemicals, are common causes of skin pain. Other injuries, such as bruises, lacerations or abrasions, commonly result in skin pain. Circulation problems that impair blood flow to the skin lead to painful skin (2).

Skin pain is a common symptom of neuropathic pain. It is often manifested as paresthesia, a sensation of prickling or tingling (pins and needles). Skin pain can also arise due to different types of burns to the skin. Paresthesia may be caused by peripheral neuropathy, a disorder in which the peripheral nerves that relay signals between the body, brain and spinal cord are functionally impaired (3). Skin pain may be caused by skin conditions including abrasion, abscess, blister, burn from severe cold or heat, chemical burn, cellulitis (infection of skin and underlying tissues), electrical burn, foreign body (splinter), laceration, psoriasis (before and after PUVA treatment), shingles, skin ulcers and sunburn (4). In some cases, skin pain may be a symptom of a serious or life-threatening condition that should be immediately evaluated in an emergency setting. These include cellulitis (infection of skin and underlying tissues), deep skin laceration that causes extensive damage and bleeding, and severe third-degree burn (destroys or damages the deep skin and tissue layers).

#### References

1. Ferri FF (Ed.) Ferri's Fast Facts in Dermatology. Philadelphia: Saunders Elsevier, 2011.
2. Burns. Medline Plus, a service of the National Library of Medicine National Institutes of Health. <http://www.nlm.nih.gov/medlineplus/burns.html>.
3. Argoff CE. Review of current guidelines on the care of postherpetic neuralgia. Postgrad Med 2011; 123:134.
4. Ljossa TM, Mork C, Stubhaug A, et al. Skin pain and skin discomfort is associated with quality of life in patients with psoriasis. J Eur Acad Dermatol Venereol. 2012; 26: 29-35.

**Keywords:** neuropathy, pain, psoriasis



# 4<sup>th</sup> INDERCOS

## Dermatology and Cosmetology Congress with International Participants

27 - 30 MARCH, 2019  
HILTON ISTANBUL BOSPHORUS HOTEL  
ISTANBUL, TURKEY



### CEPHALALGIA IN ALOPECIA

Bachar Memet

Cephalalgia alopecia is a rare and recently described headache syndrome in which recurrent, burning head and neck pain is associated with hair loss from areas of scalp affected by the pain (1,2). Interestingly, it has been reported that both the cephalalgia and the alopecia disappeared after injections of onabotulinumtoxin A. Besides, a case series of nummular headache (NH) with alopecia in the painful area has been published, in addition to the fact that some patients with NH may respond to onabotulinumtoxin A (3-6). Recently, a case of a woman with a syndrome of recurrent, burning, aching head pain with superimposed episodes of severe pain in areas of the temporal, parietal, and occipital scalp with associated alopecia was thoroughly studied by Cutrer and Pittelkow with the diagnosis of cephalalgia alopecia (1). The patient described by Cutrer and Pittelkow was unresponsive to multiple medication trials, and only treatment with local injections with onabotulinumtoxin A induced both remission of the pain and regrowth of the hair in the alopecia area. Biopsy specimens from untreated scalp areas showed lymphocytic infiltration around the hair bulb, as seen in alopecia areata. Immunochemical staining disclosed an altered pattern, with decreased density of nerve fibers in the epidermal neural plexus, including substance P (SP)-positive and calcitonin gene-related peptide (CGRP)-positive fibers. These alterations were reversible after onabotulinumtoxin A treatment, as seen in the evolutive biopsy from treated scalp areas. The authors suggested that the alopecia that follows neuralgiform pain could be due to loss of SP and CGRP release from depleted C-fiber terminals, and also supported by the fact that SP is an important regulator in alopecia areata (7).

1. Cutrer FM, Pittelkow MR. Cephalalgic alopecia areata: A syndrome of neuralgiform head pain and hair loss responsive to botulinum A toxin injection. *Cephalalgia*. 2006;26:747-751.
2. Cutrer FM, Sandroni P, Wendelschafer-Crabb G. Botulinum toxin treatment of cephalalgia alopecia increases substance P and calcitonin gene-related peptide-containing cutaneous nerves in scalp. *Cephalalgia*. 2010;30:1000-1006.
3. Pareja JA, Cuadrado ML, Fernández-de-las Peñas C, Nieto C, Sols M, Pinedo F. Nummular headache with trophic changes inside the painful area. *Cephalalgia*. 2008;28:186-190.
4. Porta-Etessam J, Lapeña T, Cuadrado ML, Guerrero A, Parejo B. Multifocal nummular headache with trophic changes. *Headache*. 2010;50:1612-1613.
5. Mathew NT, Kailasam J, Meadors L. Botulinum toxin type A for the treatment of nummular headache: Four case studies. *Headache*. 2008;48:442-447.
6. Ashkenazi A, Silberstein S. Is botulinum toxin useful in treating headache? Yes. *Curr Treat Options Neurol*. 2009;11:18-23.
7. Siebenhaar F, Sharov AA, Peters EM, et al. Substance P as an immunomodulatory neuropeptide in a mouse model for autoimmune hair loss (alopecia areata). *J Invest Dermatol*. 2007;127:1489-1497.

**Keywords:** alopecia, botulinum toxin, cephalalgia, headache



# 4<sup>th</sup> INDERCOS

## Dermatology and Cosmetology Congress with International Participants

27 - 30 MARCH, 2019  
HILTON ISTANBUL BOSPHORUS HOTEL  
ISTANBUL, TURKEY



### PARESTHESIA RELATED SKIN DISEASES

**Pelin Üstüner**

Nerve entrapment, metabolic, connective tissue or autoimmune disorders, vasculitis, drug use, neurological abnormalities, the central nervous system disorders, such as stroke and transient ischemic attacks (mini-strokes), multiple sclerosis, transverse myelitis, and encephalitis, infectious causes or nutritional deficiencies play a key role in the etiology of paresthesia (1). Herpes zoster is the most common etiological infectious cause of the paresthesia related dermatological diseases (2). During the pre-eruptive phase; sensory phenomena including pain or, less commonly, itching or paresthesia present along 1 or more skin dermatomes or persistent or recurring pain lasting 30 or more days after the acute infection named as “postherpetic neuralgia” may be seen (2). Secondly, Fabry disease a deficiency of  $\alpha$ -galactosidase A that presents with the accumulation of glycosphingolipids in central and peripheral nervous system shows an increased risk of strokes and mortalities. It is also accompanied by paresthesia, pain, reduced cold and heat-pain detection thresholds (3). In a patient presenting with a red circular skin rash (erythema marginatum), arthritis and flue like symptoms, Lyme disease should also be considered (4). In vitamin B1, B6, B12 deficiency patients may have a length-dependent sensorimotor axonal peripheral neuropathy; subacute combined degeneration within the spinal cord with loss of both corticospinal tracts and posterior columns with a concomitant axonal sensorimotor peripheral neuropathy (5). Besides, acute inflammatory demyelinating polyneuropathy, bilateral facial muscle paralysis, lowered muscle strength in extremities, absence of deep tendon reflexes, paresthesia on the distal limbs in a glove and stocking distribution may all be seen in systemic lupus erythematosus (6). Primary Sjögren syndrome may be present in 9 to 30% of the patients with small fiber neuropathy (7). On the contrary a pure small fiber neuropathy is diagnosed in only 3 to 9% of the patients with Sjögren syndrome (7). In a rare heterogeneous group of genetic disorder Charcot-Marie-Tooth disease, length dependent paresis; muscle atrophy with areflexia due to the chronic motor neuropathy are commonly seen. Loss of vibration and joint position sense followed by decreased pain and temperature sensation in stocking and glove distribution are typical (8). Leprosy is characterized with paresthesia on both hands and feet, livedo reticularis and complaints of frequent hand lesions (9). Distal symmetric sensitive polyneuropathy with axonal predominance, muscle paralysis (eg, lagophthalmos, foot drop, and claw hands), ulcers, and amputations are seen common (9). Moreover, in patients with HIV; peripheral sensory and motor nerves, thoracic nerve, cranial nerves or autonomic nerves are typically involved (10). The risk of palmoplantar erythrodysesthesia increases by the dosage of chemotherapy mostly doxorubicin, cytarabine, docetaxel, fluorouracil and prolonged exposure (11). Lastly, in notalgia paresthetica; a sensory neuropathic syndrome of a small localized patch on the midback skin, typically on the unilateral infrascapular area characterized with a localized episodic or continuous pruritus, pain or dysesthesia is typical (12). Somatization Disorder previously referred to as hysteria or Briquet’s syndrome also presents with scalp dysesthesias, vulvodynia, scrotodynia, atypical facial pain or orofacial dysesthesias and “burning mouth syndrome” without any objective physical finding (13).





# 4<sup>th</sup> INDERCOS

## Dermatology and Cosmetology Congress with International Participants

27 - 30 MARCH, 2019  
HILTON ISTANBUL BOSPHORUS HOTEL  
ISTANBUL, TURKEY



### REFERENCES

- Beran R. Paraesthesia and peripheral neuropathy. *Aust Fam Physician* 2015;44(3):92-5.
- Bennett GJ, Watson CP. Herpes zoster and postherpetic neuralgia: past, present and future. *Pain Res Manag* 2009;14(4):275-82.
- Schiffmann R, Moore DF. Neurological manifestations of Fabry disease. In: Mehta A, Beck M, Sunder-Plassmann G, editors. *Fabry Disease: Perspectives from 5 Years of FOS*. Oxford: Oxford PharmaGenesis; 2006. Chapter 22.
- Roaldsnes E, Eikeland R, Berild D. Lyme neuroborreliosis in cases of non-specific neurological symptoms. *Tidsskr Nor Laegeforen* 2017;137(2): 101-104.
- Staff NP, Windebank AJ. Peripheral neuropathy due to vitamin deficiency, toxins, and medications. *Continuum (Minneapolis)* 2014;20(5 Peripheral Nervous System Disorders):1293-306.
- Li X, Wang Y. Systemic Lupus Erythematosus With Acute Inflammatory Demyelinating Polyneuropathy: A Case Report and Review of the Literature. *J Clin Med Res* 2016 Jul;8(7):555-9.
- Pereira PR, Viala K, Maisonobe T, et al. Sjögren Sensory Neuronopathy (Sjögren Ganglionopathy): Long-Term Outcome and Treatment Response in a Series of 13 Cases. *Medicine (Baltimore)* 2016;95(19):e3632.
- Szigeti K1, Lupski JR. Charcot-Marie-Tooth disease. *Eur J Hum Genet* 2009;17(6):703-10.
- Wan EL, Rivadeneira AF1, Jouvin RM1, et al. Treatment of Peripheral Neuropathy in Leprosy: The Case for Nerve Decompression. *Plast Reconstr Surg Glob Open* 2016;4(3):e637.
- Schütz SG1, Robinson-Papp J. HIV-related neuropathy: current perspectives. *HIV AIDS (Auckl)* 2013;5:243-51.
- Hui YF1, Cortes JE. Palmar-plantar erythrodysesthesia syndrome associated with liposomal daunorubicin. *Pharmacotherapy* 2000;20(10):1221-3.
- Howard M, Sahhar L, Andrews F, et al. Notalgia paresthetica: a review for dermatologists. *Int J Dermatol* 2018;57(4):388-392.
- Gupta MA. Somatization disorders in dermatology. *Int Rev Psychiatry* 2006;18(1):41-7.



# 4<sup>th</sup> INDERCOS

## Dermatology and Cosmetology Congress with International Participants

27 - 30 MARCH, 2019  
HILTON ISTANBUL BOSPHORUS HOTEL  
ISTANBUL, TURKEY



### NEUROLOGICAL ITCH MANAGEMENT

Pelin Üstüner

The best approach to treatment of postherpetic itch has not been established. Symptoms may or may not respond to treatments for postherpetic neuralgia. Topical therapies can be useful for the treatment of brachioradial pruritus, however further study is necessary to clarify efficacy. Topical capsaicin 0.025% cream was associated with symptom improvement in 13 out of 15 patients in an open-label study (1) and in four out of seven patients in a small case series with brachioradial pruritus (2). Topical capsaicin has been used for also the management of notalgia paresthetica (3). In a randomized cross-over trial of 20 patients, more patients improved with topical capsaicin therapy than with vehicle (70 versus 30%) (4). However, symptoms returned after the cessation of therapy. In contrast, a randomized trial of 13 patients with methodological flaws showed no benefit of capsaicin 0.025% cream over a placebo cream (5). Topical 1% menthol may offer some relief (6). Topical corticosteroids are not effective. The efficacy of topical anesthetics for notalgia paresthetica has not been formally studied, but improvement has been reported in a few patients (7).

First-line options for oral therapy in patients who do not respond to local therapies include gabapentin (8) and pregabalin (9). Improvement with ketoprofen (8) or lamotrigine (10) has also been documented in case reports. Effects of fentanyl, oxymorphone, and tramadol on pruritus with or without wheal and flare response are histamine independent and involve mu-opioid receptors, while the effect of other opioids, such as morphine, codeine, and meperidine, involve both mu-opioid receptor and histamine-related mechanisms (11). Systemic administration of ketamine has been associated with multiple side effects (6). Oxcarbazepine, has also been reported to achieve varying amounts of improvement in four patients in a case series (12). Antihistamines and topical corticosteroids are ineffective. Agents that act through effects on the central nervous system are additional options for the treatment of pruritus. Modulators of opioid receptors, antidepressants, anticonvulsants, and aprepitant have been used successfully (4,13). The efficacy of agents used for neuropathic pruritus such as topical capsaicin, gabapentin, pregabalin, and tricyclic antidepressants are still unknown.

Botulinum toxin A with vertebral nerve block, transcutaneous electrical nerve stimulation physiotherapy, surgical intervention such as cervical spine manipulation have also been reported in some cases (14-16).

### REFERENCES

- 1) Steinke S, Gutknecht M, Zeidler C, et al. Cost-effectiveness of an 8% Capsaicin Patch in the Treatment of Brachioradial Pruritus and Notalgia Paraesthetica, Two Forms of Neuropathic Pruritus. *Acta Derm Venereol* 2017;97(1):71-76.
- 2) Zeidler C, Lüling H, Dieckhöfer A, et al. Capsaicin 8% cutaneous patch: a promising treatment for brachioradial pruritus? *Br J Dermatol* 2015;172(6):1669-71.
- 3) Pereira MP, Lüling H, Dieckhöfer A, et al. Brachioradial Pruritus and Notalgia Paresthetica: A Comparative Observational Study of Clinical Presentation and Morphological Pathologies. *Acta Derm Venereol* 2018;98(1):82-88.
- 4) Wallengren J, Klinker M. Successful treatment of notalgia paresthetica with topical capsaicin: vehicle-controlled, double-blind, crossover study. *J Am Acad Dermatol* 1995;32(2 Pt 1):287-9.



# 4<sup>th</sup> INDERCOS

## Dermatology and Cosmetology Congress with International Participants

27 - 30 MARCH, 2019  
HILTON ISTANBUL BOSPHORUS HOTEL  
ISTANBUL, TURKEY



- 5) Andersen HH, Sand C, Elberling J. Considerable Variability in the Efficacy of 8% Capsaicin Topical Patches in the Treatment of Chronic Pruritus in 3 Patients with Notalgia Paresthetica. *Ann Dermatol* 2016;28(1):86-9.
- 6) Lee HG, Grossman SK, Valdes-Rodriguez R, et al. Topical ketamine-amitriptyline-lidocaine for chronic pruritus: A retrospective study assessing efficacy and tolerability. *J Am Acad Dermatol* 2017;76(4):760-761.
- 7) da Cruz CM, Antunes F. Physical Medicine and Rehabilitation Role on Notalgia Paresthetica: Case Report and Treatment Review. *Am J Phys Med Rehabil* 2018;97(12):929-932.
- 8) Matsuda KM, Sharma D, Schonfeld AR, et al. Gabapentin and pregabalin for the treatment of chronic pruritus. *J Am Acad Dermatol* 2016;75(3):619-625.e6.
- 9) Foroutan N, Nikvarz N. Role of Pregabalin in Management of Pruritus: A Literature Review. *J Pharm Pharm Sci* 2016;19(4):465-474.
- 10) Gupta MA, Pur DR, Vujcic B, et al. Use of antiepileptic mood stabilizers in dermatology. *Clin Dermatol* 2018;36(6):756-764.
- 11) Gavril W. Pasternak, Ying-Xian Pan. Mu Opioids and Their Receptors: Evolution of a Concept. *Pharmacol Rev* 2013; 65(4): 1257–1317.
- 12) Savk E, Bolukbasi O, Akyol A, et al. Open pilot study on oxcarbazepine for the treatment of notalgia paresthetica. *J Am Acad Dermatol* 2001;45(4):630-2.
- 13) Foroutan N, Nikvarz N. Role of Pregabalin in Management of Pruritus: A Literature Review. *J Pharm Pharm Sci* 2016;19(4):465-474.
- 14) Maari C, Marchessault P, Bissonnette R. Treatment of notalgia paresthetica with botulinum toxin A: a double-blind randomized controlled trial. *J Am Acad Dermatol* 2014;70(6):1139-41.
- 15) Mohammad Ali BM, Hegab DS, El Saadany HM. Use of transcutaneous electrical nerve stimulation for chronic pruritus. *Dermatol Ther* 2015;28(4):210-5.
- 16) Tait CP, Grigg E, Quirk CJ. Brachioradial pruritus and cervical spine manipulation. *Australas J Dermatol* 1998;39(3):168-70.



# 4<sup>th</sup> INDERCOS

## Dermatology and Cosmetology Congress with International Participants

27 - 30 MARCH, 2019  
HILTON ISTANBUL BOSPHORUS HOTEL  
ISTANBUL, TURKEY



### SEROTONIN ANTAGONISTS, ANTI-CGRP MONOCLONAL ANTIBODIES, CANNABOID AGONIST, OPIATE ANTAGONISTS, A – ADRENERGIC AGONIST AND SKIN

Nagihan Sahillioğlu

**Selective serotonin reuptake inhibitors (SSRI)** enhance serotonin activity by preferentially blocking 5-HT reuptake. The commonly used SSRIs are fluoxetine, paroxetine, sertraline, citalopram, escitalopram, and fluvoxamine. They were used successfully in pathologic skin picking, neurotic excoriations, chronic pruritus, trichotillomania and body dysmorphic disorder. SSRIs require a minimum trial of 4 to 6 weeks for maximum therapeutic benefits. The medication is continued for several months, because rapid discontinuation will increase the risk of relapse<sup>1,2</sup>. **Calcitonin gene-related peptide (CGRP)** has been viewed as a neuropeptide and vasodilator. However, CGRP is more appropriately thought of as a pleiotropic signalling molecule. Indeed, CGRP has key regulatory functions on immune and inflammatory processes within the skin. CGRP-containing nerves are intimately associated with epidermal Langerhans cells (LCs), and CGRP has profound regulatory effects on Langerhans cell antigen-presenting capability. Exciting new studies suggest a significant role for CGRP in the pathogenesis of psoriasis and, most strikingly, that CGRP inhibits the ability of LCs to transmit the human immunodeficiency virus 1 to T lymphocytes. A more complete understanding of the role of CGRP in the skin immune system may lead to new and novel approaches for the therapy of immune-mediated skin disorders<sup>3</sup>. Although preliminary models with **topical cannabinoids** have shown potential, large-scale clinical trials in humans have yet to be performed. Despite this lack of investigation, commercial formulations of topical cannabinoids are available to dermatology patients. These formulations are nonstandardized, and no safety data exists regarding their use. Topical cannabinoids on the market may contain various amounts of active ingredient and may be combined with a range of other compounds. Based on the results from recent animal models, cannabinoids may have a role in future treatment algorithms for several inflammatory conditions. However, current efficacy and safety data are almost entirely limited to preliminary animal studies in rodents. In addition, the formulation of topical cannabinoid products is nonstandardized and poorly regulated. As such, the present evidence does not support the use of topical cannabinoids in dermatology practices<sup>4</sup>. **Opioids** are intimately linked to central pain inhibition and their abuse potential. Thus, peripheral opioid receptors in the skin have been studied initially with a focus on their peripheral analgesic properties. Recent results, however, clearly indicate that opioids play a specific role in skin homeostasis by modulating keratinocyte differentiation, wound healing, and inflammatory responses<sup>5</sup>. **Topical alpha-agonists** serve an important role in the management of rosacea as the only medical therapies shown to be effective in reducing the persistent facial erythema caused by fixed dilatation of superficial skin vasculature. Both brimonidine 0.33% gel and oxymetazoline 1% cream have received FDA approval for once-daily topical therapy of persistent (non-transient) facial erythema of rosacea, with both agents demonstrating efficacy and safety in clinical studies. There are differences between these two agents in alpha-receptor binding properties, which may potentially relate to variations in clinical response and possibly adverse events. It is clear that further research is needed to advance our understanding of these novel therapeutic agents<sup>6</sup>.





# 4<sup>th</sup> INDERCOS

## Dermatology and Cosmetology Congress with International Participants

27 - 30 MARCH, 2019  
HILTON ISTANBUL BOSPHORUS HOTEL  
ISTANBUL, TURKEY



### REFERENCES

1. Gupta, M. A. & Gupta, A. K. The use of antidepressant drugs in dermatology. *J. Eur. Acad. Dermatology Venereol.* **15**, 512–515 (2001)
2. Park, K. K. H. & Koo, J. Use of psychotropic drugs in dermatology: Unique perspectives of a dermatologist and a psychiatrist. *Clin. Dermatol.* **31**, 92–100 (2013).
3. Granstein, R. D., Wagner, J. A., Stohl, L. L. & Ding, W. Calcitonin gene-related peptide: Key regulator of cutaneous immunity. *Acta Physiol.* **213**, 586–594 (2015).
4. Hashim, P., Cohen, J., Pompei, D. & Goldenberg, G. Topical Cannabinoids in Dermatology. *Cutis* **100**, (2017).
5. Schmelz, M. & Paus, R. Opioids and the skin: 'Itchy' perspectives beyond analgesia and abuse. *J. Invest. Dermatol.* **127**, 1287–1289 (2007).
6. Del Rosso, J. Q. In focus: Topical  $\alpha$ -Agonist therapy for persistent facial erythema of rosacea and the addition of oxmetazoline to the treatment armamentarium: Where are we now? *J. Clin. Aesthet. Dermatol.* **10**, 28–32 (2017).



# 4<sup>th</sup> INDERCOS

## Dermatology and Cosmetology Congress with International Participants

27 - 30 MARCH, 2019  
HILTON ISTANBUL BOSPHORUS HOTEL  
ISTANBUL, TURKEY



### NATURAL SUNLIGHT THERAPY IN DERMATOLOGY

Kenan Aydođan

More than 3500 years ago, ancient Egyptian and Indian healers used the ingestion of plant extracts or seeds in addition to sunlight for treating "leucoderma. For millennia, sunlight or "heliotherapy(HT)" has been used in the treatment of various skin diseases such as psoriasis and atopic dermatitis. One prominent example known in ancient times, heliothalassotherapy, combined the effects of direct immersion in salt water, inhalation of salt water aerosols, as well as UV and thermal radiation from the sun. Other forms of climate therapy exclusively use solar radiation as heliotherapy or a combination of saltwater baths and sunlight as heliothalassotherapy. Spas offering climate therapy at the North, Baltic, and Dead Sea as well as in the Alps treat a broad range of skin diseases such as atopic dermatitis, psoriasis, prurigo and various forms of pruritus, parapsoriasis, and mycosis fungoides. HT also called climatotherapy, defined as a treatment combining the natural elements of a specific geographic location, has been used at the Dead Sea in Israel for over twenty years. Because of its unique position, the treatment at the Dead Sea mainly consists of the patients being exposed to a UV spectrum of long-wave ultraviolet light found naturally in high intensity only in that area of the world and, in addition, a sea rich in natural minerals and salts. The treatment is believed to be cost-effective and pleasant. The modern discoveries (eg, ultraviolet radiation) and modern inventions (eg, the electric generator or the electric lightbulb), as well as balneologic experiences of the treatment with sunlight, contributed to the transition from HT to artificial light phototherapy at the end of the 19th century.

In presence of UVA, psoralen intercalates between the DNA base pairs forming functional adducts, free radicals and reactive oxygen species thus causing cross linking of DNA strands, protein conjugation and cytotoxic effects. Psoralens can be applied either topically (topical PUVA) or orally (Oral PUVA) followed by exposure to UVA light. Depending upon source of UVA, the therapy can be given as PUVA (artificial phototherapy unit as the source of UVA) or PUVAsol (solar irradiation as the source of UVA). PUVAsol can be used in sunnier climates, according to the same principles as PUVA. PUVAsol therapy is especially useful for patients, who cannot refer to hospital for the conventional treatment. It consists of psoralen (8-MOP) intake and sunlight exposure, which can be easily performed at patients' home. On the other hand, the lack of a medical control during the therapeutic sessions, makes PUVAsol therapy less safe. Severe reaction, such as erythema, pigmentation, blistering, burning and ocular side effects, are well-described. Topical psoralen containing preparations (such as 5-MOP) are less phototoxic and more convenient as compared to oral psoralen. Soak/ paint and bath PUVAsol are the various modalities of topical PUVAsol therapy. PUVAsol can be combined with topical drugs (Calcipotriol, corticosteroids, tar or dithranol in resistant psoriasis or/and vitiligo cases) and systemic drugs (Methotrexate in resistant psoriasis cases). In this present, I will review indications of Dead sea climatotherapy and PUVAsol therapy

#### References

- J. Koo, M. Nakamura, Heliotherapy. In Clinical Cases in Phototherapy, Springer International Publishing AG 2017;77-80
- Hönigsmann H. History of phototherapy in dermatology. Photochem. Photobiol. Sci., 2013; 12:16–21
- Grzybowski A, Sak J, Pawlikowski J. A brief report on the history of phototherapy. Clin in Dermatol 2016; 34: 532–537



# 4<sup>th</sup> INDERCOS

## Dermatology and Cosmetology Congress with International Participants

27 - 30 MARCH, 2019  
HILTON ISTANBUL BOSPHORUS HOTEL  
ISTANBUL, TURKEY



### HORMON REPLACEMENT THERAPY IN THERAPY OF AGING SKIN

Ivana Binic

The skin, the largest organ of the body, is the organ in which changes associated with aging are most visible. The skin is a target organ for various hormones, and sex steroids have a profound influence on the aging process. At present, most women in developed societies can expect to spend one-third or more of their lifetime in the postmenopausal period. Skin ageing, therefore, becomes increasingly important; it is still a matter of debate, however, whether hormone replacement therapy (HRT) also improves the various symptoms of skin ageing in postmenopausal women.

Among the various other factors that affect skin aging, such as genetic predisposition, ultraviolet light and metabolic processes, the effect of hormones is also of great importance. The skin is the target organ for various hormones. Sex hormones have a great influence on the development and composition of the skin, and their level in the body needs to be appropriate to maintain its structural integrity and functional capacity. The effect of the hormones depends on their binding to specific receptors, which have been discovered, among others, in keratinocytes, Langerhans cells, melanocytes, fibroblasts, sebaceous glands, hair follicles, endocrine glands, and blood vessels. The density of the receptor varies depending on the region, with higher concentration of these receptors on the face, than for example in the pelvic region or breast.

A few months after menopause, a large number of women notice the sudden symptoms of aging of the skin in the form of its drying and / or loss of firmness and elasticity. These symptoms relate to changes in collagen and elastic fibers that are associated with an estrogen deficiency. The most important for aging are collagen type I and III, and aging reduces both the total collagen content in the skin, as well as the ratio of collagen I and III. It is considered that the annual content of collagen is reduced by 1% in adults, and that this process is more pronounced in women. In postmenopausal woman, about 30% of total collagen is lost in the first five years. Hypoestrogenemia is also responsible for alterations in the concentration of glycosaminoglycans, and consequently for the content of water in the skin.

Numerous studies have demonstrated the positive effect of systemic hormone replacement therapy on the skin aging process, but it should be noted that this therapeutic option should not be prescribed if the target would only have the prevention and fight against skin aging. But, as an additional benefit in the treatment of other menopausal disorders, with an experienced dermatologist with knowledge of endocrinology, this type of therapy can be a good instrument in controlling the so-called, internal skin aging. Topical administration of hormones using creams may be a good alternative to systemic hormonal substitution, but it is important that this type of therapy is administered by a dermatologist with endocrinology experience, in order to avoid systemic effects. Phytoestrogens, also given systemically and / or locally, can be a good choice in the fight against skin aging.



# 4<sup>th</sup> INDERCOS

**Dermatology and Cosmetology Congress  
with International Participants**

27 - 30 MARCH, 2019  
HILTON ISTANBUL BOSPHORUS HOTEL  
ISTANBUL, TURKEY



## **DERMOSCOPY: WHAT'S NEW?**

**Mustafa Turhan Şahin**

Dermoscopy has been described as a useful tool for the early diagnosis of melanoma and the differential diagnosis of pigmented lesions of the skin. This has been proven by some independent meta analyses of the literature. Dermoscopy is a fast evolving field with a high number of new publications every year. Initially, the use of dermoscopy was limited to pigmented lesions, but it is used more and more in other situations. It has become an important tool for the diagnosis of nail pigmentations, hair and scalp disorders, inflammatory skin diseases, and so forth. This presentation aims to provide an update on recent trends and developments in dermoscopy.





# 4<sup>th</sup> INDERCOS

## Dermatology and Cosmetology Congress with International Participants

27 - 30 MARCH, 2019  
HILTON ISTANBUL BOSPHORUS HOTEL  
ISTANBUL, TURKEY



### DNA METHYLATION IN DERMATOLOGY

**Aslı Tatlıparmak**

DNA methylation is the covalent binding of a methyl group to a DNA nucleotide. Methylation of the 5-carbon position of the cytosine in a cytosine-guanine dinucleotide (CpG) plays important roles in mammalian biological function. When a CpG island (CGI) containing a high density of CpG sites on genomic DNA is highly methylated in the 5' region of a gene, the transcription of that gene is suppressed. In contrast, DNA methylation in the gene body can promote gene transcription. The CpG dinucleotides tend to cluster in regions called CpG islands, defined as regions of more than 200 bases with a G + C content of at least 50% and a ratio of observed to statistically expected CpG frequencies of at least 60%. Approximately 60% of gene promoters are associated with CpG islands and are normally unmethylated, although some of them (approximately 6%) become methylated in a tissue-specific manner during early development or in differentiated tissues. This finding may explain why all cells in an organism share the same genetic information, but they show different phenotypes. In general, CpG island methylation is associated with gene silencing.

DNA methylation serves as a mark that indicates repression of gene expression; therefore, it is involved in several biological processes, such as cell differentiation and proliferation. Aberrant DNA methylation frequently occurs in malignant tumors but scarcely occurs in benign tumors.

In recent years, several studies have demonstrated that disruption of epigenetic mechanisms can alter immune function, and aberrant DNA methylation may contribute to the development of autoimmune-related skin diseases such as lupus, psoriasis, atopic dermatitis, and vitiligo. The precise mechanisms and clinical applications of DNA methylation in skin diseases, however, require further exploration.



# 4<sup>th</sup> INDERCOS

## Dermatology and Cosmetology Congress with International Participants

27 - 30 MARCH, 2019  
HILTON ISTANBUL BOSPHORUS HOTEL  
ISTANBUL, TURKEY



### ION CHANNELS IN DERMATOLOGY

Özgür Gündüz

The term ion refers to an atom or molecule that has a non-zero net electrical charge. Conventionally, the negative charge of an electron is considered equal to the positive charge of a proton, so the net charge of an ion depends of the number of its electrons. A positively charged ions have fewer electrons than protons and are described as cations, while negatively charged ions posses more electrons than protons and named as anions.

Ions, ionic compounds participate in many cellular activities, during which they have to relocate between intra-and extracellular compartments. Although nonpolar hydrophobic molecules can easily diffuse between intracellular and extracellular compartments; the ion migration is hindered by the same cellular membrane. Transport of ionic compunds across the cell membrane is under strict control and only enabled by the special cell membrane-itegrated proteins. These cell membrane transporters are grouped in two major classes:

**1. Carrier proteins:** These group proteins bind to specific molecules including ionic compounds and transfer them across the membrane down or against their electrochemical gradient

**2. Ion channels:** These proteins form pores in the plasma membrane and, allow the ions, typically inorganic ions such as sodium ( $\text{Na}^+$ ), potassium ( $\text{K}^+$ ), calcium ( $\text{Ca}^{2+}$ ), and chloride ( $\text{Cl}^-$ ), down their electrochemical gradients. These ion channels have a enormous influx capacity and through a single ion channel, up to 100 million ions can be transported across the cell membrane per second. <sup>1</sup>

Transport via ion channels is under strict control. Many factors, such as posttranslational modification, membrane potential, extracellular ligands etc. influence and modulate the ion flux.

Ion channels are found in the membranes of all excitable cells and their activation may result in shaping action potentials, reestablishing resting membrane potential and other voltage-dependent cellular activities.

In recent years, the ion channels have been a popular research focus in dermatology. Presence of various types of ion channels have been demonstrated in skin. For example, transient receptor potential (TRP) ion channels, which are previously known to be expressed on sensory neurons, are also found in many non-neuronal cells and tissues, including skin. Almost all subtypes of TRP channels - TRPC1, TRPC3, TRPC4, TRPC5, and TRPC6 – are expressed by human keratinocytes.<sup>2</sup> TRPM (subgroup of TRPC) have been shown to be expressed on melanocytes<sup>4</sup> and various other TRPC subgroups on other cutaneous cells, such as Langerhans cells, sebocytes.<sup>4</sup> Recent researchs point out the possible role of TRPs in various dermatological diseases. TRPV2 and TRPV4 have been shown to be upregulated in rosacea affected skin<sup>5</sup>.

Expression of another ion channel, the Orai-STIM (stromal interaction molecule) channels, on melanoma cells have also been demonstrated.<sup>6</sup>

Further research may provide the dermatologists in the near future with new therapeutic options for various hard-to-cure skin diseases in the shape of ion channel-targeting drugs.



# 4<sup>th</sup> INDERCOS

## Dermatology and Cosmetology Congress with International Participants

27 - 30 MARCH, 2019  
HILTON ISTANBUL BOSPHORUS HOTEL  
ISTANBUL, TURKEY



- Petkov, G. (2009). Ion Channels. In Pharmacology (pp. 387-427). Elsevier Inc.. <https://doi.org/10.1016/B978-0-12-369521-5.00016-6>
- Tóth BI, Oláh A, Szöllösi AG, Bíró T. TRP channels in the skin. *Br J Pharmacol*. 2014 May;171(10):2568-81. doi: 10.1111/bph.12569.
- Guo H, Carlson JA, Slominski A. Role of TRPM in melanocytes and melanoma. *Exp Dermatol*. 2012;21(9):650-4.
- Cheng X, Jin J, Hu L, et al. TRP channel regulates EGFR signaling in hair morphogenesis and skin barrier formation. *Cell*. 2010;141(2):331-43.
- Sulk M, Seeliger S, Aubert J, et al. Distribution and expression of non-neuronal transient receptor potential (TRPV) ion channels in rosacea. *J Invest Dermatol*. 2011;132(4):1253-62.
- Stanisz H, Vultur A, Herlyn M, Roesch A, Bogeski I. The role of Orai-STIM calcium channels in melanocytes and melanoma. *J Physiol*. 2016;594(11):2825-35.



# 4<sup>th</sup> INDERCOS

## Dermatology and Cosmetology Congress with International Participants

27 - 30 MARCH, 2019  
HILTON ISTANBUL BOSPHORUS HOTEL  
ISTANBUL, TURKEY



### NANOTECHNOLOGY IN DERMATOLOGY

Özgür Gündüz

A nanometre is the billionth of a metre and is used in the study of the atomic and subatomic particles. Nanotechnology is a field of research and innovation concerned with creating and processing things on atomic scale. A branch of nanotechnology, Nanobiotechnology is focused on the cellular biology and development of new biomolecules and instruments, which are capable on operating in living organisms on subatomic levels.

Particularly in the last decade, medical applications of nanotechnology has become very popular. Various nanoparticles with the aim of medical use have been developed and many pharmaceuticals containing nanoparticles can be found in the market.

A nanoparticle is a microscopic particle with at least a dimension less than 100 nm. Nanoparticles can be divided into organic (lipids, proteins, etc) and inorganic (e.g., gold, silver ) substances. Nowadays, particularly the organic nanoparticles are prominently used as delivery systems for bioactive molecules in dermatology. Due to the a very formidable outer barrier formed by healthy – intact-epidermis, molecules larger than 200-300 Dalton can not permeate thoroughly.<sup>1</sup> Using nanoparticles, this skin barrier can be bypassed more easily to transport the bioactive molecules into the blood stream. Another dermatological focus on nanobiotechnology research is active substance liberation systems for topical administration. The aim of these systems is to transport and keep the active ingredients in epidermis. Liposomes, cyclodextrins etc. are some of the well- known nanocarrier systems. According to their dimensions, nanoparticles can diffuse around corneocytes, use a more direct route and pass through epidermal cells or penetrate through hair follicles and/or sudiparous glands.

As of today, dermatological use of nanotechnology can be grouped as follows, nanoparticles in photoprotective products (reported to cause less skin whitening than the traditional ones),<sup>2</sup> nanomaterials in products, nanoparticles used as delivery systems for antiseptic and antiinflammatory molecules (reported to cause less skin atrophy).<sup>3</sup> Phototherapy, skin cancers, especially melanoma, scalp diseases are other dermatological diseases of interest for researchers of nanotechnology. Nanotechnology continues to attract the interest of researchers. In the near future, dermatological drug arsenal will consist of more and more therapeutical agents with nanoparticles as delivery systems.

Antonio RA, Antonio CR, Cardeal ILS, Ballavenuto JMA, Oliviera JR. Nanoparticles in Dermatology. An Bras Dermatol 2014;89(1):126-36.

Wang SQ, Tooley IR. Photoprotection in the era of nanotechnology. Semin Cutan Med Surg. 2011;30:210-3.  
Santos Maia C, Mehnert W, Schaller M, Korting HC, Gysler A, Haberland A, et al. Drug targeting by solid lipid nanoparticles for dermal use. J Drug Target. 2002;10:489-95





# 4<sup>th</sup> Indercos

## Dermatology and Cosmetology Congress with International Participants

27 - 30 MARCH, 2019  
HILTON ISTANBUL BOSPHORUS HOTEL  
ISTANBUL, TURKEY



### IMMUNOSENESCENCE IN AGEING

H. Bing Thio

A well-established feature of physiological ageing is altered immune function, a phenomenon termed immunosenescence. This ageing-related decline affects both the innate and adaptive immune system and is associated with diminished abilities to induce protective immunity, diminished vaccine efficacy, increased incidence of cancer, inflammation and autoimmunity, and the impaired ability to generate tolerance to harmless antigens. There is an accumulating body of evidence that a decline in immune function with age is common to most if not all vertebrates. Age-associated thymic involution seems to occur in all species that possess a thymus. The ageing phenotype, including immunosenescence, is the result of an imbalance between inflammatory and anti-inflammatory mechanisms with the consequence of a state defined as inflammaging. The innate immune system is described as being "dysregulated", with the older people having increased levels of proinflammatory cytokines, resulting in persistent sub- inflammation. The gradual weakening of the immune system begins around the age of 60 and gradually deteriorates with age. However, the exact order and precise cellular changes that occur between individuals can be diverse, due to differences in environmental exposures and genetic composition. One important potential mechanism underlying immunosenescence includes epigenetic changes such as changes in DNA methylation (DNAm) and DNA hydroxymethylation that occur with age. Ageing is associated with numerous changes in immune cell subsets, antigen-specific cells and cytokines, consistent with an increasing acquisition of a Th2-cell bias. There is a trend towards a lower Th1 : Th2 ratio. Cell subset analysis consistently demonstrated an increase in Th2 cells in both sexes with age. Among all subjects there was also an increase with age in NK cells. Decreases in the total number of T cells and naive T cells in males and females in addition to decreases in T helper cells and cytotoxic T cells in males. This ageing- associated cellular Th2 bias explains why an autoimmune disease as bullous pemphigoid and pruritus senilis predominantly occur in elderly people. So, remodelling of the immune system with age in humans is characterized by a kind of immunodeficiency, low-grade chronic systemic inflammation and increased risk of autoimmunity.

#### References

Sadighi Akha AA. Ageing and the immune system: An overview. *J Immunol Methods*. 2018 Dec;463:21-26.  
Di Lorenzo G, Di Bona D, Belluzzo F, Macchia L. Immunological and non-immunological mechanisms of allergic diseases in the elderly: biological and clinical characteristics. *Immun Ageing*. 2017 Dec 20;14:23.



# 4<sup>th</sup> INDERCOS

## Dermatology and Cosmetology Congress with International Participants

27 - 30 MARCH, 2019  
HILTON ISTANBUL BOSPHORUS HOTEL  
ISTANBUL, TURKEY



### ACETYLCHOLINE RELATED SKIN DISEASE

**Erdoğan Terzi**

Acetylcholine (ACh) is regarded as a classical neurotransmitter well known for acting in the central and peripheral nervous system, and to be present in both prokaryotes and eukaryotes. However, in recent years, there have been extensive evidence demonstrating a nonneuronal cholinergic system, in which ACh and/or its synthesizing enzyme, choline acetyltransferase (ChAT), have been found to be present in non-neuronal human cells, such as keratinocytes, epithelial and endothelial cells, tendons, and various cells of the immune system. ACh has been shown to have widespread physiological effects such as cytoskeleton reorganization, cellular proliferation, differentiation, and apoptosis. Most cell types not innervated by cholinergic neurons still express two types of ACh receptors: nicotinic (nAChRs), which are ion channels, or G protein-coupled muscarinic receptors (mAChRs). Activation of these receptors has been linked to activation of mitogen-activated protein kinase (MAPK)-dependent pathways, in which phosphorylation of Erk1/2 leads to DNA synthesis and cell proliferation. ACh is also main neurotransmitter of eccrine sweat glands. ACh is related to some skin disorders such as hyperhidrosis, cholinergic urticaria. ACh related skin disorders are mentioned and discussed.

#### References

1. Hasmonai M, Cameron AEP, Connery CP, Perin N, Licht PB. The etiology of primary hyperhidrosis: a systematic review. *Clin Auton Res* 2017;27:379-83.
2. Rosen R, Steward T. Results of a 10-year follow-up study of botulinum toxin A therapy for primary axillary hyperhidrosis in Australia. *Intern Med J* 2018;48:343-7.
3. Altrichter S, Wosny K, Maurer M. Successful treatment of cholinergic urticaria with methantheliniumbromide. *J Dermatol* 2015;42:422-4.



# 4<sup>th</sup> INDERCOS

## Dermatology and Cosmetology Congress with International Participants

27 - 30 MARCH, 2019  
HILTON ISTANBUL BOSPHORUS HOTEL  
ISTANBUL, TURKEY



### ADRENALINE- NORADRENALINE RELATED SKIN DISEASE

**Erdoğan Terzi**

Noradrenaline and adrenaline are catecholamines that play major roles in regulation of the 'inner world' of the body by the brain. Noradrenaline (synonymous with norepinephrine), the main neurotransmitter of the sympathetic nervous system, is responsible for tonic and reflexive changes in cardiovascular tone. Adrenaline is a key determinant of responses to metabolic or global challenges to homeostasis, such as glucoprivation, and of manifestations of emotional distress. In contrast with the view that the sympathetic nervous and adrenomedullary hormonal systems function as a unit (the 'sympathoadrenal system') to maintain homeostasis in emergencies, across a variety of situations adrenaline responses are more closely linked to responses of the hypothalamic-pituitary-adrenocortical system than of the sympathetic nervous system. The sympathetic noradrenergic system is active even when the individual is at rest and maintains tonic levels of cardiovascular performance. Adrenoceptors in the membranes of effector cells determine the physiological and metabolic effects of catecholamines. Adrenaline- noradrenaline related skin disease are very rare such as adrenergic urticaria, nevus anemicus<sup>1,2</sup>. Adrenaline-noradrenalin also related to stress induced skin disease including psoriasis, urticaria, vitiligo, atopic dermatitis<sup>3</sup>. In this presentation, adrenaline-noradrenaline related skin diseases are mentioned and discussed.

#### References

1. Hogan SR, Mandrell J, Eilers D. Adrenergic urticaria: review of the literature and proposed mechanism. *J Am Acad Dermatol* 2014;70:763-6.
2. Kawakami Y, Gokita M, Fukunaga A, Nishigori C. Refractory case of adrenergic urticaria successfully treated with clonazepam. *J of Dermatol* 2015;42:635-7.
3. Alexopoulos A, Chrousos GP. Stress-related skin disorders. *Rev Endocr Metab Disord* 2016;17: 295-303.



# 4<sup>th</sup> Indercos

## Dermatology and Cosmetology Congress with International Participants

27 - 30 MARCH, 2019  
HILTON ISTANBUL BOSPHORUS HOTEL  
ISTANBUL, TURKEY



### DOPING RELATED SKIN DISEASES

Gül Yıldırım

Doping in sport is a widespread problem not just among elite athletes, but even more so in recreational sports. Athletes use prohibited drugs or methods for improving their performance and sporting results. In earliest Olympic Games cocaine, heroin and morphine were used to get better race results. Today anabolic agents, steroids, hormones, diuretics, narcotics, cannabinoids are used for doping purposes. In scientific literature major emphasis is placed on doping detection. Detrimental effects of doping agents on athletes health are seldom discussed. Here we will have a look side effects of doping agents on skin.

#### References:

1. Intern Med J 2015 Mar; 45(3): 239-48.
2. Sports Med 2004; 34: 513-54.
3. Br J Sports Med 1997;31: 54-58.
4. N Engl J Med 351; 9, 2004.
5. Acta Dermatoven APA Vol 16, 2007 No:3
6. Clin Exp Dermatol. 2006 Jan; 31(1): 134-6.





# 4<sup>th</sup> INDERCOS

## Dermatology and Cosmetology Congress with International Participants

27 - 30 MARCH, 2019  
HILTON ISTANBUL BOSPHORUS HOTEL  
ISTANBUL, TURKEY



### HERBAL DRUG INTERACTIONS AND NEW HORIZONS IN DERMATOLOGY

**Ahmet Metin**

For a long period of time in history, plants have been valuable and indispensable sources of natural products for the health of human beings. Even today people who live near to plant sources are dense like the forests use plant products to cure their many chronic diseases. Plants have a great potential for producing new drugs. Medicinal plants are also generally known as medicinal herbs. Herbs have been the main medical agents in traditional and holistic treatments for thousands of years. A huge part of the plant products is used as part of the traditional medical treatments which barely have any side effects and help in the treatment and cure. In India, Ayurvedic medicine dates back to 3000 BC and Chinese medicine dates back about 4000 years. In Western medicine, herbal therapy began as folk medicine. The last two decades have seen a rapid increase in usage of herbal medicine. There are several reasons for this, but the main ones are an increasing realization of the limits of modern medicine, particularly in the treatment of chronic disease; fear of adverse side effects of prescription drugs; and the increasing support for the medicinal use of plants from modern clinical research.

Almost 50% of the drugs used today are obtained directly from the plants. 40-70, thousand plant species have one or more medical applications in various systems of traditional medicine. According to the World Health Organization, 80% of the world's population mainly relies on plant-based traditional drugs specifically for primary health care needs. The belief that medicinal plants based on tradition are always safe to be "natural" or close to nature is not true recently. The advancement of technology has shown that in these herbs, they can detect small amounts of carcinogens, allergens, irritants and toxic chemicals and interact with some modern medicinal drugs. Thus, it has enabled the recognition of the potential hazardous effects of some plants used in traditional medicines for centuries. There are also some powerful features of the use of medicinal herbs. These are; the fact that humanity is used both as a food and a drug is based on trustworthy, working with physiological mechanisms of the body, strengthening the underlying weak areas (such as infections), being safe and accurate when used in a sensitive way, being trained by individuals and being able to enhance health, prevent problems or treat a disease. On the other hand, they are in a gentle structure that can be used without problems in many special patient groups like very young to oldest or pregnant patients. As proven by their use for a long time, the effectiveness and safety of the many widely known traditionally used key herbs have been demonstrated in medical researches and approved. They are also a renewable resource as natural products. All of these features have been provided them for widely accepted by large groups in both small and acute and chronic problems.

Since many years, a number of governments and international organizations have advocated the use of such local traditional medicine in primary health care. For this, however, it is necessary to have active substance (s) of known activity with at least non-toxic evidence. Although it is important to observing how animals use them as in the back of the traditional use for many plants; the scientific studies of chemical constituents, may support the knowledge on the mechanism of their action, the definitive knowledge about the therapeutic efficacy of a plant and its potential use can only be obtained through researches. However, for many reasons, there are problems related to the development, production, use and supervision of plants as modern medicines. There are, however, a number of hurdles to overcome. First of all in the present system in the Western world organizations like EMA and FDA make the rules for registration of novel medicines. These rules are based on a single target, single compound paradigm. In traditional medicine often mixtures of plants are used, in which each ingredient does have a certain meaning, and the ingredients and amounts given are part of a personalized medication. New approaches are thus required to deal with these problems. Particularly in Asia much of the traditional knowledge has already been recorded in books thousands of years ago and still plays a very important role in health care. So, as with any modern medicine, there is an urgent need to protect the rights of traditional medical development based on evidence to promote traditional medical studies.



# 4<sup>th</sup> INDERCOS

## Dermatology and Cosmetology Congress with International Participants

27 - 30 MARCH, 2019  
HILTON ISTANBUL BOSPHORUS HOTEL  
ISTANBUL, TURKEY



**Table 1:** Constituent and common medicinal activities of plants

CONSTITUENT	COMMON MEDICINAL ACTIVITY	EXAMPLES
Phenols	Often have anti-inflammatory, antiseptic, and antioxidant properties	Salicylic acid, found in willow II bark ( <i>Salix alba</i> )
Volatile oils	Stimulant, sedative, anti-inflammatory, and insecticidal	Essential oil of tea tree ( <i>Melaleuca alternifolia</i> )
Flavonoids	Many are strongly antioxidant and benefit the circulation, some are estrogenic	Rutin, found in lemon ( <i>Citrus limon</i> ) pith and peel
Tannins	Have astringent, binding (or tanning) action; often with potent antioxidant and anti-inflammatory	Catechins, found " in witch hazel ( <i>Hamamelis virginiana</i> )
Coumarins	Often have blood-thinning or antispasmodic properties	Aesculin, found in horse chestnut seed ( <i>Aesculus hippocastanum</i> ) .
Saponins	Key medicinal compounds similar in structure to the body's own hormones, often having hormonal or anti-inflammatory	Dioscin, found in Mexican wild yam ( <i>Dioscorea villosa</i> )
Anthraquinones	Constituents that at the right dosage act as laxatives	Sennosides, found in senna ( <i>Cassia</i> spp.)
Cardiac glycosides	Powerful compounds that act on the heart; often toxic	Digitoxin, found in foxglove ( <i>Digitalis purpurea</i> '
Cyanogenic glycosides	Compounds that contain cyanide; at low doses valuable as sedatives and relaxants	Sambunigrin, found in elder leaves ( <i>Sambucus nigra</i> )
Polysaccharides	Large molecules that typically have a demulcent/soothing effect on mucous membranes	Mucilage, found in slippery elm ( <i>Ulmus rubra</i> )
Bitters	Strongly bitter-tasting compounds that stimulate appetite and digestive function and slow the heart	Amarogentin, found in gentian ( <i>Gentiana lutea</i> )
Alkaloids	A diverse group of compounds, some with very potent activity as medicines, for example morphine	Isoquinoline alkaloids, found in Californian poppy ( <i>Eschscholzia californica</i> )

Every discovery and approach to the diagnosis of skin diseases has been released as a new horizon in dermatology and new breakthroughs have been opened. Understanding of bacterial diseases and skin structure by the discovery of microscope, treating most infectious and fatal diseases after antimicrobials, ultraviolet therapies, electrocautery, laser therapies and cryotherapy for many skin diseases are some of them. Thanks to the analysis and disclosure of phytochemicals in plants due to technological developments and the *in vivo* or *in vitro* researches done with them, our knowledge is constantly increasing and the behavior or effects of plants in the living organism are being put more clearly. A herb can contain hundreds of different constituent, but just a small amount of them have direct therapeutic activity. The main types of active ingredients in herbal medicines are listed in the table. If active components of a plant are known, it is possible to predict its medicinal effects in a wide range. For example linden flowers (*Tilia* spp) contain a volatile oil which have calming activity, flavonoids, mucilage, and phenols. These components correlate with linden



# 4<sup>th</sup> INDERCOS

## Dermatology and Cosmetology Congress with International Participants

27 - 30 MARCH, 2019  
HILTON ISTANBUL BOSPHORUS HOTEL  
ISTANBUL, TURKEY



flower's standard use as a remedy: to aid sleep and relaxation, relieve headache and fever, and lower blood pressure and support the circulation. They may also contain many nutrients, vitamins, and minerals. Herbal plants exhibit antimicrobial, antioxidant, anti-tumoral, anti-inflammatory, hormonal, blood diluent, loyalty, function regulator and supportive activity in addition to food supplements in human body thanks to their active ingredients.

In addition, many of them have been found in cosmetics or cosmeceuticals skin products for long times. Thus; they can be used for a variety of skin diseases ranging from cutaneous cancer to bacterial, viral and fungal diseases or from psoriasis to eczema, rozacea, and lichen planus.

Herbs can be used in 12 different ways to extract the active substance from fresh, dried or frozen parts of flowers, leaves, fruit seeds, roots and stem materials.

In the European Union, there are approximately 150,000 dual-trained doctors, meaning trained in conventional medicine and a particular CAM modality. In addition to these regularly trained physicians, 180,000 is a non-doctor CAM practitioner.

The use of complementary medicine for skin diseases and therefore herbs is common in all societies and is constantly increasing among dermatolog patiens. Because of their convenient availability, many patients with chronic dermatological diseases have attempted to take more control over their health by using herbs along with or instead of conventional treatments. Some patients have lost hope; standard treatments have failed to be effective for them. As a result, they seek newer therapies in an attempt to find a "cure" for their problems.

### CONCLUSIONS

plants have a great potential for producing new drugs. Although initially regarded as non-scientific, today the effectiveness of many plants has become the focus of attention by the mechanisms of action, the potential side effects, and scientifically researched for integration with conventional modern medicine. These researches continue to cover new indications and plants at an ever-increasing rate. Today, as the most important component of integrative dermatology, herbal treatments are well- accepted internationally with many new practices starting in many countries, such as the USA. Similar to the past, groundbreaking new horizons, such as the discovery of corticosteroids, biological agents, laser and phototherapy devices, are waiting ahead of us. The data on the phytochemical content of the plants are now more easily and quickly revealed by technology, and the information about them has been huge accumulated. The projects that will be planned by comparing the knowledge of thousands of years of traditional medicine with those pythochemical data will provide to researchers new study topics and more effective treatment approaches for patients. Today, many integrative dermatologists combine herbal treatment products to achieve the best outcomes for their patients by dermatologically or cosmetically.

### REFERENCES

- Chevallier A. Herbal remedies handbook : more than 140 plant profiles : remedies for more than 50 common conditions. New York: DK Publishing; 2018.
- Norman RA, Shenefelt PD, Rupani RN. Integrative dermatology. Oxford: Oxford University Press; 2014.
- Haq I. Safety of medicinal plants. Pakistan J. Med. Res. 2004;43(4).
- Edwards SE, Rocha I, Williamson EM, Heinrich M. Phytopharmacy : an evidence-based guide to herbal medicinal products. 2015.
- Mukherjee PK. Evidence-based validation of herbal medicine. Amsterdam; Waltham, MA: Elsevier; 2015.
- Agbabiaka TB, Spencer NH, Khanom S, Goodman C: Prevalence of drug-herb and drug-supplement interactions in older adults: a cross-sectional survey. Br J Gen Pract 2018;68:e711-e717.
- Tirant M, Lotti T, Gianfaldoni S, Tchernev G, Wollina U, Bayer P. Integrative Dermatology - The Use of Herbals and Nutritional Supplements to Treat Dermatological Conditions. Open Access Maced J Med Sci. 2018;6:185-202.
- França K, Lotti TM. Advances in integrative dermatology. Hoboken, NJ: Wiley-Blackwell; 2019.



# 4<sup>th</sup> INDERCOS

## Dermatology and Cosmetology Congress with International Participants

27 - 30 MARCH, 2019  
HILTON ISTANBUL BOSPHORUS HOTEL  
ISTANBUL, TURKEY



### **BOTANICAL DERMATOLOGY: PLANTS AND PLANT PRODUCTS INJURIOUS TO THE SKIN**

**Rafet Koca**

Zonguldak Bulent Ecevit University Faculty of Medicine Department of Dermatology and Venereology  
Plants are used by humans in daily life in many different ways, including as food, herbal medicines, and cosmetics. Skin reactions due to plants are common, as plants are ubiquitous and exhibit a number of physical and chemical properties that may result in harm. Phototoxic and phytochemical components are widely present in many different plant families. Many natural plants have photoactive chemicals. The photoactivities of these chemical constituents can be either harmful or beneficial to human health. Besides using plants as vegetables and fruits, their use as herbs and herbal dietary supplements also plays an important role. Concerning the harmful side effects, photoactivities, specifically phototoxicity, can cause damage to the skin. Subsequently it was found that humans who ingested phototoxic plants or phototoxic phytochemicals or who came into contact with those chemicals on the skin, and subsequently exposed to sunlight, were susceptible to phototoxic and photogenotoxic dermal effects, such as skin irritation, sensitization, allergy, mutations, and skin cancers. Four major types of cutaneous reactions following exposure to plant or plant-derived products have been described: irritant contact dermatitis, contact urticaria, allergic contact dermatitis, and phytophotodermatitis. The most important two are irritant contact dermatitis and phytophotodermatitis.





# 4<sup>th</sup> INDERCOS

## Dermatology and Cosmetology Congress with International Participants

27 - 30 MARCH, 2019  
HILTON ISTANBUL BOSPHORUS HOTEL  
ISTANBUL, TURKEY



### **LEUKOTRIENE RECEPTOR ANTAGONISTS IN THE TREATMENT OF SKIN DISEASES**

**Valentina Broshtilova**

The leukotriene receptor antagonists are successfully used to alleviate asthma and allergic rhinitis symptoms. They have been widely recognized in the combined therapeutic regimen of atopic diathesis syndrome. The therapeutic implications of montelukast have extended beyond the scope of asthma to the management of chronic urticaria and atopic dermatitis as proven by a handful of clinical observations and few trials. Leukotriene receptor antagonists are helpful therapeutic tools in the complex management of all age categories atopic dermatitis. Our own observations proved montelukast as a very effective corticosteroid-sparing option in the combined therapeutic regimen of corticosteroid-dependent atopic dermatitis patients, even in some severe erythrodermic cases.



# 4<sup>th</sup> INDERCOS

## Dermatology and Cosmetology Congress with International Participants

27 - 30 MARCH, 2019  
HILTON ISTANBUL BOSPHORUS HOTEL  
ISTANBUL, TURKEY



### EMERGENCY IVIg MANAGEMENT IN DERMATOLOGY

**Hilal Gökalp**

Intravenous immunoglobulin (IVIg) is a well-established procedure in numerous defined dermatological autoimmune diseases and toxic epidermal necrolysis (TEN). However, the exact mechanisms of action of IVIg are still unclear in these conditions and treatment with IVIg is based on case reports. The cost of the treatment limits its first-line use, and IVIg is generally reserved for patients who are refractory to conventional treatments.

At present IVIg can be used in severe forms of dermatomyositis, polymyositis, inclusion body myositis, severe forms of autoimmune blistering diseases, severe systemic vasculitic syndromes, severe forms of lupus erythematoses, scleromyxedema and TEN. It can be also used in atopic dermatitis, autoimmune urticaria, severe forms of collagen vascular diseases and livedoid vasculopathy less obviously. However, emergency IVIg management in dermatology is still controversial, and is generally used in TEN. TEN represents as a life-threatening side effect of medications. The condition has a progressive course with detachment of large areas of the epidermis in severe cases, and it is lethal in up to 40%. Because of its high mortality risk, these patients must receive intensive care. Early administration of high doses of IVIg ( $\geq 2$  g/kg) in TEN has been shown to be potentially life-saving. The dose regimen TEN differs from autoimmune diseases. Generally, a total dose of at least 3 g/kg is recommended. Fractionated administration (over 3-5 days) is essential, particularly in cardiovascular disease, diabetes and renal impairment. It has also suggested that IVIg treatment can be administered as a monotherapy, in addition to supportive measures. The concomitant treatment of immunosuppressive agents and corticosteroids is still controversial. The cessation of ongoing epidermal detachment and the onset of re-epithelialization are good clinical parameters for the treatment efficacy. However, survival is the most valid clinical parameter in TEN.



# 4<sup>th</sup> INDERCOS

## Dermatology and Cosmetology Congress with International Participants

27 - 30 MARCH, 2019  
HILTON ISTANBUL BOSPHORUS HOTEL  
ISTANBUL, TURKEY



### STEROID PHOBIA: WHAT CAN WE DO?

**Hilal Kaya Erdoğan**

Corticosteroids (CS) are mainstay of the treatment of many dermatological diseases such as atopic dermatitis and psoriasis. They have anti-inflammatory, anti-proliferative, vasoconstrictive and immunosuppressive effects. Topical corticosteroids (TCS) are often underutilised by many patients and parents of patients due to TCS phobia; accordingly TCS phobia can cause nonadherence to treatment and treatment failure. Patients and parents of patients are usually afraid of the side effects of TCSs. TCSs have side effects such as atrophy, hypopigmentation, hypertrichosis, osteoporosis, purpura-telangiectasia, striae, hypothalamic-pituitary-adrenal axis alteration and ophthalmological effects. Actually TCSs are very safe when they are used appropriately as per guidelines. Although the term "TCS phobia" is generally used for patients and parents of patients; TCS phobia can be seen even in physicians, nurses and pharmacists. There is doubt on the description and nomenclature of CS phobia. TCS phobia or corticophobia was defined by various ways such as "irrational fear of TCSs"; "anxiety about using TCSs"; "apprehension about cortisone; distrust of cortisone"; "negative attitudes toward TCSs" and "feelings of resistance about using TCSs". TCS phobia is common and prevalence ranges between 21.0-83.7%. The most common concerns about TCS phobia are skin thinning and the potential effects of TCS on growth and development. TCS phobia can be provoked by media and internet.

Education of patients and parents of patients is very important to prevent TCS phobia. Verbal information can be supported with written information explaining treatments (how much, how long to apply), and their side effects. These information can be conducted to patients through internet and specific websites. Besides, primary care clinicians, family practitioners, pediatricians, internists, nurses and pharmacists should be educated about TCSs; they should be noticed for TCS phobia. It is also important to pay attention to patients' perceptions and beliefs about TCS phobia. Emotional support of the patients and parents of the patients can help to overcome TCS phobia. It should be kept in mind that strong relationship between patient and physician is crucial to prevent and reduce TCS phobia.



# 4<sup>th</sup> INDERCOs

Dermatology and Cosmetology Congress  
with International Participants

27 - 30 MARCH, 2019  
HILTON ISTANBUL BOSPHORUS HOTEL  
ISTANBUL, TURKEY



## THE IMPACT OF PSYCHOSOCIAL STRESS ON HEALTHY SKIN

**Berna Aksoy**

Nowadays stress is described as the phenomenon in which a potentially harmful stimulus results in a physiological or psychological disturbance to body's normal physiologic equilibrium (Homeostasis). Upon perception of psychological stress, the central stress response leads to the activation of the hypothalamic–pituitary–adrenal axis that causes the release of corticotropin-releasing hormone (CRH), ACTH, and prolactin (PRL) and hence cortisol from the adrenal cortex. Sympathetic adrenal medulla pathway leads to the release of catecholamines from the adrenal medulla. Additionally peripheral renin-angiotensin system and cholinergic pathways become activated. In the skin's response to stress, mast cells occupy a central switchboard position. Mast cells are targets for stress-triggered factors as well as they act as important regulators of neurogenic inflammation during stress responses. Neurogenic inflammation leads to vascular permeability, edema and pain. Psychological stress leads to altered immune function, impaired wound healing, impaired barrier function, and impaired resistance to infections in healthy skin. Chronic stress conditions may trigger a wealth of inflammatory dermatological diseases especially atopic dermatitis and psoriasis, skin cancers especially melanoma and skin aging.





# 4<sup>th</sup> INDERCOS

## Dermatology and Cosmetology Congress with International Participants

27 - 30 MARCH, 2019  
HILTON ISTANBUL BOSPHORUS HOTEL  
ISTANBUL, TURKEY



### STAPHYLOCOCCUS AUREUS ERADICATION THERAPIES

Gülden Ersöz

Bacteria have been part of the normal human microflora and usually do not cause signs or symptoms of infection. This colonization is most common in body sites such as the nose, skin, and gastrointestinal tract. The body sites of colonization are usually specific to the type of bacteria. *S. aureus* and other coagulase-negative staphylococci (CNS) most commonly colonize the skin and mucosal membranes of the nose. Staphylococcal colonization can occur among both healthy and ill populations. Between 15 % to 30% of healthy adults are nasally colonized with methicillin-susceptible *S. aureus* (MSSA), and 1% to 3% are nasally colonized with MRSA. Hospitalized patients and long-term-care facility residents are at high risk of colonization with health care-associated pathogens. *S. aureus* colonization at other body sites, including the pharynx, groin, perianal region, or axilla, is also associated with development of *S. aureus* infections. Since colonization often leads to infection, two overarching approaches to health care-associated infections (HAIs) prevention have emerged: (i) horizontal strategies to broadly reduce the burden of all pathogens by infection control preventions and (ii) vertical approaches to reduce colonization or infection due to specific pathogens. Vertical approaches are directed at a single pathogen and often utilize active surveillance testing. This is important because multidrug-resistant organisms (MDROs), such as MRSA, are similar in that colonization precedes infection, transmission occurs by direct or indirect contact, and there are many more asymptomatic patients than infected patients. In addition, unrecognized colonized patients can be source of transmission of the bacteria. Decolonization strategies aim to decrease the bacterial burden in order to prevent transmission and infection. Often, these strategies are vertical strategies in which patients are screened for certain pathogens of interest (e.g., MRSA or VRE) and decolonized if they are found to carry those pathogens. This may prevent both endogenous and exogenous infections. *S. aureus* nasal carriers, approximately can be 40% persistent colonization and 60% intermittent colonization. The goal of decolonization is to eradicate the bacterial load on the body.

#### Nasal Topical Decolonization Strategies

##### Mupirocin

Mupirocin is a topical antibacterial agent made up of pseudomonic acids produced by the bacterium *Pseudomonas fluorescens*. This agent inhibits synthesis of bacterial proteins by reversibly binding. It has excellent activity against staphylococci, most streptococci, and some Gram-negative bacteria, including *Neisseria gonorrhoeae*, *Haemophilus influenzae*, and *Moraxella catarrhalis*. Nasal mupirocin is the most widely used topical antibacterial agent. A systematic literature review evaluated 23 clinical trials, including 12 trials that evaluated topically applied antibiotics. The authors concluded that short-term nasal mupirocin was the most effective treatment for MRSA decolonization, with success rates of 90% at 1 week after treatment and approximately 60% after a longer follow-up time. The effectiveness of mupirocin was similar for both MSSA and MRSA carriers. However, intranasal mupirocin treatment was evaluated for community-associated MRSA (CA-MRSA)-colonized soldiers could prevent infections. CA-MRSA was eradicated in colonized soldiers, but studies have shown that mupirocin-treated soldiers fail to reduce infections. In addition, CA-MRSA declonation did not prevent new colonization. Mupirocin resistance among *S. aureus* has now been identified in multiple studies, especially with widespread use over prolonged periods. There are two phenotypes of mupirocin resistance: low-level



# 4<sup>th</sup> INDERCOS

## Dermatology and Cosmetology Congress with International Participants

27 - 30 MARCH, 2019  
HILTON ISTANBUL BOSPHORUS HOTEL  
ISTANBUL, TURKEY



mupirocin resistance (LL-MR), and high-level mupirocin resistance (HL-MR) are uncommon. Certainly studies have shown that high-level mupirocin-resistant *S. aureus* results failure. The association between LL-MR and failure of mupirocin decolonization is unclear. If mupirocin suppresses growth of LL-MR MRSA it can be temporally and does not result in sustained decolonization.

### **Bacitracin**

The topical agent bacitracin is produced from *Bacillus subtilis*. It acts against MRSA and other Gram-positive bacteria by effect to bacterial cell wall synthesis. Soto et al. performed an RCT of a 5-day regimen of either mupirocin or bacitracin for *S. aureus* nasal decolonization in health care workers. It was shown that after 30 days, bacitracin was inferior to mupirocin for eradication of *S. aureus* (23% versus 80%;  $P < 0.01$ ).

Bacitracin is also available in combination with polymyxin B and/or neomycin. Neomycin is an aminoglycoside, which binds to the 30S ribosomal subunit and interferes with protein synthesis. Both polymyxin and neomycin also have activity against to Gram-negative bacilli. Some studies show that polymyxin and bacitracin are significantly less efficacious than mupirocin. In the other hand, rates of allergic dermatitis have also been found to be higher with bacitracin and neomycin than with mupirocin, ranging from 8% to 15%. Given inferior outcomes and increased risk of allergic dermatitis, the use of bacitracin-containing compounds cannot be recommended as a decolonization strategy.

### **Retapamulin**

Retapamulin belongs to a new antibiotic class called pleuromutilins. Retapamulin acts against Gram-positive and Gram-negative bacteria by interacting at the 50S subunit of the ribosome. It is approved for treatment of impetigo due to MSSA. It is also active against both MRSA and mupirocin-resistant staphylococci. Although this agent has not been approved by the U.S. Food and Drug Administration (FDA) for nares application.

### **Topical Chlorhexidine Gluconate**

Chlorhexidine, a topical antiseptic, has been used throughout the world for decades. Chlorhexidine gluconate (CHG) is a cationic biguanide that works by binding to bacterial cell walls, which alters the osmotic equilibrium of the bacterial cell. CHG has activity against Gram-positive and Gram-negative bacteria and yeasts. CHG has an excellent safety record. Adverse events associated with CHG are mild skin irritation and rare serious allergic reactions.

According to many research and guidelines, it is more effective than vertical strategies in healthcare settings, which are commonly recommended, including CHG baths and decolonization with mupirocin. Although the incidence of CHG resistance is currently low but, resistance to CHG should be monitored with more widespread use.

### **Povidone-Iodine**

Povidone-iodine (PI) is a complex of polyvinylpyrrolidone and tri-iodine ions that has been widely used as an antiseptic on skin, wounds, and mucous membranes. Specifically, PI has activity against both MSSA and MRSA. The results of studies suggested that PI may be a good decolonizing agent for the prevention of infections due to *S. aureus*, including MRSA and mupirocin-resistant strains, and may be a potential alternative to nasal mupirocin for prevention of SSIs, more studies are needed.

### **Alcohol-Based Nasal Antiseptic**

Alcohol has bactericidal activity against most Gram-positive and Gram-negative bacteria, including MDROs. Most alcohol-based hand antiseptics contain either isopropanol or ethanol. In a study, health care workers testing positive for nasal *S. aureus* colonization were treated three times during the day with



# 4<sup>th</sup> INDERCOS

## Dermatology and Cosmetology Congress with International Participants

27 - 30 MARCH, 2019  
HILTON ISTANBUL BOSPHORUS HOTEL  
ISTANBUL, TURKEY



a nasal alcohol-based antiseptic or placebo. The antiseptic formulation contained 70% ethanol combined with natural oil emollients and the preservative benzalkonium chloride. Nasal *S. aureus* and total bacterial colonization levels were determined before and at the end of a 10-hour shift.

### Oral Agents

Systemic antibiotics are usually unable to attain adequate concentrations in secretions to eradicate nasal *S. aureus*. Therefore, decolonization regimens may use a combination of oral antibiotics with topical therapies.

Pifampin (300 mg twice daily) and novobiocin (500 mg twice daily) combined or rifampin (300 mg twice daily) and trimethoprim (160 mg)-sulfamethoxazole (800 mg twice daily) combined decreased whole-body *S. aureus* colonization.

Seven-days regimen of 2% CHG bathing once daily, 2% intranasal mupirocin used three times daily, and combined with trimethoprim-sulfamethoxazole, novobiocin, clindamycin, doxycycline, or minocycline have all been evaluated as oral decolonizing agents, but current data have not demonstrated a preferred agent. In addition, it is unclear whether oral agents are more efficacious than topical decolonizing agents. The risk of resistance and side effects must be taken into consideration when evaluating these therapies. Current guidelines recommend against routine use of oral agents for eradication treatment.

### Investigational Nasal Agents

Ozenoxacin, a novel quinolone antibacterial agent with potent bactericidal activity against gram-positive bacteria, has been developed as a cream with 1% active drug for the treatment of impetigo, a highly contagious bacterial skin infection. Although this agent has not been approved by the FDA for nares using.

Tea tree oil is extracted from the *Melaleuca alternifolia* plant and has broad-spectrum antimicrobial activity. In a pilot study of 30 patients, a combination of 4% tree oil nasal ointment with 5% tree oil body wash was evaluated against 2% mupirocin nasal ointment with triclosan body wash for MRSA decolonization at 48 to 96 h. But, more studies are needed to determine the optimal concentration to eradicate colonization of *S. aureus*, to standardize that concentration, and to determine if decolonization with tea tree oil can reduce *S. aureus* infections.

Photodynamic Therapy; the use of a light source, such as a laser, has been suggested as an alternative method to eliminate MRSA nasal carriage. Photodynamic therapy is a promising approach for topical MRSA decolonization, but larger clinical trials are needed to evaluate different nasal decolonization protocols.

### Other methods to eradicate MRSA

Omigagan pentahydrochloride is a unique topical peptide that has in vitro activity against Gram-positive and Gram-negative bacteria and yeasts.

Lysostaphin is a glycylglycine endopeptidase that is active against staphylococci. Using 24-h time-kill studies, lysostaphin was more effective than either mupirocin or tea tree oil and may offer a therapeutic option, but results need to be validated by well-designed studies.

Vaccination can be a powerful intervention against infections, including nosocomial infections. Several attempts have been made to develop a safe and efficacious vaccine to prevent *S. aureus* infections. Two investigational anti-*S. aureus* vaccines showed promise and reached advanced clinical trial stages.

In conclusion; decolonization prevents both vertical and horizontal transmission of MDROs and the strongest evidence for decolonization is among surgical patients in order to prevent SSIs. Mupirocin still remains the gold standard agent for nasal eradication of *S. aureus*, but there is concern about mupirocin resistance, and alternative agents are needed. The most promising new agents for nasal decolonization



# 4<sup>th</sup> INDERCOS

## Dermatology and Cosmetology Congress with International Participants

27 - 30 MARCH, 2019  
HILTON ISTANBUL BOSPHORUS HOTEL  
ISTANBUL, TURKEY



are retapamulin, povidone-iodine, and alcohol-based nasal antiseptics. Chlorhexidine gluconate is the skin decolonization agent that has the strongest evidence base. CHG skin decolonization is an effective horizontal strategy to reduce both the bio-burden on the skin and subsequent infection. However, with wide- spread use, we need to monitor for the incidence of chlorhexidine resistance. Orally administered systemic decolonizing agents, such as oral TMP-SMX, may be acceptable for nasal decolonization of MRSA. Acute short-term use of decolonizing agents, such as prior to surgery, is recommended in order to avoid adverse outcomes such as recolonization and resistance. Resistance to both mupirocin and chlorhexidine has been seen when they are used over a long time period.

### References

- Wertheim HF, Melles DC, Vos MC, et al. The role of nasal carriage in *Staphylococcus aureus* infections. *Lancet Infect Dis* 2005; 5:751–762.
- Septimus EJ, Schweizer ML. Decolonization in prevention of health care-associated infections. *Clinical Microbiology Reviews* 2016, 29 (2) 201-222;
- den Heijer CD, van Bijnen EM, Paget WJ, et al. Prevalence and resistance of commensal *Staphylococcus aureus*, including methicillin-resistant *S aureus*, in nine European countries: a cross-sectional study. *Lancet Infect Dis* 2013; 13:409–415.
- Graham PL, III, Lin SX, Larson EL. A U.S. population-based survey of *Staphylococcus aureus* colonization. *Ann Intern Med* 2006; 144:318 – 325
- Williams V, Simor AE, Kiss A, et al. Is the prevalence of antibiotic-resistant organisms changing in Canadian hospitals? Comparison of point-prevalence survey results in 2010 and 2012. *Clin Microbiol Infect* 2015; 21:553–559.
- Septimus EJ, Weinstein RA, Perl TM, et al. Approaches for preventing healthcare-associated infections: go long or go wide? *Infect Control Hosp Epidemiol* 2014; 35(Suppl 2):S10–S14.
- Septimus EJ, Hayden MK, Kleinman K, et al. Does chlorhexidine bathing in adult intensive care units reduce blood culture contamination? A pragmatic cluster-randomized trial. *Infect Control Hosp Epidemiol* 2014; 35(Suppl 3):S17–S22.
- Climo MW, Yokoe DS, Warren DK, et al. Effect of daily chlorhexidine bathing on hospital-acquired infection. *N Engl J Med* 2013;368:533–542.
- Huang SS, Septimus E, Kleinman K, et al. Targeted versus universal decolonization to prevent ICU infection. *N Engl J Med* 2013; 368:2255–2265.
- Noto MJ, Domenico HJ, Byrne DW, et al. Chlorhexidine bathing and health care-associated infections: a randomized clinical trial. *JAMA* 2015; 313:369–378
- Troeman DPR, Van Hout D, Kluytmans JAJV. Antimicrobial approaches in the prevention of *Staphylococcus aureus* infections: a review, *Journal of Antimicrobial Chemotherapy*, 2019; 74:281–294





# 4<sup>th</sup> INDERCOS

## Dermatology and Cosmetology Congress with International Participants

27 - 30 MARCH, 2019  
HILTON ISTANBUL BOSPHORUS HOTEL  
ISTANBUL, TURKEY



### **AUTOIMPLANTATION THERAPY FOR SKIN DISEASES**

**Emin Özlü**

Immunotherapy is described as a type of biological treatment that uses materials to activate or suppress the immune system to help the body defense. Some immunotherapy methods target specific cells; whereas others affect the immune system in general.

Autoimplantation is a novel, procedure which uses for treating the viral skin diseases by stimulating an immune response. This procedure was mainly used in the treatment of extensive viral warts. In this lecture, procedure, mechanisms of action, clinical uses, possible future indications and side effects of autoimplantation therapy will be presented.



# 4<sup>th</sup> INDERCOS

## Dermatology and Cosmetology Congress with International Participants

27 - 30 MARCH, 2019  
HILTON ISTANBUL BOSPHORUS HOTEL  
ISTANBUL, TURKEY



### SUN PROTECTION IN INTEGRATIVE DERMATOLOGY - FROM COSMETIC PURPOSES TO SKIN CANCER PREVENTION

**Aleksandra Vojvodic**

Integrative Dermatology is a relatively new term coined to describe treatment therapy that combines conventional practice, Complementary and Alternative medicine and the latest research findings. UVR induces DNA damage, but also and damage of proteins and lipids (chromophore), directly and indirectly producing cytokines and hemokines. Even sub-erythemogenic doses have great influence on skin. Short-term cutaneous effects of UV radiation include acute inflammatory erythema and pigment darkening, delayed hyperpigmentation, epidermal hyperplasia, immunomodulatory changes and vitamin D3 synthesis. Chronic effects include photoaging and photocarcinogenesis. Only certain individuals develop abnormal reactions – photodermatoses (polymorphic light eruption, actinic prurigo, solar urticaria, etc), phototoxic and photoallergic reactions. Cutaneous signs of significant photodamage are solar elastosis, wrinkling, dyschromia, pseudoscras, solar lentigines, ephelides, actinic keratoses, BCC, SCC, melanoma, etc.

The best protection from the UVR is avoiding sunlamps and parlours and midday sun exposure. Using protective clothes and broad-spectrum sunscreen of SPF 50+ before sun exposure and than every two hours or after working, swimming, playing or exercising outdoors is essential for protecting. There are a lot of different types of sunscreen products / for different types of the skin, for face/body, baby/adults, photosensitive skin, etc. They are multifunctional products with a lot of effects – UVR protection, hydration, anti-age, sebum control, etc. Less used are pills for UVR protection. They contain *Polypodium leucotomas* extract, a natural product derived from a tropical fern. PL is classified as an oral dietary supplement. PL has been noted to exhibit photoprotective, antioxidant, and chemopreventative properties in animal and human studies. Decreases depletion of epidermal antigen-presenting cells, reduction in UV-induced photodamage effects, such as sunburn cells, maturation disarray, and keratinocyte vacuolization; reduction in tumor formation in mice, reduction in UV-induced COX-2 expression (2-fold to 4-fold decrease; murine study), reduction in UV-induced macrophages and neutrophils (murine study), downregulate production/release of chemical markers, such as iNOS which is increased during UV exposure, reduce antioxidant depletion in UV-irradiated skin and protect non-irradiated skin (4-fold decrease in oxidized glutathione; animal study), increased p53 suppressor activity promoting clearance of cyclobutane pyrimidine dimers (CPDs) (human study), decrease in UV-induced increase in CPDs compared to untreated skin (human and mouse studies), decrease in common deletions induced by UVA (human study), reduction in UV-induced erythema in UV-exposed skin; decrease in erythema and pigmentation in psoralen plus ultraviolet light therapy (PUVA)-exposed skin. There are a few studies that are not enough to show a slight benefits of taking vitamin E and C, nicotinamide, beta-carotene and astaxanthin to promote protection of the skin to UVR. Current data indicate that the vitamin A system is a direct target of both UVB and UVA and participates in an adaptive response to UV exposure. Interfering with this UV-induced vitamin A deficiency could be a new concept for the prevention of skin cancer and aging.

Further studies are necessary for researching effects of different food supplements on protection of the skin from the UVR. Also improving of the cosmetic and protective characteristics of sunscreen products is very important.



# 4<sup>th</sup> INDERCOS

## Dermatology and Cosmetology Congress with International Participants

27 - 30 MARCH, 2019  
HILTON ISTANBUL BOSPHORUS HOTEL  
ISTANBUL, TURKEY



### **CHRONIC PRURITUS – DEFINITION, CLASSIFICATION, ASSESSMENT, IMPACT**

**Martin Metz**

In the 17<sup>th</sup> century Samuel Hafnenreffer, a German physician, described pruritus as an unpleasant sensation of the skin, which provokes scratching. Chronic pruritus is defined as pruritus that occurs for six weeks or longer, and this often leads to an almost unbearable burden for those affected. The International Forum for the Study of Itch (IFSI) classifies chronic pruritus clinically into three groups. 1) Chronic pruritus on primarily altered skin (i.e. in the presence of a skin disorder), 2) chronic pruritus on primarily unaltered skin (i.e. without the initial presence of skin lesions) and 3) chronic pruritus with scratch lesions (in patients where secondary scratch lesions do not allow for a classification into the first or second group). Dermatological disorders usually fall into the first category, while systemic disorders (e.g. kidney- or liver-associated pruritus), neurological and psychosomatic disorders mostly fall into the second category. In many patients, however, more than one cause is responsible for chronic pruritus. Pruritus can be an exceptionally burdensome symptom in many dermatological or non-dermatological diseases; therefore an accurate assessment of the presence and intensity of itch is crucial. As the perception of pruritus is subjective, it is recommended to use a visual analogue scale (VAS) or a verbal rating scale (VRS) for the assessment of pruritus severity. Furthermore, assessment of the impact of pruritus on the patients quality of life needs to be assessed and appreciated. To this end, quality of life questionnaires and other Patient Reported Outcome measures should be used.

In this presentation, I will review the current guidelines on the definition and classification of the chronic pruritus and will give examples on the importance of assessing pruritus severity and, most of all, the impact of chronic pruritus in various diseases.



# 4<sup>th</sup> INDERCOS

## Dermatology and Cosmetology Congress with International Participants

27 - 30 MARCH, 2019  
HILTON ISTANBUL BOSPHORUS HOTEL  
ISTANBUL, TURKEY



### **CHRONIC PRURITUS DUE TO EXTRACUTANEOUS CAUSES - GASTROINTESTINAL, ENDOCRINE, NEPHROLOGY, HEMATOLOGY/ONCOLOGY AND TREATMENT**

**Ragıp Ertaş**

Pruritus is a frequent and distressing symptom in the general population. It is known as the most common presenting symptom in dermatology out-patient clinics. Approximately 20% of the general population has suffered from chronic pruritus (CP) at least once in a lifetime. It causes a significantly impaired quality of life similar to that of chronic pain and its often refractor to therapy.

The focus of the current speech is the understanding and management of chronic pruritus in the course of the non-dermatological systemic diseases. Especially in non-diseased skin, it may be caused by systemic diseases such as kidney diseases, hepatobiliary diseases, metabolic and endocrine diseases, malignancies, infectious diseases, neurological or psychiatric diseases, as well as being a side effect of medications. There can be multifactorial reasons in some of the cases.

In patients where no cause can be identified or treated, symptomatic treatment may be appropriate. However, when the possible systemic cause of the pruritus is known, the treatment of the underlying disease should be the main target of the management in patients with chronic pruritus. Therefore, CP needs multi-disciplinary approach with multimodal and performed in a step-wise procedure. The management of patients with CP can be divided into topical treatment modalities, ultraviolet phototherapy, systemic treatments, psychological approaches or alternative therapies. In general, because of the individual differences of the patients with CP, therapy of the pruritus should be individualized according to the patient's circumstances.

#### **References**

- Weisshaar, E. and F. Dalgard. Epidemiology of itch: adding to the burden of skin morbidity. *Acta Derm Venereol* 2009; 89(4): 339-350.
- Weisshaar, E., C. Apfelbacher, G. Jager, E. Zimmermann, T. Bruckner, T. L. Diepgen and H. Gollnick. Pruritus as a leading symptom: clinical characteristics and quality of life in German and Ugandan patients. *Br J Dermatol* 2006; 155(5): 957-964.
- Millington GWM, Collins A, Lovell CR, Leslie TA, Yong ASW, Morgan JD, Ajithkumar T, Andrews MJ, Rushbook SM, Coelho RR, Catten SJ, Lee KYC, Skellett AM, Affleck AG, Exton LS, Mohd Mustapa MF, Levell NJ. British Association of Dermatologists' guidelines for the investigation and management of generalized pruritus in adults without an underlying dermatosis, 2018. *Br J Dermatol*. 2018; 178:34-60.
- Weisshaar E, Szepietowski JC, Darsow U, Misery L, Wallengren J, Mettang T, Gieler U, Lotti T, Lambert J, Maisel P, Streit M, Greaves MW, Carmichael AJ, Tschachler E, Ring J, Ständer S. European guideline on chronic pruritus. *Acta Derm Venereol*. 2012;92(5):563-81.





# 4<sup>th</sup> Indercos

## Dermatology and Cosmetology Congress with International Participants

27 - 30 MARCH, 2019  
HILTON ISTANBUL BOSPHORUS HOTEL  
ISTANBUL, TURKEY



### REGISTRY SYSTEMS FOR PSORIASIS

#### Kemal Özyurt

Patient Registry System (PRS) includes structured observational data of a group of patients with certain disease or medical condition. PRS provides detailed and comprehensive data for common or uncommon diseases, in a “real-world” setting. Distinct from PRS, Randomized Clinical trials (RCTs), patient registries consist more rigorous and designed inclusion and exclusion criteria. Thus, PRS allows to investigate larger populations of patients, with increased generalizability of results to clinical practice. Moreover, PRS provides important pharmacovigilance data of drug therapies, such as biologic agents, for observing long-term safety data. Psoriasis is a common disease in all over the world, prevalence of psoriasis European countries ranges from 1, 2% in Croatia to 8, 5% in Norway.

Treatment of psoriasis consists broad spectrum of conventional systemic therapies and biologics. Thus long-term data on efficacy and safety have great importance for dermatologists.

Also, PRS includes available experience and structured information about the treatment strategies, such as the switching or combination therapies, the optimization of dosages or duration of drugs. This presentation will review PRS in all over the world and discuss the importance of it in psoriasis.



# 4<sup>th</sup> INDERCOS

## Dermatology and Cosmetology Congress with International Participants

27 - 30 MARCH, 2019  
HILTON ISTANBUL BOSPHORUS HOTEL  
ISTANBUL, TURKEY



### LABORATORY PROCEDURES AND CONSULTATIONS BEFORE AND DURING TREATMENT OF PSORIASIS

Ömer Faruk Elmas

Psoriasis is a chronic, complex, multifactorial, inflammatory disease with an increase in the epidermal cell turnover rate. Environmental, genetic, and immunologic factors play important roles. The disease most commonly affects the skin of the elbows, knees, scalp, lumbosacral areas, intergluteal clefts, and glans penis. The joints may also be affected. Treatment is essentially based on the severity of the disease, presence or absence of arthritis and associated comorbidities if any.

In the patients with psoriasis having infectious diseases using drugs that modify immunologic response, determining the type of therapy is crucial and, if such an agent is identified, referral to a infectious diseases specialist may be needed.

Many authors suggest that the possible comorbidities of heart and cardiovascular diseases in adult patients with psoriasis should be evaluated. So, referral to a cardiologist may be appropriate.

Patients with severe psoriasis have a higher incidence of depression and this situation may require referral to a mental health specialist.

Autoimmune diseases are considered to be associated with higher incidence of lymphoma and myelodysplastic disease. It is not clearly revealed yet whether this increased rate associated with the disease itself or with treatment. Patients having laboratory abnormalities or physical findings of hematologic disease or malignancy should be referred to a hematologist or oncologist.

The diagnosis of psoriasis is clinical, however some laboratory investigations may be needed if starting systemic therapies. We suggest that the laboratory investigations should be in accordance with the published national and international management guidelines before starting any systemic treatments. However, complete blood cell count, blood urea nitrogen/creatinine, liver function tests, hepatitis panel, tuberculosis screening, and pregnancy test are the basic investigations before starting immunologic and immunosuppressive therapies.

In conclusion laboratory procedures and consultations before and during treatment of psoriasis should be personalised in accordance with the medical history, physical findings, comorbidities and the chosen treatment agents.



# 4<sup>th</sup> INDERCOS

## Dermatology and Cosmetology Congress with International Participants

27 - 30 MARCH, 2019  
HILTON ISTANBUL BOSPHORUS HOTEL  
ISTANBUL, TURKEY



### LONG TERM SAFETY PROFILES OF SYSTEMIC THERAPIES OF SYSTEMIC THERAPIES IN PSORIASIS

Zafer Türkoğlu

	Psoriatic Arthritis	History of Cancer	Cardiovascular Disease <sup>1</sup>	Obesity	Infections	IBD	Demyelinating Disease
TNF- $\alpha$ inhibitors	++		++	++ <sup>2</sup>		++	×
IL-12/IL-23 inhibitor	+	+	+	++ <sup>2</sup>	+	+	+
IL-17 inhibitors	+	ID	+	+	+	×	+
IL-17R inhibitor	TBD <sup>3</sup>	ID	+	+	+	×	+
IL-23 inhibitors	TBD <sup>3</sup>	ID	+	+	+	TBD	+

Abbreviations: IBD, inflammatory bowel disease; TNF, tumor necrosis factor; ID, insufficient data to make a recommendation; TBD, to be determined.  
\*++ indicates first-line option; +, good option; ×, contraindication. These options are based on the opinion of the authors.  
<sup>1</sup>Other than severe congestive heart failure.  
<sup>2</sup>Infliximab and ustekinumab are weight based.  
<sup>3</sup>Data submitted and under review.

#### TNF- $\alpha$ INHIBITORS

Drugs in this category include: etanercept, infliximab, adalimumab, certolizumab, and golimumab. Side effects of TNF- $\alpha$  inhibitors include injection site reactions, upper respiratory tract infections, drug-induced lupus, abnormal liver function tests, and palmoplantar pustulosis. A small increased risk of non-melanoma skin cancers and other malignancies has also been reported. Reactivation of tuberculosis and hepatitis have been reported with TNF- $\alpha$  inhibition. Data suggest that infliximab may be associated with more serious infections. Neurological disorders (demyelinating conditions) such as multiple sclerosis and demyelinating disorders have been shown to either develop or get worse following treatment with TNF- $\alpha$  inhibitors. Positive ANA has been noted to occur with TNF- $\alpha$  inhibitors, and several cases of systemic lupus erythematosus have been reported. Infusion reactions are specifically noted with infliximab, 1% severe. TNF- $\alpha$  inhibitors should be avoided in patients with decompensated heart failure. Rare cases of liver enzyme elevation and cytopenia have been noted.

TNF- $\alpha$  inhibitors adalimumab and infliximab are indicated for inflammatory bowel disease (IBD). TNF- $\alpha$  is upregulated in obesity, cardiovascular disease, and atherosclerotic plaques. Evidence suggests that TNF- $\alpha$  inhibitors may lower cardiovascular risk over time. For patients with obesity, infliximab is a good option, as it is the only TNF- $\alpha$  inhibitor with weight-based dosing. In patients with frequent infections or history of hepatitis C, etanercept has been the biologic most commonly used when no alternatives exist, in part due to its shorter half-life.

#### USTEKINUMAB (IL12/23 inhibitor)

Safety data on prospective trials over 5 years showed very low rates of adverse events (AEs), serious infections, malignancies, and major adverse cardiovascular events with Ustekinumab. Laboratory abnormalities did not arise in trials. Periodic tuberculosis screening is required but Hepatitis B and C is not required. Ustekinumab did not worsen or improve demyelinating disease.



# 4<sup>th</sup> INDERCOS

## Dermatology and Cosmetology Congress with International Participants

27 - 30 MARCH, 2019  
HILTON ISTANBUL BOSPHORUS HOTEL  
ISTANBUL, TURKEY



### **IL 17 INHIBITORS: (Secukinumab, Ixekizumab, and Brodalumab)**

The safety profile of IL-17 inhibitors is reassuring, and common adverse effects noted in clinical trials include upper respiratory tract infections, nasopharyngitis, headache, mild neutropenia (not associated infection risk), diarrhea, and candida mucocutaneous infections. Other less common side effects reported are injection site reactions, arthralgias, fatigue.

Inflammatory bowel disease (IBD) is an adverse event of special interest with IL-17 inhibitors. Psychiatric adverse effects were noted specifically with brodalumab, including depression, suicidal ideation, and behavior. Risk Evaluation and Mitigation Strategy was instituted for required surveillance of brodalumab-treated patients for suicide and suicidal ideation.

Ixekizumab and secukinumab also are approved for PsA. Although improvement in joint disease is not as fast as with the anti-TNF inhibitors, notable improvement occurs by week 20 to 24.

### **IL 23 INHIBITORS: (Tildrakizumab, Guselkumab, Risankizumab)**

The side effect profile of IL-23 inhibitors is favorable with non-serious infections being most common, such as upper respiratory tract infections, gastroenteritis, tinea, and herpes simplex infections. Other common side effects noted are nasopharyngitis, arthralgia, mild elevation of liver enzymes, and injection site reactions. Rare adverse events such as skin and soft tissue abscesses and non-melanoma skin cancers have also been noted. These drugs are still new, and more studies are needed to better understand their long-term side effects.

Guselkumab and tildrakizumab demonstrated efficacy with minimal AEs or precautions noted thus far. Infections are again a risk, making tuberculosis testing the only recommended monitoring (Table 2). Table 3. Laboratory screening for biologics

### **References**

- Cather MK, et al. Biologic Therapy in Psoriasis: Navigating the Options. *Cutis*. 2018;102(suppl 5):13-17.
- Cohen AD, et al. Psoriasis associated with ulcerative colitis and Crohn's disease. *J Eur Acad Dermatol Venereol*. 2009;23:561-565.
- Gaeta M, et al. Role of psoriasis as independent predictor of cardiovascular disease: a meta-regression analysis. *Int J Cardiol*. 2013;168:2282-2288.
- Rodríguez-Zúñiga MJM, et al. Systematic review and meta-analysis of the association between psoriasis and metabolic syndrome. *J Am Acad Dermatol*. 2017;77:657-666.e8.
- Armstrong AW, et al. From the Medical Board of the National Psoriasis Foundation: treatment targets for plaque psoriasis. *J Am Acad Dermatol*. 2017;76:290-298.
- Papp KA, et al. Long-term safety of ustekinumab in patients with moderate-to-severe psoriasis: final results from 5 years of follow-up. *British Journal of Dermatology*. 2013;168:844-854.
- Gottlieb AB, et al. Safety Observations in 12095 Patients With Psoriasis Enrolled in an International Registry (PSOLAR): Experience With Infliximab and Other Systemic and Biologic Therapies *J Drugs Dermatol*. 2014;13(12):1441-1448.
- Kaushik SB, et al. Review of safety and efficacy of approved systemic psoriasis therapies. *International Journal of Dermatology*. 2018. doi:10.1111/ijd.14246.
- Schmitt J, et al. Efficacy and safety of systemic treatments for moderate-to-severe psoriasis: meta-analysis of randomized controlled trials. *British Journal of Dermatology*, 2014, 170.2: 274-303.
- Lernia VD, et al. An overview of the efficacy and safety of systemic treatments for psoriasis in the elderly, Expert Opinion on Biological Therapy. 2018. DOI: 10.1080/14712598.2018.1504016.





# 4<sup>th</sup> INDERCOS

## Dermatology and Cosmetology Congress with International Participants

27 - 30 MARCH, 2019  
HILTON ISTANBUL BOSPHORUS HOTEL  
ISTANBUL, TURKEY



### INJECTION PHOBIA: WHAT CAN WE DO IN AESTHETIC DERMATOLOGY

Ömer Faruk Elmas

Needle phobia, also known fear of needles or injection phobia, is the extreme fear of medical procedures including injections or hypodermic needles. It is sometimes referred to by different names like aichmophobia or belonephobia, trypanophobia. It is estimated that nearly 10% of the population have a fear of needles. Some authors suggest that the condition may have a genetic basis. Approximately 80% of people with a fear of needles report that a relative within the first degree exhibits the same disorder. Types of needle phobia includes vasovagal, associative, resistive, hyperalgeziec. The medical literature suggests a number of methods that have been proven effective for specific cases of needle phobia. These methods are as follows;

-Ethyl Chloride Spray. Easily administered, but provides only superficial pain control.

-Jet Injectors. Jet Injectors work by introducing substances into the body through a jet of high-pressure gas as opposed to by a needle. Though these eliminate the needle, some people report that they cause more pain.

-Iontophoresis. Iontophoresis drives anesthetic through the skin by using an electric current. It provides effective anesthesia, but is generally unavailable to consumers on the commercial market and some regard it as inconvenient to use.

-EMLA. EMLA is a topical anesthetic cream that is a mixture of lidocaine and prilocaine. Although not as effective as iontophoresis, since EMLA does not penetrate as deeply as iontophoresis-driven anesthetics, EMLA provides a simpler application than iontophoresis. EMLA penetrates much more deeply than ordinary topical anesthetics, and it works adequately for many individuals.

-Ametop. Ametop gel contains only tetracain and appears to be more effective than EMLA for eliminating pain during injection

-Lidocaine/tetracaine patch. A self-heating patch containing a mixture of lidocaine and tetracaine. The patch requires 20 to 30 minutes to achieve full anesthetic effect.

-Behavioral therapy. Effectiveness of this method varies greatly depending on the person and the severity of the condition. There is some debate as to the effectiveness of behavioral treatments for specific phobias (like blood, injection, injury type phobias), though some data are available to support the efficacy of approaches like exposure therapy.

-Nitrous Oxide (Laughing Gas). This will provide sedation and reduce anxiety for the patient, along with some mild analgesic effects.

-Benzodiazepines, such as diazepam or lorazepam, may help alleviate the anxiety of needle phobics

-General Anesthesia. This will eliminate all pain and also all memory of any needle procedure. On the other hand, it is often regarded as a very extreme solution and most physicians do not order it. It can be risky and expensive and may require a hospitalization.



# 4<sup>th</sup> INDERCOs

## Dermatology and Cosmetology Congress with International Participants

27 - 30 MARCH, 2019  
HILTON ISTANBUL BOSPHORUS HOTEL  
ISTANBUL, TURKEY



### MEDICAL GLOVES FOR DERMATOLOGIST

**Ömer Faruk Elmas**

The main purpose of medical gloves is form a protective barrier to prevent transmission of diseases between caregivers and patients during medical procedures. There are two main types of medical gloves: Surgical gloves and medical examination gloves. Surgical gloves are sterile gloves and have a more appropriate sizing than examination gloves.

The commonest medical gloves material is latex. The incidence of allergic and irritant reactions to latex began to increase among patients and caregivers in the 1990s. Since then, new synthetic glove materials having different properties with regards to strength, comfort and sensitivity have been developed. However, overwhelming majority of medical gloves are still made from latex. Neoprene and polyisoprene are the latex free synthetic materials used in medical gloves.

Apart from material used, the important factors that establish the level of barrier protection include length of time the glove is worn, handling of equipment that may stress the glove material, chemicals coming into contact with the glove and the fit of the glove.

Latex allergy, allergic contact dermatitis and irritant contact dermatitis are the common allergic reactions associated with medical gloves. Non-powdered gloves are less irritating than powdered gloves. FDA rules to ban powdered surgical gloves and powdered patient examination gloves in January 2017. Consistent hand care regimen is crucial to avoid skin irritation from surgical gloves.



# 4<sup>th</sup> Indercos

## Dermatology and Cosmetology Congress with International Participants

27 - 30 MARCH, 2019  
HILTON ISTANBUL BOSPHORUS HOTEL  
ISTANBUL, TURKEY



### **TOPICAL ANESTHETICS, NERVE BLOCKS AND ANESTHESIA OF ORAL MUCOSA IN AESTHETIC DERMATOLOGY**

#### **Tuğrul Dereli**

One of the most important events in the history of medicine is the discovery of local anesthetics. Cocaine, the first local anesthetic, was discovered towards the end of the 19th century, then procaine and forty years later, the most commonly used lidocaine was synthesized.

In aesthetic dermatology, local anesthetics can be applied in the form of topical, infiltrative, nerve blocks or tumescent anesthesia. In this presentation, I will give a simple topical anesthetic formula that I use in many of the aesthetic procedures. I will also talk about the most commonly used nerve blocks in aesthetic surgery.



# 4<sup>th</sup> INDERCOS

## Dermatology and Cosmetology Congress with International Participants

27 - 30 MARCH, 2019  
HILTON ISTANBUL BOSPHORUS HOTEL  
ISTANBUL, TURKEY



### PUNCH AND SHAVE EXCISIONS IN DERMATOLOGY

**Necmettin Akdeniz**

The skin biopsy is a simple procedure that can assist with the diagnosis of cutaneous disorders. Skin biopsies can provide diagnostic information about undiagnosed lesions such as neoplasms, bullous disorders, keratoses, or dysplastic nevi. A skin biopsy can also be the definitive treatment for numerous benign skin tumors, some malignant, irritated, or precancerous lesions.

**Shave biopsy** is the most commonly used technique because of how quickly it can be performed, the simplicity of wound care, cosmesis, and cost-effectiveness.

Shave biopsies can be either superficial or deep. Superficial shave biopsies are done across or nearly parallel to the skin surface and extend into the epidermis only or epidermis and limited superficial dermis. The slightly deeper shave biopsy allows for sampling of dermis and epidermis, important for assessing basal cell and squamous cell carcinomas.

Shave biopsies require little training, and do not require sutures for closure; Lesions that are most suitable for shave biopsies are either elevated above the skin or have pathology confined to the epidermis. Examples include seborrheic or actinic keratoses, skin tags, warts, and superficial basal cell or squamous cell carcinomas. Superficial shave biopsies should not be used for papular or tumoral pigmented lesions; an unsuspected melanoma cannot be properly staged if partially removed. This procedure yields a flat, preferable to a technique requiring sutures because of excessive tension. With shave biopsies, a small, depressed scar does occur. Macular pigmented lesions, especially those 5–8 mm in diameter, it is preferable to use the shave technique to maximize the rate of negative margins.

A superficial shave removes a thin disk of tissue, typically by scalpel (generally a no. 15 blade), although many physicians prefer a Dermablade, a double-edged razor blade, or scissors.

Limitations of the shave biopsies are that it may not provide a deep enough sample in suspect pigmented lesions (because of the superficial nature of the specimen), which in turn may affect tumor staging and prognosis. With shave biopsies, a small, depressed scar about the size of the initial lesion does occur.

**Punch biopsy** is considered the primary technique to obtain diagnostic, full-thickness skin specimen. Punch biopsies are performed with disposable punch instrument with a cylindrical blade ranging in diameter from 2 to 10 mm; 3 mm is the smallest size likely to give sufficient tissue for consistently accurate histologic diagnosis. The punch is an ideal procedure for diagnostic skin biopsy or removing small lesions. It often provides a better cosmetic result than a shave biopsy. Punch biopsies may be used for lesions that require dermal or subcutaneous tissue for diagnosis, including inflammatory or bullous lesions, dysplastic or complex nevi that are too large to be excised, panniculitis, and scalp or hair follicle biopsies. Punch biopsies are easily mastered by most practitioners, are quick, and have a low incidence of infection, bleeding, nonhealing, or significant scarring. They can heal by secondary intention, but punches greater than 3 mm may produce unacceptable scarring and are best closed with one or two sutures.

Limitations of the punch biopsy are that it may not provide a wide enough sample in suspect pigmented lesions (because of the narrow, deep nature of the specimen), which in turn may affect tumor staging and prognosis.

There are few absolute contraindications to skin biopsy; it usually should not be performed at an infected





# 4<sup>th</sup> INDERCOS

## Dermatology and Cosmetology Congress with International Participants

27 - 30 MARCH, 2019  
HILTON ISTANBUL BOSPHORUS HOTEL  
ISTANBUL, TURKEY



site, although occasionally infection is the indication for the procedure. Patients should be asked about allergies to topical antibiotics, antiseptics, local anaesthetics, and reactions to tape. Inquiries also should be made regarding bleeding disorders, bleeding with previous surgery, and use of drugs known to interfere with hemostasis. Excessive bleeding is rarely a problem in patients taking oral anticoagulants or antiplatelet agents. Patients taking aspirin can generally be managed with careful attention to hemostasis and the use of a pressure dressing. These medications should generally not be discontinued for simple skin biopsies.

In conclusion, skin biopsy is an essential technique in the management of skin diseases, but it cannot replace clinical knowledge. Shave biopsy requires the least experience and time, but its use is limited to superficial lesions and should not be used for pigmented lesions. Punch biopsy is the primary diagnostic procedure in dermatology, is simple to perform, has few complications, and small biopsies can heal without suturing. Although closing with sutures improves the cosmetic result, it requires more expertise and time.

### References

- Seia Z., Musso L., Palazzini S., Bertero M. How and Where to Perform a Proper Biopsy. In; Khopkar U. Skin Biopsy – Perspectives, Published by InTech, Croatia. pp:1-18, 2011
- Alguire PC, MD, Mathes BM, Skin biopsy techniques. [https://www.uptodate.com/contents/skin-biopsy-techniques?source=history\\_widget](https://www.uptodate.com/contents/skin-biopsy-techniques?source=history_widget) February 17, 2019
- Pickett H. Shave and punch biopsy for skin lesions. *Am Fam Physician*. 2011;84(9):995-1002.
- Nischal U, Nischal Kc, Khopkar U. Techniques of skin biopsy and practical considerations. *J Cutan Aesthet Surg*. 2008 Jul;1(2):107-11.
- Cheng R, Bialas RW, Chiu ST, Lawrence TJ, Lesesky EB. Punch biopsy vs. shave biopsy: a comparison of margin status of clinically atypical pigmented lesions. *Br J Dermatol*. 2015;173(3):849-51.
- Christenson LJ, Phillips PK, Weaver AL, Otley CC. Primary closure vs second-intention treatment of skin punch biopsy sites: a randomized trial. *Arch Dermatol*. 2005;141(9):1093-1099.
- Alguire PC, Mathes BM. Skin biopsy techniques for the internist. *J Gen Intern Med*. 1998;13(1):46-54.



# 4<sup>th</sup> INDERCOS

## Dermatology and Cosmetology Congress with International Participants

27 - 30 MARCH, 2019  
HILTON ISTANBUL BOSPHORUS HOTEL  
ISTANBUL, TURKEY



### MORPHOLOGICAL AND ETHNIC DIFFERENCES BETWEEN MEN AND WOMEN FOR AESTHETIC PROCEDURES

Alev Bobuş

**Introduction:** Facial aesthetic procedures are popular in recent years. Physicians' wish is to improve facial harmony and beauty. For this purpose several proportions and canons have been described. Bueller (2018) has suggested to take four principal ideas into account to achieve success. These are: (1) classical definitions of beauty as they relate to symmetry, proportion, and youth; (2) achieving a natural and unoperated look for the patient; (3) current cultural trends and ideals; and (4) patient's personal preferences and desires. Here, he implies that the previously defined standards can not be applicable to every patient as the standards of beauty shows ethnic and cultural differences. Besides, many people do not want to lose their ethnic identity when going under some cosmetic and surgical procedures.

In this presentation, it is aimed to give knowledge on anatomic and aesthetic properties and proportions of facial structures like brows, eyelids, eyes, nose (radix, dorsum, nostrils, columella, nasal tip), lips and also on facial angles and canons. Ideal measurements of these structures, and their differential properties in different ethnic groups, like in Asians, Chinese, Caucasians, Europeans, North American Africans, Arabians are mentioned. All these structures have unique features and effects on facial appearance and attractiveness.

**Conclusion:** Al-Sebaei stated that facial norms and measurements of Caucasian populations cannot be applied to the Arab population. Likewise, norms and measurements of any ethnicity can not be applied to any other. Therefore, each individual should be evaluated in terms of his or her cultural norms, besides his own desire.

**Key words:** ideal face, facial proportions, ethnic facial differences, facial angles

#### INTRODUCTION

Physicians or aestheticians need some rules or definitions in planning a surgical or cosmetic procedure to achieve a proportioned and symmetrical face. Renaissance artists and scholars defined vertical and horizontal facial canons for their purpose. Since then many researchers tried to apply these canons to the faces in different ethnic, age and sex groups. Some concluded that these canons can be applicable to the faces, whereas some came to an opposite conclusion. Also many researchers made antropologic and morphometric studies on facial soft tissue structures and compared the measurements among them besides studies on bony structures of the cranium. Besides these, many researches have been done on golden proportion. Some authors believed in golden proportion and some did not. The most followed proportions of the face are dividing the face into three horizontal parts and five vertical parts.

The Horizontal Thirds are described as follows:

The upper third measures from the trichion (the midline point of the hairline) to the glabella.

The middle third measures from the glabella to the subnasale (the midline point where the nasal septum meets the upper lip).

The lower third measures from the subnasale to the menton (the most inferior point of the chin).

The lower third is again divided into two portions that the upper one-third which is measured from the subnasale to the stomion (the midline point of the oral fissure when the lips are closed), and the lower two-thirds measured from the stomion to the menton (5).

The Vertical Fifths are described as follows:



# 4<sup>th</sup> INDERCOS

## Dermatology and Cosmetology Congress with International Participants

27 - 30 MARCH, 2019  
HILTON ISTANBUL BOSPHORUS HOTEL  
ISTANBUL, TURKEY



In the vertical dimension, the neoclassical canon of facial proportions divides the face into equal fifths. The 2 most lateral fifths are measured from the lateral helix of each ear to the exocanthus of each eye. The eye fissure lengths (measured between the endocanthion and exocanthion of each eye) represent one-fifth.

The middle fifth is measured between the medial canthi of both eyes (endocanthion to endocanthion). This distance is equal to the width of the nose, as measured between both alae.

Finally, the width of the mouth represents 1.5-times the width of the nose. These ratios of the vertical fifths apply to both males and females (5).

### DISCUSSION

Although validity of neoclassical canons do not always fit to the faces, there are some beauty standards that shows the facial structures symmetric and proportioned and therefore, more attractive. These are given under each subtitle as below:

#### Eyes

Rejuvenation of the eyes is one of the most popular subject of dermatologists and plastic surgeons. Because they are considered as one of the most attractive facial features in both of the sexes and the most striking signs of age deformities are seen on eyes.

Farkas et al. (2005) reported that in Middle Eastern and Asian groups, the intercanthal and biocular widths were significantly greater than those in North American whites, and eye fissure length was significantly smaller (4).

#### Eyelids

It is known that in Caucasians, the upper lid has a well defined supratarsal crease. It is generally 7 to 10 mm from the palpebral margin. This crease is often lacking in the eastern Asian eyelid. It looks puffier and has more fullness. Mild ptosis is commonly seen and an epicanthal fold is common in Asian eyelid (6).

#### Brows

In literature, the ideal brow shape is described by Westmore as having a medial extent in line vertically with the lateral nasal ala and medial canthus. The lateral end sits on a line drawn from the most lateral point of the ala through the lateral canthus, having medial and lateral ends at the same vertical height, and having an apex immediately above the lateral limbus (14).

There are gender differences in the brow shape and position. It is concluded that, the brow lies over the orbital rim in male and is several millimetres above the rim in female. Also, male tend to have a heavier, and thicker brow, with little arch. Whereas, in female, the eyebrow tends to have a pleasant arch peaking in the lateral third of the eyebrow (13).



# 4<sup>th</sup> INDERCOS

## Dermatology and Cosmetology Congress with International Participants

27 - 30 MARCH, 2019  
HILTON ISTANBUL BOSPHORUS HOTEL  
ISTANBUL, TURKEY



### **Nose**

Cause of the central position and prominence of the nose, it is reported as a most critical aesthetic facial structure. A nose which is in harmony with the other facial structures, enables an appreciated face and vice versa.

The nasofrontal angle affects the shape of the nose & midfacial length in profile view. The nasion is defined as the deepest point of the nasofrontal angle at the intersection of forehead slope and the proximal nasal bridge. The ideal vertical position of the nasion is reported by Sunk et al. to be between the supratarsal fold and the lash line of the upper eyelid. However, the ideal position of the nasion for an Asian nose is to be at the level or lower than the lower margin of the upper eyelid in forward gaze (12).

Radix of the nose is in the area centered around this point extending from the eyebrows down to the intercanthal line (15). According to Mowlavi et al., the ideal Western radix height was at 10 mm anterior to the corneal plane for both men and women. A shallower radix was preferred over a deeper one. A deep radix will create the appearance of a short nose with a dorsal hump. A shallow radix will create a long nose with a poorly defined starting point.

The nasal bridge is defined as the part of the nose between the soft tissue nasion to pronasale. In the study of Shuk et al., Asian nosebridge length is reported to be shorter than the Caucasian norm (between 45 to 50 mm). They also stated that, dorsum of Asian nose tend to be wider and less straight with more concavity at the supraciliary ridge.

The brow-tip aesthetic line is an imaginary line traced from the medial brow down the lateral wall of the nose to the tip defining points. In the female, this line should be slightly wider at the radix, narrow at the middle third and then widen at the tip like a hourglass (8)

Farkas et al reported that the nose width is significantly greater in both the Asian and African groups than in North American whites. But the width is more conspicuous among the Africans because their mandible and face widths were the same as North American whites (4).

Several methods are determined for ideal tip projection. Baum's method is the first, which was calculated by placing a vertical line through the nasofrontal angle to the subnasale and then placing a perpendicular line from subnasale to the nasal tip. This yielded a 2:1 ratio of the vertical to the horizontal line.

The most widely used method is Goode's method, which uses a 3 to 4 or 5 triangle. The first leg of the triangle is from the nasofrontal angle through the alar crease, then a line is drawn perpendicular to this one through the tip-defining point, and, finally, the triangle is completed by a line from the tip-defining point to the nasofrontal angle, along the nasal dorsum. For an ideal shape, the ratio of the projection of the nose from the alar crease to the tip is reported to be equal 0.55 to 0.60 of the nasal dorsal length from the nasion to the nasal tip according to Goode's method.

It is stated that, unlike Caucasians East Asians, tend to have a short, retruded columella, wide and flaring nostrils, a broad and ill-defined nose tip (9)

### **Alar base of the nose**

It has been traditionally accepted that the alar base width ought to equal the intercanthal distance, which also should be equal to one-fifth of the overall facial width. This standard may be too narrow for many faces. It has been noted that multiple non-Caucasian ethnicities typically have a wider alar base than this recommendation.

The alar flare is the maximum degree of alar convexity above the alar crease that ideally should not extend more than 2 mm outside the crease.





# 4<sup>th</sup> INDERCOS

## Dermatology and Cosmetology Congress with International Participants

27 - 30 MARCH, 2019  
HILTON ISTANBUL BOSPHORUS HOTEL  
ISTANBUL, TURKEY



### **Lips**

According to the literature, fullness of the lips is generally considered as an attractive feature for women. Proportionate lip measurements for both women and men contribute to the overall harmony of the face. The golden ratio of approximately 1:1.6 has been considered an ideal ratio for upper to lower lips in terms of attractiveness. Many studies support that lips having proportions very close to this ratio are considered attractive, especially in Caucasian women.

There are some reference lines for the position of lips in literature. These are; Burstone's B line, Steiner's S1 line, Ricketts' E line, Sushner's S2 line, and Holdaway's H line. In the study of Erbay et al., males and females with more protrusive lips were selected as attractive by raters. While, the protrusive lower lip was found attractive in female, protrusive upper lip was found attractive in male (3).

Ricketts E-Plane is drawn from tip of the nose to the chin. The ideal distance between this plane & the lips is reported as upper lip at a distance of 4mm & lower lip at a distance of 2mm (10).

The ideal protrusion of the lips has been reported as the upper lip having a slightly greater protrusion than the lower lip. The upper and lower lips should protrude slightly beyond a line drawn from the subnasale to the pogonion (Burstone line). The upper lip protrudes an average of 3.5 mm beyond this line and the lower lip an average of 2.2 mm.

It is stated that, eastern Asians prefer smaller lips relative to Caucasians, while Hispanics prefer larger lips. African Americans naturally tend to have fuller lips, and they also prefer a fuller, more protrusive lip. Bueller reported that, well-proportioned lips should have a vertical height ratio of 1:1.6 and width 40% of the lower face (2).

### **Facial Profile**

During an angular profile analysis of a patient, the angle of facial convexity (nasion-subnasale-pogonion or glabella-subnasale-pogonion) and angle of total facial convexity (nasion-pronasale-pogonion or glabella-pronasale-pogonion) are commonly measured from the lateral side to assess the balance between the face and nose.

Czarnecki et al concluded that the males with straight profiles and the females with slightly convex profiles were the most pleasant, and those with severely convex profiles and extremely retrusive chins were the least pleasant.

In the study of Park et al., it is reported that, East Asians, unlike Caucasians, tend to have a low dorsal profile, obtuse nasofrontal angle, acute nasolabial angle, and greater forward placement of the upper lip with midface retrusion. In a another study, it is stated that Western subjects tended to have a protruding forehead, while Asians had a retruded midface and less chin prominence (9).

Sforza et al. compared the facial characteristics of two different groups of attractive women with those of reference women. Among the common characteristics was a relatively large forehead (facial upper third), with a relatively reduced mandible (facial lower third), and a rounded face, with a reduced surface to volume ratio. They had a more acute soft tissue profile, an increased upper facial width and middle facial depth, larger mouths, and more voluminous lips, than reference women (11).

Consequently, knowledge of the most striking facial characteristic of ethnic groups is crucial to achieve satisfying aesthetic results. Because, the norms and measurements of any ethnicity can not be applied to any other (1). Therefore, each individual should be evaluated in terms of his or her cultural norms, besides his own desire.



# 4<sup>th</sup> INDERCOS

## Dermatology and Cosmetology Congress with International Participants

27 - 30 MARCH, 2019  
HILTON ISTANBUL BOSPHORUS HOTEL  
ISTANBUL, TURKEY



### REFERENCES

- Al-Sebaei MO. The validity of three neo-classical facial canons in young adults originating from the Arabian Peninsula. *Head & Face Medicine* (2015) 11:4.
- Bueller H. Ideal Facial Relationships and Goals. *Facial Plast Surg* 2018;34:458–465.
- Erbay EF, Caniklioglu CM. Soft tissue profile in Anatolian Turkish adults: Part II. Comparison of different soft tissue analyses in the evaluation of beauty. *Am J Orthod Dentofacial Orthop* 2002;121:65-72.
- Farkas LG, Katic MJ, Forrest R. International Anthropometric Study of Facial Morphology in Various Ethnic Groups/Races. *Journal of Craniofacial Surgery*. August 2005. DOI: 10.1097/01.scs.0000171847.58031.9e
- Hashim PW, Nia JK, Talierno M, Goldenberg G. Ideals of Facial Beauty. *Cutis*. 2017;100:222-224
- Kiranantawat, K, Suhk JH, Nguyen, AH. The Asian Eyelid: Relevant Anatomy. *Semin Plast Surg* 2015;29:158–164
- Le TT, Farkas LG, Ngim RCK, Levin LS, Forrest CR. Proportionality in Asian and North American Caucasian Faces Using Neoclassical Facial Canons as Criteria. *Aesth. Plast. Surg.* 26:64–69, 2002. DOI: 10.1007/s00266-001-0033-7
- Park CW, Lee MY, Jung YI. Photogrammetric Facial Analysis of Attractive Celebrities Using the Glabella for Planning Rhinoplasty and Analyzing Surgical Outcomes. *Arch Aesthetic Plast Surg* 2018;24(3):105-110
- Park SS. Fundamental Principles in Aesthetic Rhinoplasty. *Clinical and Experimental Otorhinolaryngology* Vol. 4, No. 2: 55-66, June 2011.
- Patnaik, V.V.G; Singla Rajan, K; Bala Sanju. Anatomy of 'A Beautiful Face & Smile. *J Anat. Soc. India* 52(1) 74-80 (2003)
- Sforza C; Lainob A; D'Alessio R; Grandid G; Binellid M; Ferruccio V. Ferrario. Soft-Tissue Facial Characteristics of Attractive Italian Women as Compared to Normal Women.
- Suhk JH, Park JS, Nguyen AH. Nasal Analysis and Anatomy: Anthropometric Proportional Assessment in Asians—Aesthetic Balance from Forehead to Chin, Part I. *Semin Plast Surg* 2015;29:219–225.
- Tan KS, Oh S-R, Priel A, Korn BS, Kikkawa DO. Surgical Anatomy of the Forehead, Eyelids, and Midface for the Aesthetic Surgeon. G.G. Massry et al. (eds.), *Master Techniques in Blepharoplasty and Periorbital Rejuvenation*, 11. DOI 10.1007/978-1-4614-0067-7\_2.
- Yalcinkaya E, Cingi C, Soken H, Ulusoy S, Bayar Muluk N. Aesthetic analysis of the ideal eyebrow shape and position. *Eur Arch Otorhinolaryngol* (2016) 273:305–310
- Yas NK. Anthropometric study on the nasofrontal angle in human skulls. *J Fac Med Baghdad* 107 Vol.54, No.1, 2012.



# 4<sup>th</sup> INDERCOS

## Dermatology and Cosmetology Congress with International Participants

27 - 30 MARCH, 2019  
HILTON ISTANBUL BOSPHORUS HOTEL  
ISTANBUL, TURKEY



### GUIDELINES OF CHEMICAL PEEL

**Ivana Binic**

Chemical peeling is a popular, relatively inexpensive, and generally safe method for treatment of some skin disorders and to refresh and rejuvenate skin. It is used to create an injury of a specific skin depth with the goal of stimulating new skin growth and improving surface texture and appearance. This results in epidermal regeneration and postinflammatory collagen neof ormation with remodeling of collagen and elastic fibers and deposition of glycosaminoglycans in the dermis, with more evenly distributed melanin. Chemical peels are classified according to their depth of penetration of the skin into superficial, medium-depth and deep subtypes. The depth of penetration is determined by the concentration, pH and type of peeling agent used. Anatomical location, epidermal integrity, adnexal structure density and skin thickness also influence the depth of the peel. Other important considerations include cutaneous priming, application technique, occlusion and contact time. The depth of the peel is correlated with clinical changes, with the greatest change achieved by deep peels. However, the depth is also associated with longer healing times and the potential for complications. A wide variety of peels are available, utilizing various topical agents and concentrations, including a recent salicylic acid derivative,  $\beta$ -lipohydroxy acid, which has properties that may expand the clinical use of peels.

Superficial peels, penetrating only the epidermis, can be used to enhance treatment for a variety of conditions, including acne, melasma, dyschromias, photodamage, and actinic keratoses. Medium-depth peels, penetrating to the papillary dermis, may be used for dyschromia, multiple solar keratoses, superficial scars, and pigmentary disorders. Deep peels, affecting reticular dermis, may be used for severe photoaging, deep wrinkles, or scars.

Contraindications include patients with active bacterial, viral or fungal infection, tendency to keloid formation, facial dermatitis, taking photosensitizing medications and patients with unrealistic expectations. Peels can be combined with other in-office facial resurfacing techniques to optimize outcomes and enhance patient satisfaction and allow clinicians to tailor the treatment to individual patient needs. Chemical peeling is a common office procedure that has evolved over the years, using the scientific knowledge of wound healing after controlled chemical skin injury. In spite of the advent of newer techniques and lasers, peeling has stood the test of time as a simple procedure, requiring hardly any instrumentation to rejuvenate the skin. Successful outcomes are based on a careful patient selection as well as appropriate use of specific peeling agents. Used properly, the chemical peel has the potential to fill an important therapeutic need in the dermatologist's armamentarium.



# 4<sup>th</sup> INDERCOS

## Dermatology and Cosmetology Congress with International Participants

27 - 30 MARCH, 2019  
HILTON ISTANBUL BOSPHORUS HOTEL  
ISTANBUL, TURKEY



### **COSMETICAL PROCEDURES IN CONNECTIVE TISSUE DISORDERS**

**Hilal Gökalp**

Patients with connective tissue disorders (CTDs) commonly present with significant concerns about changing facial features. Lupus erythematosus, morphea, en coup de sabre, scleroderma, dermatomyositis are all disfiguring connective tissue disorders, and as of today there is not enough information to determine whether or not cosmetic intervention would be appropriate for these patients. Nevertheless, it has been shown that permanent fillers such as silicone should be avoided, since connective tissue disorders has been reported to occur following injection of paraffin and silicone. It is also shown that calcium hydroxyapatite, methacrylate, acrylamides, and polyalkylimide provoke notable chronic activation of the immune system. Mesotherapy and non-surgical thread lift are also should not be used in CTDs.

On the other hand, botulinum toxins, fillers, lasers, light systems, platelet-enriched plasma (PRP), autologous fat transplantation have been successfully used to correct tissue during inactive period of connective tissue disorders. Several techniques have been shown to be effective in limited case studies. Connective tissue disorders are characterized with inflammation caused by autoantibodies that incorrectly damage against its own tissues. Hence, evaluation of serum levels of acute phase reactants may be a sensitive marker of CTDs activity which may be helpful in maintaining or withdrawing cosmetical procedures in patients with CTDs.

Despite low-level of evidence, cosmetic procedures may have beneficial effect in patients with CTDs and, complete investigation and the patient selection are essential. Clinicians must also be experienced to ensure the appropriate procedure, product, and technique. However, long term and larger studies are needed.





# 4<sup>th</sup> INDERCOS

## Dermatology and Cosmetology Congress with International Participants

27 - 30 MARCH, 2019  
HILTON ISTANBUL BOSPHORUS HOTEL  
ISTANBUL, TURKEY



### HAIR LOSS IN ELDERLY WOMEN

Tugba Özkök Akbulut

Hair loss in elderly women has a special appearance due to aging of the hair follicles, hormonal changes, various diseases and therapeutic considerations. Hair growth and pigmentation in the hair follicle aging process is affected, but the underlying molecular mechanism has not been clarified yet. Different forms of scarring alopecia and non-scarring alopecia can coexist. Androgenetic alopecia is a common form of hair loss, especially in older women, and usually worsen after menopause. Finasteride, which is among the options that can be used in the treatment of androgenetic alopecia, requires high doses and long periods of time to be effective. Androgenic tumors should be considered when there is virilization findings with a sudden exacerbation of hair loss. Primary chronic telogen effluvium is a diagnosis of exclusion. Secondary chronic telogen effluvium has been observed more frequently in senile women with thyroid diseases, deep iron deficiency anemia, chronic liver or kidney diseases, malignancy and malnutrition. Common drugs that promote telogen effluvium in older women may include anticoagulants, interferons, and psychotropic drugs, but it is often difficult to establish a precise link between drug intake and hair loss. Trichotillomania in older age groups is associated with more psychopathology such as depression, anxiety disorder, obsessive-compulsive disorder, panic attack and psychosis. The dominance of adult tinea capitis in postmenopausal women was confirmed in an epidemiological study. Frontal fibrosing alopecia, giant cell arthritis and erosive pustular dermatosis are among the causes of cicatricial alopecia mainly seen in older women. Drug-induced alopecia is usually described as a diffuse non-scarring alopecia which is reversible upon withdrawal of the drug. However cicatricial alopecia can be seen in older women with the use of some drugs. Alopecia associated with epidermal growth factor receptor inhibitors may show progressive progression and may be scarring. The use of long-term hormone replacement therapy may affect the onset and exacerbation of both systemic and discoid lupus erythematosus. Rarely seen alopecia neoplastica caused by metastatic cancers, should be kept in mind in women with breast cancer. As a result, hair loss in postmenopausal women is usually multifactorial and requires a close examination.

#### References:

- Camacho-Martinez FM. Hair loss in women. *Semin Cutan Med Surg* 2009; 28: 19-32.
- de Berker DAR, Messenger AG, Sinclair RD. Disorders of hair. In: Burns DA, Breathnach SM, Cox N, Griffiths CE, eds. *Rook's textbook of dermatology*. London, England: Blackwell Science, 2004: 63.31-63.36.
- Kossard S, Lee MS, Wilkinson B. Postmenopausal frontal fibrosing alopecia: a frontal variant of lichen planopilaris. *J Am Acad Dermatol* 1997; 36: 59-66.
- Prohic A. An epidemiological survey of tinea capitis in Sarajevo, Bosnia and Herzegovina over a 10-year period. *Mycoses* 2008; 51: 161-4.
- Chen W, Yang CC, Todorova A, et al. Hair loss in elderly women. *Eur J Dermatol*. 2010;20:145-151.
- Ablon G, Dayan S. A Randomized, Double-blind, Placebo-controlled, Multicenter, Extension Trial Evaluating the Efficacy of a New Oral Supplement in Women with Self-perceived Thinning Hair. *J Clin Aesthet Dermatol*. 2015;8(12):15-21.



# 4<sup>th</sup> INDERCOS

## Dermatology and Cosmetology Congress with International Participants

27 - 30 MARCH, 2019  
HILTON ISTANBUL BOSPHORUS HOTEL  
ISTANBUL, TURKEY



### ESTRADIOL/PROGESTERONE RELATED SKIN DISEASES

Filiz Topaloğlu Demir

**INTRODUCTION:** Estradiol and progesterone related skin diseases are much less defined and studied as compared to androgen mediated skin diseases. The association is mainly based on clinical observations and the pathogenesis remains unclarified. The best characterized example is autoimmune progesterone dermatitis, with diverse cyclical manifestations including generalized pruritus, urticaria, eczema, stomatitis, papulovesicular eruption, fixed drug eruption, bullous eruption, erythema multiforme, to anaphylaxis 1-3. Explicit are the pregnancy-specific dermatoses, especially pemphigoid gestationi, polymorphous eruption of pregnancy (PUPPP) and intrahepatic cholestasis of pregnancy, which occur exclusively during pregnancy, pustular psoriasis of pregnancy (impetigo herpetiformis), atopic eruption/atopiform dermatitis of pregnancy, erythema nodosum gravidarum, and rosacea fulminans are easily inducible in predisposed women in pregnancy. Autoimmune collagen vascular diseases such as lupus are the classical female dominant diseases most commonly seen in women of childbearing age with unclear hormonal pathogenesis.

Autoimmune progesterone dermatitis Autoimmune progesterone dermatitis is a rare disorder characterized by recurrent cutaneous or mucocutaneous manifestations during the luteal phase of the menstrual cycle as a cyclic premenstrual reaction to progesterone production.<sup>1</sup> The exact pathogenesis of autoimmune progesterone dermatitis is not completely understood and multiple hypotheses have been proposed: I. Stimulation of T-helper cells related to progesterone therapy II. Intolerance to high levels of progesterone being in pregnancy III. Cross-sensitivity to other steroids IV. High expression of progesterone receptors V. Type I hypersensitivity or Type IV hypersensitivity<sup>1,2</sup>. The clinical features of autoimmune progesterone dermatitis vary widely and thus, its diagnosis is challenging. Hives, erythema multiforme, angioedema, eczema-like rash, annular erythema, anaphylaxis and mouth sores are the cutaneous and mucocutaneous findings associated with autoimmune progesterone dermatitis<sup>3,4</sup>. Because of this polymorphic characteristics, it can easily misdiagnosed. It usually occurs during the second half of the cycle when progesterone levels start to rise and improves after menstruation when the progesterone levels naturally fall. The lesions severity varies depending on the phase of the menstrual cycle. The diagnostic criteria of APD proposed by Warin et al. include: I. Skin lesions relevant to menstrual cycle, II. Symptomatic improvement by inhibiting ovulation, III. Positive intradermal progesterone provocation test.<sup>5</sup> However, there is no standardization in the application of the test, neither regarding the dose, nor the technique to use. Eosinophil count, quantitative measurements of immunoglobulin, complement, luteinizing hormone, progesterone, and estradiol are the other diagnostic tests suggested.

There is also no standardization in the treatment of autoimmune progesterone dermatitis but suppressing ovulation is the main target. If there is exogenous progesterone intake, first it should be stopped. Combined oral contraceptive pills (OCPs) are the first choice among treatment options. Tamoxifen (anti-estrogen) and danazol (increased progesterone clearance) are the other alternative treatments that can be used to avoid side effects of OCPs.<sup>7</sup> Variable results have been reported with the use of systemic corticoids and antihistamines.<sup>8</sup> Another option in the treatment is gonadotropin-releasing hormone (GnRH) analogs. The use of GnRH analogs (such as goserelin, busorelin) decreases the secretion of follicular stimulating hormone and luteinizing hormone along with endogenous GnRH release<sup>3</sup>. In resistant cases, hysterectomy and bilateral salpingo-oophorectomy should be kept in mind.<sup>8</sup> Estrogen hypersensitivity Estrogen hypersensitivity appears to be even rarer than autoimmune progesterone dermatitis.<sup>9-11</sup> It occurs as a premenstrual exacerbation of urticaria or as a delayed



# 4<sup>th</sup> INDERCOS

## Dermatology and Cosmetology Congress with International Participants

27 - 30 MARCH, 2019  
HILTON ISTANBUL BOSPHORUS HOTEL  
ISTANBUL, TURKEY



type dermatitis.<sup>9</sup> Estrogen levels, however, peak earlier than in progesterone, in the menstrual cycle (ie, 6 to 14 days), but there is a secondary increase in the luteal phase reflecting the increase in progesterone. In the diagnosis, an intracutaneous estrogen test or an estrogen challenge has been using.<sup>9-11</sup> Treatments include suppression of estrogen with tamoxifen, leuprolide acetate, contraceptives containing only progestin, or oophorectomy.<sup>9-12</sup> Pemphigoid Gestationis The disease course of pemphigoid gestationis (PG) is associated with the changes in hormone levels of estrogen and progesterone. In addition to its relationship with pregnancy, PG has been reported to exacerbate after administration of oral contraceptives and during menstruation.<sup>13,14</sup> The progesterone level goes up in the last few weeks of pregnancy and suppresses antibody production while estrogen increases.<sup>15</sup> This may explain why PG usually develops just before birth, but is usually characterized by postpartum glare as progesterone levels decrease. Systemic lupus erythematosus (SLE) The biggest risk factor in the development of SLE is being female. Sex hormones contribute to this gender bias in SLE, but the relevant mechanisms are not fully described. It has been hypothesized that estradiol alters signaling pathways in activated SLE T cells that control T cell function. Differential expression of transcriptional coactivators could effect estrogen-dependent gene regulation in T cell signaling and contribute to SLE onset and disease pathogenesis.<sup>16</sup> It was shown that estradiol affected the calcium signaling pathway in SLE T cells.<sup>16</sup> Calreticulin is a major calcium buffering protein in the endoplasmic reticulum. It was reported that its expression in normal human T cells was tightly regulated by estradiol. The lack of this tight regulation in SLE T cells could contribute to abnormal T cell function.<sup>17</sup>

### References

- 1) Herzberg AJ, Strohmeyer CR, Cirillo-Hyland VA. Autoimmune progesterone dermatitis. *J Am Acad Dermatol*. 1995;32:333–338.
- 2) Apurwa A, Patil S, Chaudhari P, Nadkarni NJ. Autoimmune Progesterone Dermatitis Indian *J Dermatol*. 2018 Mar-Apr; 63(2): 188–190.
- 3) George R, Badawy SZ. Autoimmune progesterone dermatitis: a case report. *Case Rep Obstet Gynecol*. 2012;2012:757854.
- 4) Michael Schatz, MD, MS. Recognition and management of allergic disease during pregnancy. *UpToDate*. February 2015.
- 5) Warin AP. Case 2. Diagnosis: erythema multiforme as a presentation of autoimmune progesterone dermatitis. *Clin Exp Dermatol*. 2001;26:107–108.
- 6) Tegan Nguyen, A. Razzaque Ahmed. Autoimmune progesterone dermatitis: Update and insights. *Autoimmunity Reviews*. 2/2016; 15(2):191-197.
- 7) Nguyen T, Razzaque Ahmed A. Autoimmune progesterone dermatitis: Update and insights. *Autoimmun Rev*. 2016;15:191–197.
- 8) Prieto-Garcia A, Sloane DE, Gargiulo AR, Feldweg AM, Castells M. Autoimmune progesterone dermatitis: clinical presentation and management with progesterone desensitization for successful in vitro fertilization. *Fertil Steril*. 2011;95:1121.e9–1121.13.
- 9) Shelley WB, Shelley ED, Talanin NY, Santoso-Pham J. Estrogen dermatitis. *J Am Acad Dermatol* 1995; 32:25.
- 10) Leylek OA, Unlü S, Öztürkcan S, et al. Estrogen dermatitis. *Eur J Obstet Gynecol Reprod Biol* 1997; 72:97.
- 11) Mayou SC, Charles-Holmes R, Kenney A, Black MM. A premenstrual urticarial eruption treated with bilateral oophorectomy and hysterectomy. *Clin Exp Dermatol* 1988; 13:114.
- 12) Yoon TY, Kim YG, Kim MK. Estrogen dermatitis responding to leuprolide acetate. *J Dermatol* 2005; 32:405.
- 13) Shornick JK. Herpes gestationis. *J Am Acad Dermatol* 1987;17:539–56.
- 14) Semkova K, Black M. Pemphigoid gestationis: current insights into pathogenesis and treatment. *Eur J Obstet Gynecol Reprod Biol* 2009;145:138–44.
- 15) Da Silva JAP. Sex hormones and glucocorticoids: Interactions with the immune system. *Ann NY Acad Sci*. 1999;876:102–17.
- 16) Walters E, Rider V, Abdou NI, et al. Estradiol targets T cell signaling pathways in human systemic lupus. *Clin Immunol*. 2009;133:428–436.
- 17) Walters E, Rider V, Abdou NI, et al. Estradiol Differentially Regulates Calreticulin: A Potential Link with Abnormal T Cell Function in Systemic Lupus Erythematosus? *Lupus*. 2013 May; 22(6): 583–596.



# 4<sup>th</sup> INDERCOS

## Dermatology and Cosmetology Congress with International Participants

27 - 30 MARCH, 2019  
HILTON ISTANBUL BOSPHORUS HOTEL  
ISTANBUL, TURKEY



### **SILVER, GLIZIGIEN AND GLUTATHIONE TREATMENT IN DERMATOLOGY**

**Yeşim Akpınar Kara**

The use of silver in treatment has a very long tradition. Around 1920, colloidal silver was approved for wound treatment by the FDA . In 1968, silver sulfadiazine was introduced into clinical practice, and continued to be in topical antimicrobial treatment, especially in the management of burn injuries. Silver can prevent bacterial infection and silver ions have been proven to be effective against many bacteria, fungi, and viruses. Silver nanoparticles (Ag-NPs) have proinflammatory activities and can augment the antimicrobial activities of reactive oxygen species. Silver-containing wound dressings play a key role in modern wound management concepts. In biofilms, silver ions reduce bacterial adhesion and destabilize the biofilm matrix, thus increasing the sensitivity of bacteria. 40% silver nitrate aqueous solution and silver nitrate paste is also use to treat cutaneous lesions of Molluscum Contagiosum with antiviral effect except wound healing. Topical silver and other nanoparticles complexed suppress inflammation in plaques psoriasis.

#### **GLIZIGIEN (GLYCYRRHIZINIC ACID)**

Glycyrrhizin (GL) is isolated from the licorice plant (*Glycyrrhiza glabra*). GL has been used as a traditional Chinese medicine for many centuries to treat allergic disease. In 1946, Revers reported the anti-ulcer effects of licorice . Since then, GL has been used as an anti-ulcer drug in Europe. Glycyrrhizin and its derivatives have been used recently to treat inflammatory skin diseases . *Glycyrrhiza glabra* and its components has inhibitory effects on inflammatory and allergic reactions. GL and other related compounds are proven to have multiple pharmacological activities, such as immunomodulatory, anti-allergy, anti-inflammation, anti-ulcer, anti-viral, anti-carcinogen, and anti-hepatitis properties. It has been used clinical application in treating atopic dermatitis , eczema, vitiligo, psoriasis, alopecia areata, systemic sclerosis, keloid and anogenital warts.

#### **GLUTATHIONE**

Glutathione is a antioxidant which physiologically plays a role in maintaining homeostasis through redox balance and providing protection against oxidative stress. Glutathione is a natural organic molecule with extensive biological activity. Glutathione confers protection against microbial infections and can diminish the virulence of pathogens antimicrobials. Glutathione, being a strong antioxidant with additional anti-melanogenic properties, has recently become the most popular systemic skin lightening molecule and it as a "wonder" drug for skin lightening and treatment of hyperpigmentation.





# 4<sup>th</sup> INDERCOS

## Dermatology and Cosmetology Congress with International Participants

27 - 30 MARCH, 2019  
HILTON ISTANBUL BOSPHORUS HOTEL  
ISTANBUL, TURKEY



### POLYAMINE METABOLISM CHANGES IN DERMATOLOGY

**Valentina Broshtilova**

Polyamines – putrescine, spermidine and spermine are polycationic compounds ubiquitous for all living organisms. They are essential for cell growth and differentiation, cell cycle progress control, apoptosis, and cancer induction. Elevation of cellular polyamine content triggers the transcription of c-myc and c-fos, suggesting participation of proto-oncogene expression in polyamine-mediated control of cellular proliferation in studies on cell cultures. Accumulated scientific evidence suggests the central role of polyamines in the processes of keratinocytic proliferation, differentiation, and regulation. Skin samples from benign (psoriasis) and neoplastic (basal and squamous cell carcinoma lesions) keratinocytic proliferations are analyzed on the content of basic biogenic polyamines. An original, innovative chromatographic method was used to detect the levels of putrescine, spermidine, and spermine in all skin samples. The scientifically proven results showed different concentration and proliferation trends emphasizing the importance of propylamine synthesis in the pathogenesis of psoriasis and enhancement of putrescine synthesis in neoplastic proliferations. The leading role of adenosine methionine decarboxylase (AMDC) in the pathogenesis of benign keratinocytic proliferations and of ornithine decarboxylase in squamous cell carcinoma have been proven, rising opportunities for future therapeutic approaches.

**Key words:** *biogenic polyamines, benign and malignant keratinocytic proliferations*



# 4<sup>th</sup> INDERCOS

## Dermatology and Cosmetology Congress with International Participants

27 - 30 MARCH, 2019  
HILTON ISTANBUL BOSPHORUS HOTEL  
ISTANBUL, TURKEY



### POSSIBILITIES AND PROSPECTS FOR ACUPUNCTURE IN DERMATOLOGY

**Valentina Broshtilova**

The growing popularity of complementary and alternative medicine highlights the importance of integrating these unconventional treatment approaches in the traditional up-to-date medical principles with the presumption of gaining control on chronic retractable conditions. Traditional Chinese Medicine (TCM) includes two mainstream treatments: 1. methods of external irritation (Wai Zhi), which include acupuncture, moxibustion, cupping therapy, Qi Gong as well as Tai Chi Quan gymnastics, and 2. methods of internal treatment such as nutrition, herb therapy, suggestive-magic exercises and autosuggestion. Acupuncture is extremely popular in alleviating pain, itch and inflammation as well as to prevent some severe adverse drug reactions. Dermatologists should be acquainted with the basic TCM principles and their implication in the treatment of various skin diseases. A short review of literature and some own observations on treatment of psoriasis, alopecia, morphea and vitiligo will be presented.

**Key words:** *acupuncture, skin diseases*



# 4<sup>th</sup> INDERCOS

## Dermatology and Cosmetology Congress with International Participants

27 - 30 MARCH, 2019  
HILTON ISTANBUL BOSPHORUS HOTEL  
ISTANBUL, TURKEY



### AYURVEDA, CUPPING THERAPY, MOXIBUSTION AND HIRUDOTHERAPY FOR SKIN DISEASES

**Habibullah Aktaş**

**Ayurveda** is an ancient treatment method originated thousands of years ago in India. It means the science of life in Sanskrit language. It basically depends on the prevention of diseases. There is a strict balance between mind, body and spirit of human being according to theory of ayurveda. Ayurvedic medicine contains a number of practices and products which are prepared for each patient himself/herself by ayurvedic experts (1).

Ayurveda includes several techniques to assess health. The practitioner evaluates the main symptoms of the disease, concentrating the origin and cause of the imbalance. The practitioner can reach the diagnosis as well as observation and physical examination. The question is what breaks down the balance. So the aim is to restore the balance between nature and human body with various life style changes, cleansing modalities and ayurvedic herbs (2).

There are small studies and case reports that a number of skin problems including eczema, psoriasis, autoimmune bullous disease, diabetic foot, reiter syndrome, molluscum contagiosum, erythroderma, photoaging, melasma, lichen planus and skin cancer has got benefit from ayurvedic medicine (3).

**Cupping therapy** is a sort of vacuum therapy increasing blood flow to the skin area on which rounded inverted cups attached. It was originated in China at ancient times, and still has popularity nowadays. Cupping therapy is widely used in many disorders, especially in musculoskeletal system diseases (4).

There are two types of cupping therapy: Dry and wet. Dry cupping only is only to put vacuum making glasses in the diseased area. Wet cupping involves scarification and collection of blood into the containers. It is believed that pathological product passes to this being sucked blood, then wasted (5).

There are numerous studies showing the effect of cupping therapy in various disorders many of them from China. Except musculoskeletal system diseases, evidences in other indications seem poor in regard to effect of cupping therapy.

**Moxibustion** is a warming therapy using aromatic plant, mugwort, on disordered area of the body. This basically depends on heat, but it is believed in that heat created by burning of mugwort has unique properties from other heating sources. It penetrates skin and access inside body, increase blood perfusion, then stimulates immunity (6).

There is a number of case reports about efficacy of moxibustion in several skin diseases again mostly from China.

Moxibustion has some adverse effects including allergies, burns, infection, coughing, nausea, vomiting, fetal distress, premature birth, basal cell carcinoma, ectropion, hyperpigmentation, and even death, despite generally accepted as safe (7)

**Hirudotherapy** is the use of leeches in the medicine. Medicinal leeches cause mainly anticoagulation in the body during blood sucking through the enzymes they carry in their mouths. In addition to anticoagulation, leech saline has many other properties such as antiinflammatory, immunomodulation and analgesic etc.



# 4<sup>th</sup> INDERCOS

## Dermatology and Cosmetology Congress with International Participants

27 - 30 MARCH, 2019  
HILTON ISTANBUL BOSPHORUS HOTEL  
ISTANBUL, TURKEY



Treatment is that one or more leeches are placed over the skin, generally just or close to the problematic area for some time. Active enzymes pass into the host circulation during the feeding of leech (8).

FDA approved medicinal leech treatment in flap salvage surgery but not only other indications. There are several case reports in which leech therapy has been found to be effective. Leech therapy has countless adverse effects from simple contact dermatitis to acute coronary syndrome to sepsis (9-10).

### References

- Thakar A. Ayurveda research: The present status and prospects. *Ayu*. 2018 ;39 (1):1
- Rao RV. Ayurveda and the science of aging. *J Ayurveda Integr Med*. 2018;9 (3):225-32
- Balkrishna A, Misra L. Ayurvedic Opportunities for Restoration of Skin Health. *Int J of Trad and Nat Med*, 2018; 8(1): 23-75
- Lowe DT et al. Cupping therapy: An analysis of the effects of suction on skin and the possible influence on human health. *Complement Ther Clin Pract*. 2017;29:162-68
- Soliman Y, Hamed N, Khachemoune A. Cupping in dermatology: a critical review and update. *Acta Dermatovenerol Alp Pannonica Adriat*. 2018 ;27(2):103-107.
- Huang C, Liang J, Han L, Liu J, Yu M, Zhao B. Moxibustion in Early Chinese Medicine and Its Relation to the Origin of Meridians: A Study on the Unearthed Literatures. *Evid Based Complement Alternat Med*. 2017;2017:8242136.
- Xu J, Deng H, Shen X. Safety of moxibustion: a systematic review of case reports. *Evid Based Complement Alternat Med*. 2014;2014:783704.
- Sig AK, Guney M, Uskudar Guclu A, Ozmen E. Medicinal leech therapy-an overall perspective. *Integr Med Res*. 2017 ;6(4):337-43
- Ahmed T, Anwar M. Clinical importance of leech therapy. *Indian Journal of Traditional knowledge*. 2009;8(3):443-45
- Çakmak T, Çaltekin İ, Gökçen E, Savrun A, Yaşar E. Kounis syndrome due to hirudotherapy (leech therapy) in emergency department; a case report. *Turk J Emerg Med*. 2018;18(2):85-87





# 4<sup>th</sup> INDERCOS

## Dermatology and Cosmetology Congress with International Participants

27 - 30 MARCH, 2019  
HILTON ISTANBUL BOSPHORUS HOTEL  
ISTANBUL, TURKEY



### **A NOVEL APPROACH AND STRATEGY TO THE TREATMENT OF MELASMA**

**Milanka Ljubenovic**

Melasma is an acquired disorder of pigmentation that is presented with symmetrical gray-brown patches, especially on the face, but also in other UV exposed regions. It is more common in women, and is called chloasma when it occurs during pregnancy.

The pathogenesis of melasma is not sufficiently clarified. It is a multifactorial disorder, with the role of female sex hormones, genetic predisposition, inflammatory processes of the skin, use of photosensitizing drugs and exposure to UV radiation.

Treatment of melasma remains challenging, due to frequent relapses, as well as the occurrence of postinflammatory hyperpigmentation, which occurs after a certain treatment procedures.

Goals of treatment are inhibition of the synthesis and transport of melanin on the one hand, and the removal of already present pigmented lesions on the other hand. Topical formulas with or without hydroquinone for bleaching, chemical peels, and various types of lasers are common modalities in the treatment of melasma.

Newer treatment options for the treatment of melasma include tranexamic acid, antiestrogens (tamoxifen and aromatase inhibitors), silymarin and an inhibitor of vascular endothelial growth factor. Integrative approach for melasma insist on minimally invasive treatments such as botanical medicines, lifestyle modifications, and dietary supplements.



# 4<sup>th</sup> INDERCOS

## Dermatology and Cosmetology Congress with International Participants

27 - 30 MARCH, 2019  
HILTON ISTANBUL BOSPHORUS HOTEL  
ISTANBUL, TURKEY



### ANTIVIRAL HERBS; BOTANICAL PROTECTION AGAINST VIRUSES

Ahmet Metin

Table I: Antiviral plants for human cutaneous viral infections

Viral infections caused by obligative intracellular parasite viruses are very important part among acute infectious diseases of human beings. Most of the viral infections are treated symptomatically and some of them have with high incidence high morbidity rates, and still the leading cause of death in humans worldwide. When confronted by illness and poor health, human beings have always sought medicines from the natural world, mostly from plants. Herbal products are used in the treatment of viral infections. In the recent past many modern synthetic drugs that replaced the life-saving many herbal remedies. There are many kinds of antiviral drugs, such as nucleosides analogues, biological agents (interferon, IFN), enzyme preparation. Among the available antiviral therapeutic modalities, the majority is nonspecific for particular viruses.

Table II: Antiviral plants for human systemic viral infections

Along with the wide clinical application of antiviral chemicals, the problems are serious increasingly, which mainly focus on drug resistance and side effects. Moreover, the emergence of viral resistance to drugs, as well as the serious adverse effects induced by antiviral drugs, has caused serious medical problems, particularly when administered within combination over prolonged treatment periods. And these drugs are quite costly, thus limiting their use in many developing countries, where infection is most prevalent. The clinical use of vaccines may cause itself viral diseases, so there still were no effective specific preventive measures for many of them.

As a result effective drug were rare and the antiviral species limited. Combined with viruses mutations which occurs

Table II: Antiviral plants for human systemic viral infections (continued)

Easily, even if the new medicine with a single structure was born, its life is very short. The development of novel cost-effective and specific antiviral regimens is the prime focus of the current medical research. A variety of herbal medicines associated with treatment of skin and systemic viral diseases have been used as therapeutic alternatives for a long time (Table I, II).

Studies have shown that various medicinal plants have a tremendous antiviral effect at various stages of viral growth (Table III). Pharmacological formulations and investigations associated with the plant are now highly ranked for viral infections. Globally, 80% of patients with viral diseases receive herbal medicines. Analysis of prescriptions in the United States showed that 41% of prescriptions contained one or more products of natural origin as therapeutic agents, and 25% of the 200 most commonly prescribed drugs are of natural origin. The global value of the plant-derived antiviral products is increasing constantly due to its effectiveness and few or no side effects. The Herbal Medicine Market is expected to reach \$ 111 billion



# 4<sup>th</sup> INDERCOS

## Dermatology and Cosmetology Congress with International Participants

27 - 30 MARCH, 2019  
HILTON ISTANBUL BOSPHORUS HOTEL  
ISTANBUL, TURKEY



by the end of 2023.

The tremendous increase in the shift of consumers towards the traditional medicine such as Ayurveda, Homeopathy, Unani, Traditional Chinese medicine has led to the increase in the market value as they are low cost, affordable than compared to allopathy. In addition to this increase in the research and funding will help for the growth of the market in the near future.

**Table III:** Some antiviral effects herbal.

The antiviral herbs showed great advantage in the areas of antivirus. Many herbal remedies individually or in combination with different formulations such as leaf powder, pastes, decoctions, infusions, and pills have been recommended in various medical treatises. They have not fully understood multi-component and multi-target (antiviral, antipyretic, anti-inflammatory, antioxidant) way to exert their pharmacological curative effects is the distinctive features of its antiviral mechanism even in resisting viral infections (Table III). Moreover, some herbals can also enhance the immune function against to viruses. They are highly targeted without damaging the surrounding tissues. The active ingredients of herbal plants are generally multicultural, so it is hard for virus to produce drug resistance. Because of all these reasons the novel bioactive compounds bearing remarkable therapeutic potential against viral diseases are direly needed to be explored from nature. Despite the development of new antiviral agents from other sources, medical plants continue to provide essential raw materials for some of the most important antiviral drugs. Various medicinal plant extracts are at an early stage of investigation, and some have reached the clinical trial. The lack of experimental and scientific evidence about effective constituents, efficacy, effectiveness, and pharmacokinetics resulted in belief to safety, quality, and effectiveness of the traditional medicine.

There is need to standardize the herbal preparations for their efficacy, safety, and quality. This requires isolation of active principles; biological testing of plant extracts; and pharmacodynamical, clinical, and, ultimately, toxicological studies. Medicinal preparations are made from the plant extract and considered to be effective as a whole instead of as a single constituent; standardization process is difficult. Furthermore, loss of activity may be possible due to antagonisms of active principles with extract. Survival of any plant-based technology needs standardization. It is a remarkable effort to isolate active principles from plants with a confirmed antiviral activity that leads to explore their mechanism of action and, lastly, to develop a conventional dosage form design that not only controls viral infections but also reduces the associated complications.

### CONCLUSIONS

Viral infection is a public health problem affecting the large population of the world. Plants are therapeutically effective in viral disease; however, it would be unwarranted to declare that all these plants can be blindly prescribed in patients with viral infections.

Therefore, it is required to establish and validate all the assessment parameters. The exploration of the plant-based bioactive compounds may significantly contribute to the validation of plant characteristics. Medicinal plants are extremely esteemed for millennia as a rich source of therapeutic agents for the management of viral disorders. Although the contribution of modern synthetic medicine for elevating human sufferings cannot be underestimated; however, the fact that synthetic drugs exert serious side



# 4<sup>th</sup> INDERCOS

## Dermatology and Cosmetology Congress with International Participants

27 - 30 MARCH, 2019  
HILTON ISTANBUL BOSPHORUS HOTEL  
ISTANBUL, TURKEY



effects cannot be ignored as well. Due to the side effects of synthetic medicine, the world has started looking toward herbal medicine for the treatment of viral diseases, which are comparatively more accessible and economical and bear fewer chances of toxicity and resistance.

### REFERENCES

- Akram M, Tahir IM, Shah SMA, Mahmood Z, Altaf A, Ahmad K, et al. Antiviral potential of medicinal plants against HIV, HSV, influenza, hepatitis, and coxsackievirus: A systematic review. *Phytother Res.* 2018;32:811-22.
- Chevallier A. *Herbal remedies handbook : more than 140 plant profiles : remedies for more than 50 common conditions.* New York: DK Publishing; 2018.
- Chevallier A. *Encyclopedia of herbal medicine. Third American edition.* ed. New York, New York: DK Publishing; 2016.
- Lin LT, Hsu WC, Lin CC. Antiviral natural products and herbal medicines. *J Tradit Complement Med.* 2014;4:24-35.
- Huang J, Su D, Feng Y, Liu K, Song Y. Antiviral herbs--present and future. *Infect Disord Drug Targets.* 2014;14:61-73.
- Mukhtar M, Arshad M, Ahmad M, Pomerantz RJ, Wigdahl B, Parveen Z. Antiviral potentials of medicinal plants. *Virus Res.* 2008;131:111-20.
- Norman RA, Shenefelt PD, Rupani RN. *Integrative dermatology.* Oxford: Oxford University Press; 2014.
- França K, Lotti TM. *Advances in integrative dermatology.* Hoboken, NJ: Wiley-Blackwell; 2019.





# 4<sup>th</sup> INDERCOS

## Dermatology and Cosmetology Congress with International Participants

27 - 30 MARCH, 2019  
HILTON ISTANBUL BOSPHORUS HOTEL  
ISTANBUL, TURKEY



### BOTULINUM TOXIN TREATMENT CONCEPTS

Zekayi Kutlubay

Istanbul University-Cerrahpaşa, Cerrahpaşa Medical Faculty, Department of Dermatology, Istanbul, Turkey Botulinum toxin (BoNT) has been approved for aesthetic use since 2002. Injection technique tends to be personal and based on clinical experience. Injection techniques and patterns have evolved, resulting in a more natural result and avoiding a “frozen” appearance.<sup>1</sup> In all cases, extreme caution should be taken with injections within the orbital rim. The upper face is considered a basic area for use of botulinum toxin. In the upper face, BoNT-A is most commonly used to eliminate or diminish glabellar rhytides (procerus and corrugator muscles), forehead rhytides (frontalis muscle), and periorbital rhytides or crow’s feet (lateral orbicularis oculi muscle). BoNT-A has been successfully administered in 3 to 5 deep intramuscular and perpendicular injections in a V-shaped pattern in glabellar area.<sup>2,3</sup> Procerus muscle lowers the medial aspect of the eyebrow and is the main contributor to the horizontal lines. Corrugator muscle draws down the medial aspect of the eyebrow and is primarily responsible for vertical lines.<sup>4</sup> For forehead rhytides, treatment is highly variable because of the anatomic variability of the frontalis muscle. The frontalis muscle elevates the eyebrow and is the only elevator muscle in the upper face. It raises the eyebrow and the upper lid and by this makes the eye look open and much bigger. BoNT-A is usually administered in 4 to 10 superficial intramuscular injections in a horizontal or V-shaped pattern under the hairline.<sup>3</sup> Injections must be deep, without contact with the periosteum. The injection point should be approximately 1 cm above the orbital rim.<sup>6</sup> Extend the injection sites far enough laterally to avoid excessive elevation of the lateral part of the eyebrow, termed the “Mephisto” or “Spock” appearance. Insert the needle to one-third its depth and inject BoNT-A superficially into the lateral fibers of the orbicularis oculi muscle. BoNT-A is usually administered in 2 to 6 superficial intradermal injections placed 1 cm lateral to the orbital rim.<sup>7</sup> Complications such as upper lip asymmetry and cheek ptosis may result from injecting into the lowest extensions of the crow’s feet at the m. Zygomaticus major. In women, the eyebrow is ideally positioned above the supraorbital rim, while in men, it lies at the rim. The medial and lateral ends of the eyebrow should lie at the same horizontal level. The frontalis plays the most important role in eyebrow lifting. Its medial fibers are stronger than the lateral fibers and that is one of the reasons why the lateral part of the eyebrow drops with time.<sup>4</sup> A key factor influencing dose is the provision of individualized therapy. It depends on gender, muscle mass and strength, wrinkle severity, elasticity, areas to be treated, and the desired degree and duration of effect. Photographic documentation should also be undertaken.

#### References

1. Kane MA, Monheit G. The Practical Use of AbobotulinumtoxinA in Aesthetics. *Aesthet Surg J.* 2017; 1;37:S12-S19.
2. Ascher B, et al. International consensus recommendations on the aesthetic usage of botulinum toxin type A (Speywood Unit)-Part I: Upper facial wrinkles. *J Eur Acad Dermatol Venereol.* 2010;24(11):1278-1284.
3. Flynn TC. Advances in the use of botulinum neurotoxins in facial esthetics. *J Cosmet Dermatol.* 2012;11(1):42-50.
4. de Maio M et al. Facial Assessment and Injection Guide for Botulinum Toxin and Injectable Hyaluronic Acid Fillers: Focus on the Upper Face. *Aesthetic Leaders in Facial Aesthetics Consensus Committee.* Plast



# 4<sup>th</sup> INDERCOS

**Dermatology and Cosmetology Congress  
with International Participants**

27 - 30 MARCH, 2019  
HILTON ISTANBUL BOSPHORUS HOTEL  
ISTANBUL, TURKEY



Reconstr Surg. 2017;140:265e-276e.

5. Gart MS, Gutowski KA. Aesthetic Uses of Neuromodulators: Current Uses and Future Directions. *Plast Reconstr Surg.* 2015;136:62S-71S.

6. Giordano CN, Matarasso SL, Ozog DM. Injectable and topical neurotoxins in dermatology: Indications, adverse events, and controversies. *J Am Acad Dermatol.* 2017;76(6):1027-1042.

7. Hexsel C et al. Botulinum toxin type A for aging face and aesthetic uses. *Dermatol Ther.* 2011;24(1):54-61.



# 4<sup>th</sup> INDERCOS

## Dermatology and Cosmetology Congress with International Participants

27 - 30 MARCH, 2019  
HILTON ISTANBUL BOSPHORUS HOTEL  
ISTANBUL, TURKEY



### **BOTULINUM TOXINS : AS A PAIN KILLER- ANTI - AGING PROPERTIES TOPICAL BOTULINUM TOXINS**

**Hüray Hügül**

Botulinum toxins are using in medicine for many years for the spasmodic neurological diseases, chronic migraine pain, tension type headaches, pains and chronic fibromyalgia. Novel use of botox for the other rheumatological diseases are studying.

Botulinum toxins are peripheral neuromuscular blocking agents which irreversibly bind to presynaptic terminal of the neuromuscular junctions and prevent release of acetylcholine for preventing muscle contraction. The pain which is due to the overtension of muscles such as tension type headaches, fibromyalgia and the pains which are due to torticollis, blepharospasm or the other spasmodic pain events in the body might be threatened by botulinum toxin injection. There are some studies about the botulinum toxin treatment at the vaginismus pain therapy.

Besides the antiaging properties of botulinum toxin threatment also pain relief is a huge indication of the toxin injection too.

Botox has been Food and Drug Administration (FDA) – approved for the treatment of chronic migraine pain and some tension pains.



# 4<sup>th</sup> Indercos

## Dermatology and Cosmetology Congress with International Participants

27 - 30 MARCH, 2019  
HILTON ISTANBUL BOSPHORUS HOTEL  
ISTANBUL, TURKEY



### COMBINATION THERAPY OF BOTULINUM TOXIN WITH OTHER NONSURGICAL PROCEEDURES

**Hüray Hügül**

Botulinum toxin treatment might be combined with many other nonsurgical procedures according to the the benefits for the patients' results.

In many cases fillers must be supported by botox in special areas such as glabellar groove, deep forehead lines, long lasting under eye - teartrough improvement, eye brow lift, malar augmentation, jaw line beauty which is managed with both fillers and platysmal botox, vertical lip lines or barkode lines wrinkles and volume deplation, sunken dorsal hand wrinkling and nonoperative rhinoplasty.

Also thread lifting procedures of face, neck or breasts might be supported by botox injections.

Fractional Radiofrequency, focus USG and the other skin rejuvenation threathments are more effective when they are combined with botulinum toxin applications.





# 4<sup>th</sup> INDERCOS

## Dermatology and Cosmetology Congress with International Participants

27 - 30 MARCH, 2019  
HILTON ISTANBUL BOSPHORUS HOTEL  
ISTANBUL, TURKEY



### **BOTULINUM TOXIN-A: MID & LOWER FACE**

**Andreas D Katsambas**

While the cosmetic use of Botulinum Toxin-A continues to increase since its approval some years ago, the percentage of Botulinum Toxin-A treatments in the upper face is higher than that of the mid and lower face.

The lower facial musculature is of paramount importance in aesthetic issues which has a certain level of difficulty due to the proximity of surrounding muscles. Therefore, it is important for physicians treating this area to obtain adequate training to understand the finer points of injection technique and facial anatomy. A detailed description of the indications and techniques of Botulinum Toxin-A for the treatment in the mid and lower face (e.g. Bunny lines, nasal tip ptosis, lip asymmetry, gummy smile etc.) will be presented.



# 4<sup>th</sup> INDERCOS

## Dermatology and Cosmetology Congress with International Participants

27 - 30 MARCH, 2019  
HILTON ISTANBUL BOSPHORUS HOTEL  
ISTANBUL, TURKEY



### PRP in COMBINATION THERAPIES

**Zahide Eriş Eken**

Platelet rich plasma (PRP) is plasma with many more platelets than what is typically found in blood. PRP has the concentration of growth factors that are released from concentrated platelets. This secretion of proteins able to capitalize on the healing process at the cellular level.

PRP has been invented to restore the natural beauty by starting the natural rejuvenation process of the skin. Besides that, it is also emerged to include hairs as a new injectable procedure to enable stimulating hair growth locally and topically; preventing its fall; improving hair shaft, hair stem, and its caliber; increasing its shine, vitality, and pliability; and declining hair splitting and breakage.<sup>1</sup>

Dermatological indications increase rapidly in recent years. In clinical trials, in comparative trials, and meta-analysis of PRP reorganized into facial rejuvenation, hair, scar, vitiligo, and synergistic effect with fractional lasers, with a conclusion that PRP has significant improvements in dermatology.<sup>2</sup>

Skin resurfacing for the purpose of rejuvenation and repair continues to evolve with the development of noninvasive or minimally invasive surgical substitutes. Advances in laser therapy, microneedling, and platelet-rich plasma have reinvigorated research in wound repair and regenerative science. An overall positive clinical response toward the use of platelet-rich plasma as an adjuvant to fractional photothermolysis and percutaneous, collagen induction is observed.<sup>3</sup>

#### **Literatures:**

- 1- Elghblawi E. Platelet-rich plasma, the ultimate secret for youthful skin elixir and hair growth triggering. *J Cosmet Dermatol.* 2018 Jun;17(3):423-430. doi: 10.1111/jocd.12404. Epub 2017 Sep 8.
- 2- Zhang M, Park G, Zhou B, Luo D. Applications and efficacy of platelet-rich plasma in dermatology: A clinical review. *J Cosmet Dermatol.* 2018 Oct;17(5):660-665. doi: 10.1111/jocd.12673. Epub 2018 Jul 25.
- 3- Badran KW, Nabili V. Lasers, Microneedling, and Platelet-Rich Plasma for Skin Rejuvenation and Repair. *Facial Plast Surg Clin North Am.* 2018 Nov;26(4):455-468. doi: 10.1016/j.fsc.2018.06.007. Epub 2018 Aug 16.



# 4<sup>th</sup> INDERCOS

## Dermatology and Cosmetology Congress with International Participants

27 - 30 MARCH, 2019  
HILTON ISTANBUL BOSPHORUS HOTEL  
ISTANBUL, TURKEY



### HERBAL STEM CELLS FOR ANTI-AGING

**Özgür Timurkaynak**

General properties of herbal stem cells that have especially been used in the cosmetic and pharmaceutical industry are summarized. Plants have the capacity to form and regenerate organs over their entire life cycle. The permanently active groups of pluripotent stem cells in plants are embedded in specialized tissues called meristems. The extracts that have been obtained from these meristems can show certain properties like protecting against UV radiation, extending the life of fibroblasts, stimulating their activity, regulating cell division, rebuilding damaged epidermis or activating DNA repair of the cells. These properties make the basis of their beneficial potential in the field of anti-aging.



# 4<sup>th</sup> INDERCOS

## Dermatology and Cosmetology Congress with International Participants

27 - 30 MARCH, 2019  
HILTON ISTANBUL BOSPHORUS HOTEL  
ISTANBUL, TURKEY



### STROMAL CELLS IN SKIN REJUVENATION

Markabayeva Assel

Therapy using Stromal Vascular Fraction (SVF) is a skin treatment that can be obtained from excess adipose (fat) tissue left from Lipoaspiration or Liposuction procedure. Along with endothelial cells, pericytes, fat cells and blood cells, it contains a large percentage of adipose-derived mesenchymal stem cells with potential regenerative and thus anti-aging properties. SVF is a heterogeneous mix of multiple cell populations with different degree of maturity and function. Selected studies registered on clinicaltrials.gov applies to the safety of MSCs application in a different dermatological disorders (Pic. 1) and in aesthetic dermatology and plastic surgery procedures (Pic. 2)

**Table 1**  
Selected studies registered on clinicaltrials.gov applies to safety of MSCs application in different dermatological disorders

No.	Study type	Condition	Number of patients	Number
1	1C1-MSCs	Psoriasis vulgaris	48	002014020104
2	4-MSCs	Erythrodermia Alopecia areata	22	002014020108
3	4-MSCs	Wound healing Chondral regeneration Epidermal Skin cancer treatment	80	002014020112
4	4-MSC 61F	Safety of 4-MSC 61F in Alzheimer's Disease Stroke	10	002014020113
5	4-MSC 61F	Safety of 4-MSC 61F in Lupus Alopecia Stroke	4	002014020114
6	4-MSCs	Wound healing of skin Chondral repair of articular cartilage in animal skin (pre-clinical) Dermatological disorders	20	002014020115
7	4-MSCs	Stomatitis	30	002014020116
8	4-MSC 61F	Wound healing Skin rejuvenation	14	002014020117
9	4-MSCs	Wound Epidermal Rejuvenation Burns	60	002014020118
10	4-MSCs	Epidermal rejuvenation	10	002014020119
11	4-MSCs	Burns	10	002014020120

**Picture 1**  
Maciej Nowacki, The use of stem cells in aesthetic dermatology and plastic surgery procedures. A compact review of experimental and clinical applications. *Advances in Dermatology and Allergology*, 2017 Dec; 34 (6): 526-534.





# 4<sup>th</sup> INDERCOS

## Dermatology and Cosmetology Congress with International Participants

27 - 30 MARCH, 2019  
HILTON ISTANBUL BOSPHORUS HOTEL  
ISTANBUL, TURKEY



**Table 2**  
Substantiated potential positive effects of the use of stem cells in aesthetic dermatology and plastic surgery procedures

Type of suggested procedure using stem cells	Type of suggested cells	Possible positive effects (positive indications)	Reference
Dermis cell suspension (autologous serum)	Autologous dermal stem cells (ADSCs)	Local natural treatment to support the natural healing process in conjunctions after the previous skin injuries	Khan et al. [17]
Cell-based liposculpture (CMBL)	Autologous-derived SVF (stromal vascular fraction) cells	Good evidence results in treatment of breast augmentation and facial lipoatrophy	Shibamoto et al. [20]
Dermis treated supporting regenerative-healing process risk plasma injection	Autologous dermal stem cells (ADSCs)	Epidermal area restoration	Rose [21]
Stem cell enriched tissue expansion (SETE)	Traditionally prepared fat grafts with adipose-derived stem cells (ADSCs)	Effective software on dermal grafting procedures performed especially in ulcers and post-sclerotic scars	Yaralis et al. [22]
Regeneration of adipogenic mesenchymal stem cells with stem cell and the delivery of their tissues	Stem cell-enriched stem cells (SCs) cells	Significantly more healing of plastic development of these tissues	Uygun et al. [23]
Stem cell supportive expansion	Stem cell-enriched stem cells (SCs) cells (MSCs)	Significantly increased proliferation rates and faster time interval healing	Yong et al. [24]
Dermis transdermal expansion	Autologous dermal stem cells (ADSCs)	Skin cell aging and regenerative effects	Chang et al. [25]

**Picture 2**

Maciej Nowacki, 1The use of stem cells in aesthetic dermatology and plastic surgery procedures. A compact review of experimental and clinical applications. *Advances in Dermatology and Allergology*. 2017 Dec; 34 (6): 526-534.

In the U.S., the unregulated use of SVF in private clinics led to the intervention of the U.S. governing body responsible for supervising and regulating cell therapy, the Food and Drug Administration (FDA). The FDA currently defines SVF as a drug, device, and/or biologic product.

In Japan, "The Act on the Safety of Regenerative Medicine" which regulates medical professionals' practices and clinical studies related to regenerative medicine classifies SVF as a low risk or medium risk depending upon the level of risk associated with the medical treatment.

In Europe, MSCs are classified as advanced therapy medicine products (ATMPs) guided through the European Medicines Agency (EMA).

In Australia, legislative framework for the regulation of human cell and tissue products by the "Therapeutic Goods Administration" (TGA) allows products that are derived from human tissue and cells during medical procedures they are collected from a patient who is under the clinical care and treatment of a licensed medical provider and manufactured by that medical provider for the therapeutic application in the treatment of a single indication and in a single course of treatment of that patient by the same medical provider.

Stromal Vascular Fraction (SVF) is recommended for the treatment of fine lines, wrinkles, sagging aged and damaged skin as well as to improve general skin tone, texture, and elasticity. The only known exclusions to this therapy is for patients who have any past or present infectious disease. The laboratory cannot process any lipoaspirate sample that may be a concern and/or risk to infection or contamination. Stromal Vascular Fraction (SVF) leads to softer, smoother, more radiant looking skin resulting from the repair and replacement of aged and damaged cells. Optimal results are achieved after approximately three weeks and may last up to a year.

The use of mesenchymal stem cells in aesthetic dermatology and plastic surgery procedures is very promising but it still not fully known mechanisms of cell interactions and possible risks and side effects.



# 4<sup>th</sup> INDERCOS

## Dermatology and Cosmetology Congress with International Participants

27 - 30 MARCH, 2019  
HILTON ISTANBUL BOSPHORUS HOTEL  
ISTANBUL, TURKEY



We think that there is still a big need to create and conduct different clinical studies which could resolve define safety of SC use and can significantly accelerate their implementation into aesthetic dermatology and plastic surgery.

### References

- C. Mason, P. Dunnill A brief definition of regenerative medicine. *Regen Med*, 3 (1) (2008), pp. 1-5
- Maciej Nowacki, 1The use of stem cells in aesthetic dermatology and plastic surgery procedures. A compact review of experimental and clinical applications. *Advances in Dermatology and Allergology*. 2017 Dec; 34 (6): 526-534.
- Spring S. Human cells, tissues, and cellular and tissue-based products (HCT/Ps) from adipose tissue: Regulatory considerations U. S. Food and Drug Administration/Center for Biologics Evaluation and Research/Center for Devices and Radiological Health 2014.
- Konomi K, Tobita M, Kimura K et al. New Japanese initiatives on stem cell therapies. *Cell Stem Cell* 2015;16:350–352.  
<http://www.ema.europa.eu/ema>  
<https://www.tga.gov.au>



# 4<sup>th</sup> INDERCOS

## Dermatology and Cosmetology Congress with International Participants

27 - 30 MARCH, 2019  
HILTON ISTANBUL BOSPHORUS HOTEL  
ISTANBUL, TURKEY



### SKIN COMPLICATION OF INJECTABLE AGENTS

#### Tuğba Kevser Uzunçakmak

Injectable therapies have been performed in a wide variety of procedures on a daily basis. They may manifest with different clinical side effects and complications. Any layer of skin can be affected and the severity of the reaction may change according to the therapeutic agent. The major side effects of injectable agents can be listed as inflammatory reactions (eg. injection site reactions such as redness, swelling, psoriasis, sarcoidosis, alopecia), infections, allergic reactions (urticaria, allergic and irritant contact dermatitis), ulcerations, necrosis, lipogranuloma formation, lipohypertrophy, vascular reactions (eg skin blanching, livedo reticularis, discoloration, Nicolau Syndrome) and amyloidosis. Clinicians should be aware of these side effects for preventing and early treatment of these reactions.

#### References

- DeLorenzi C. Complications of injectable fillers, part 2: vascular complications. *Aesthet Surg J.* 2014; 34: 584-600.
- Segaert S1, Hermans C2. Clinical Signs, Pathophysiology and Management of Cutaneous Side Effects of Anti-Tumor Necrosis Factor Agents. *Am J Clin Dermatol.* 2017; 18: 771-787.
- Seok J, Hong JY, Park KY, Kim BJ, Seo SJ, Kim MN, Hong CK. Delayed immunologic complications due to injectable fillers by unlicensed practitioners: our experiences and a review of the literature. *Dermatol Ther.* 2016; 29: 41-44.
- Pozzuoli GM, Laudato M, Barone M, Crisci F, Pozzuoli B. Errors in insulin treatment management and risk of lipohypertrophy. *Acta Diabetol.* 2018; 55: 67-73.
- Ansari AM, Osmani L, Matsangos AE, Li QK. Current insight in the localized insulin-derived amyloidosis (LIDA): clinico-pathological characteristics and differential diagnosis. *Pathol Res Pract.* 2017; 213: 1237-1241.
- Alkan Bozkaya T, Demirel G, Ormeci T, Al S, Çakar E, Tastekin A, Turkoglu H. Anticoagulant and vasodilator therapy for Nicolau syndrome following intramuscular benzathine penicillin injection in a 4 year old boy. *Arch Argent Pediatr.* 2016; 114: e184-186.
- Kamouna B, Darlenski R, Kazandjieva J, Balabanova M, Dourmishiev L, Negentsova Z, Etugov D, Mirchevska B, Tsankov N. Complications of injected vitamin E as a filler for lip augmentation: case series and therapeutic approach. *Dermatol Ther.* 2015; 28: 94-97.



# 4<sup>th</sup> INDERCOS

## Dermatology and Cosmetology Congress with International Participants

27 - 30 MARCH, 2019  
HILTON ISTANBUL BOSPHORUS HOTEL  
ISTANBUL, TURKEY



### TELOMERASE ACTIVATORS IN AGING

Kansu Büyükaşar

A human body has approximately 30 trillion cells with 200 different types. These cells are dying and being renewed continually. We have our genetical materials, *i.e.* genes located on double-stranded molecules of DNA called chromosomes. An entire chromosome has about 150 million base pairs. In every cell division about 30 to 200 base pairs are lost from the ends of telomeres.

**Telomere:** "Telo" means **end**, "meros" means **part**, telomere: end part. Telomeres are repeat **TTAGGG** sequences at the end of linear chromosomes, which can protect the ends of DNA strands from degradation and fusion. Telomeres are thus important in managing genomic stability. In each cell division telomeres continuously and progressively shorten until the cells become senescent with the inability to no longer replicate. So, telomere serves as a "**mitotic clock**". Telomere shortening prevents aberrant cell proliferation (*e.g.*, cancer) but the costs are cellular senescence and aging. Telomere and telomerase are therefore therapeutic targets for rejuvenescence and anticancer strategies. Senescent cells have different characteristics in terms of gene expression, metabolism and epigenome. Besides, these cells have a distinct secretome profile known as the *Senescence-Associated Secretory Phenotype* (SASP). This phenomenon is thought to function for senescent cells to communicate with the immune system (to possibly facilitate their own clearance), but also as an extracellular signal to promote the regeneration of tissues through the stimulation of nearby progenitor cells.

**Relationship of Telomeres with Aging and Diseases:** Aging is a degenerative process that is associated with a progressive accumulation of hazardous changes in body functions and increased risk of disease and death. It has been reported that the individuals with longer telomeres showed better health profile (*e.g.*, fewer age-related diseases). However, certain mammals such as laboratory mice (*Mus musculus*), whose telomeres do not reach a critical limit during normal aging. Therefore, it has been suggested that telomere length is not always predictive of aging deterioration in mice, pointing out that alternative factors could also drive aging. There are certain chronic diseases associated with short telomere such as hypertension, atherosclerosis, CVD, metabolic syndrome, diabetes and Alzheimer dementia. Furthermore, a link between short telomere and mortality rate has also reported due to infection and heart disease.

**Telomerase:** Telomerase enzyme was originally discovered in the unicellular eukaryote, *Tetrahymena*, by Elizabeth Blackburn and Carol Greider. It is a specific reverse transcriptase enzyme responsible for the maintenance of telomere length in most mammals by adding back DNA repeats (TTAGGG) to the end of chromosomes, thus compensating for the loss of telomeres that normally occurs in each cells division. This enzyme consists of catalytic reverse transcriptase enzymes (**TERT**), a telomerase RNA component (**TERC**) and species-specific accessory proteins. Most cells do not have this enzyme; therefore, they progressively lose their telomeres with each cell division. The enzyme is normally very active during embryogenesis but the activity is repressed conspicuously before birth. However, it is active in germ line, cancer and certain stem cells. As for somatic cells, there are particular cells in which telomerase is also active such as skin (in epidermis but not dermis), gut epithelial tissues and immune cells. Especially immune cells would be most affected by replicative senescence and apoptosis. Telomerase is important for the survival of non-mitotic, highly





# 4<sup>th</sup> Indercos

## Dermatology and Cosmetology Congress with International Participants

27 - 30 MARCH, 2019  
HILTON ISTANBUL BOSPHORUS HOTEL  
ISTANBUL, TURKEY



active cells, e.g., neurons. It has been proposed that telomerase protects the mitochondria from oxidative stress, and confers resistance to apoptosis. Decrease in telomerase activity leads to the telomere shortening, regardless of chronological age, and is associated with increased cardiovascular disease risk. However, the mice expressing lots of telomerase do not live longer.

**Telomerase Activators:** There are several telomerase activators. These are the following:

Astragalus membranaceus root extract

Astragaloside IV (is the main compound found in Astragalus membranaceus)

Cycloastragenol (hydrolysis product of the main active ingredient, astragaloside IV, a triterpenoidsaponin compound)

Statins (atorvastatin)

Metformin (through AMPK)

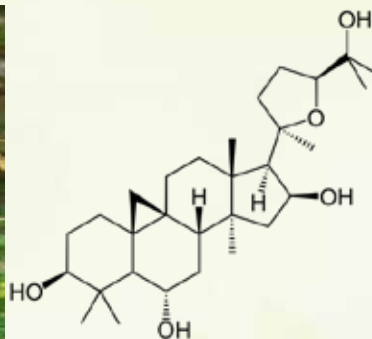
Curcuminoids (from the dried rhizomes of *Curcuma longa*)

**Astragalus membranaceus (Latin):** This is one of the important “*Qi tonifying*” adaptogenic herbs from the Chinese material medica. It is in Legum family and has been used in the practice of traditional Chinese medicine to treat a wide variety of diseases as life-prolonging extracts for more than 2000 years. This plant is also known as membranous milk-vetch root (*English*), Huang qi (*Chinese*), Ogi (*Japanese*), Hwanggi (*Korean*), and Gevenotu (*Turkish*).

**Ingredient of Astragalus Root:** There are numerous compounds in the root such as triterpenoidsaponins (Astragalosides), flavonoids, polysaccharides but pharmacologically important active ingredients are astragalosides.



Astragalus root



Cycloastragenol

**Cycloastragenol:** Astragalosides (e.g., astragaloside IV) can be converted to cycloastragenol which is the most important and effective antiaging component due to acid or enzymatic hydrolysis, Smith degradation and bacteria in gut. Now in the market, cycloastragenol is commercially available as an antiaging nutraceutical product.



# 4<sup>th</sup> INDERCOS

## Dermatology and Cosmetology Congress with International Participants

27 - 30 MARCH, 2019  
HILTON ISTANBUL BOSPHORUS HOTEL  
ISTANBUL, TURKEY



**Pharmacokinetics of Cycloastragenol:** Cycloastragenol is efficiently absorbed through the intestinal epithelium by passive diffusion; however, it undergoes an extensive first-pass metabolism in the liver. Cycloastragenol inhibits cytochrome P450 3A4 (CYP3A4) subunit but induces significantly CYP2E1 subunit.

**Biomedical Use of Cycloastragenol:** Cycloastragenol activates telomerase and decreases the percentage of critically short telomeres and DNA damage. Therefore, it exerts antiaging, antioxidant, anti-inflammatory, hepatoprotective, anticancer, hypolipidemic, antihyperglycemic, expectorant, diuretic, and immune-regulatory effects. *In vivo*, dietary supplementation of cycloastragenol increases **TERT** expression in tissues such as bone marrow, lungs, heart, brain, and liver. It has been reported that cycloastragenol improves epidermal thickness, hair growth, bone density, higher Hb, liver metabolic homeostasis, wound healing, and certain health-span indicators both in humans and animals. However, the data have shown that dietary supplementation with cycloastragenol does not impact the mean or maximum longevity of mice. Therefore, a necessary relation between telomerase activity and longevity does not likely exist. Cycloastragenol-induced telomerase activity is not mediated via common secondary messenger pathways, including  $Ca^{2+}$ ,  $IP_3$ , cAMP, Protein kinase B (Akt) but phosphorylation of extracellular signal-regulated kinase (ERK) may mediate its effects. In addition, cycloastragenol may also directly activate Farnesoid X receptors.

**Adverse reactions of Cycloastragenol:** Elongation of telomeres by telomerase enzyme is one of the characteristics of most of tumors, and thus it is vitally important to understand the efficacy, safety, and suitability of telomerase activators such as cycloastragenol. It has been reported that up to 150 mg/kg/day cycloastragenol (p.o.) for 91 consecutive days had no mortalities, which renders the usage of cycloastragenol seems to be safe. Accordingly, long-term administration of it did not increase the incidence of cancer. A comprehensive health maintenance program using a commercial dietary supplement pack containing cycloastragenol that provided 7000 person-years (The *Patton protocol-1*) reported no serious adverse events. Nevertheless, the potential adverse reactions of cycloastragenol should be noted, and more studies about adverse reactions are necessary to fully understand how to use cycloastragenol rationally.

**Summary of Cycloastragenol-Elicited Beneficial Effects:** Cycloastragenol lengthens critically short telomeres of circulating leukocytes of immuno-compromised individuals with HIV and CMV. Besides, it improves certain aspect of immune aging (T cell response and B cell antigen production). It increased T cell telomerase activity and enhance T cell proliferation, which is critically important in HIV and other immunodeficiency situations. Cycloastragenol improves glucose and lipid profiles as well as wound healing. It regulates systolic/diastolic blood pressure, and decreases inflammation and improves markers of metabolic, bone and cardiovascular parameters. Furthermore, telomerase has also been reported to reduce mitochondrial ROS production and protected the mtDNA from damages.

**Conclusion:** In humans, recent meta-analyses have supported the existence of a strong relation between short telomeres and mortality risk, particularly at younger ages. Telomerase is important in cellular proliferation. However, many of our organs, such as the brain, are mostly composed of cells that do not proliferate. Hence, it is debatable that telomerase activators will improve the function of these tissues and slow down aging. There is ample evidence that tumors have high telomerase activity and so telomerase-based therapies may induce cancer development. Whether telomerase-activating therapies will succeed in retarding human aging needs to be established, and there are questions about the efficiency and long-term



# 4<sup>th</sup> INDERCOS

## Dermatology and Cosmetology Congress with International Participants

27 - 30 MARCH, 2019  
HILTON ISTANBUL BOSPHORUS HOTEL  
ISTANBUL, TURKEY



safety of telomerase-based anti-aging therapies. Interestingly enough, cycloastragenol does not extend lifespan in mice despite increasing telomerase levels. Although telomere shortening may be a marker of certain diseases, there is no evidence at the moment that telomere length is a better indicator of biological age than chronological age. However, some companies are also selling telomere measurements to estimate biological age, which is intriguing. For a good strategy to slow down aging, to improve life quality and to maintain telomere length, life style changes such as stress reduction, exercise, weight loss, having a balanced diet, smoking cessation and avoiding of virus e.g. CMV is essentially important.

### References

- Astragalus membranaceus. Monograph. *Altern Med Rev.* 2003, 8(1):72-77.
- Artandi SE, Alson S, Tietze MK, Sharpless NE, Ye S, Greenberg RA, Castrillon DH, Horner JW, Weiler SR, Carrasco RD, DePinho RA. Constitutive telomerase expression promotes mammary carcinomas in aging mice. *Proc Natl Acad Sci U S A.* 2002;99(12):8191-8196.
- Cawthon RM, Smith KR, O'Brien E, Sivatchenko A, Kerber RA. Association between telomere length in blood and mortality in people aged 60 years or older. *Lancet.* 2003 Feb 1;361(9355):393-395.
- Coppé JP, Patil CK, Rodier F, Sun Y, Muñoz DP, Goldstein J, Nelson PS, Desprez PY, Campisi J. Senescence-associated secretory phenotypes reveal cell-nonautonomous functions of oncogenic RAS and the p53 tumor suppressor. *PLoS Biol.* 2008;6(12):2853-2868.
- de Jesus BB, Schneeberger K, Vera E, Tejera A, Harley CB, Blasco MA. The telomerase activator TA-65 elongates short telomeres and increases health span of adult/old mice without increasing cancer incidence. *Aging Cell* (2011) 10, pp604–621.
- de Magalhães JP, Toussaint O. Telomeres and telomerase: a modern fountain of youth? *Rejuvenation Res.* 2004 7(2):126-133.
- Fernandez ML, Thomas MS, Lemos BS, DiMarco DM, Missimer A, Melough M, Chun OK, Murillo AG, Alyousef HM, Medina-Vera I. TA-65, a telomerase activator improves cardiovascular markers in patients with metabolic syndrome. *Curr Pharm Des.* 2018;24(17):1905-1911.
- Fitzpatrick AL, Kronmal RA, Kimura M, Gardner JP, Psaty BM, Jenny NS, Tracy RP, Hardikar S, Aviv A. Leukocyte telomere length and mortality in the Cardiovascular Health Study. *J Gerontol A Biol Sci Med Sci.* 2011;66(4):421-429.
- Harley CB, Liu W, Flom PL, Raffaele JM. A natural product telomerase activator as part of a health maintenance program: metabolic and cardiovascular response. *Rejuvenation Res.* 2013 16(5):386-395.
- Indran IR, Hande MP, Pervaiz S. hTERT overexpression alleviates intracellular ROS production, improves mitochondrial function, and inhibits ROS-mediated apoptosis in cancer cells. *Cancer Res.* 2011;71(1):266-276.
- Satoh M, Minami Y, Takahashi Y, Tabuchi T, Itoh T, Nakamura M. Effect of intensive lipid-lowering therapy on telomere erosion in endothelial progenitor cells obtained from patients with coronary artery disease. *Clin Sci (Lond).* 2009;116(11):827-835.
- Strazhesko ID, Tkacheva ON, Akasheva DU, et al. Atorvastatin Therapy Modulates Telomerase Activity in Patients Free of Atherosclerotic Cardiovascular Diseases. *Front Pharmacol.* 2016;7:347.
- Yu Y, Zhou L, Yang Y, Liu Y. Cycloastragenol: An exciting novel candidate for age-associated diseases. *Exp Ther Med.* 2018;16(3):2175-2182.



# 4<sup>th</sup> INDERCOS

## Dermatology and Cosmetology Congress with International Participants

27 - 30 MARCH, 2019  
HILTON ISTANBUL BOSPHORUS HOTEL  
ISTANBUL, TURKEY



### NEW TATTOO APPROACHES IN DERMATOLOGY

Zehra Aşiran Serdar

Tattoo has been a trend for centuries. Although tattoos were once considered to be permanent, various treatment modalities have been developed in recent years in order to remove unwanted tattoos. Contemporary technology involves the use of non-ablative quality-switched lasers, which are considered to be the gold-standard treatment option for the removal of unwanted tattoo ink.

Lasers based on the principle of selective photothermolysis are now being used to remove black as well as colorful tattoos with varying successes. The commonly used lasers for tattoo removal are the Q-switched 694-nm ruby laser, the Q-switched 755-nm alexandrite laser, the 1,064-nm Nd:YAG laser, and the 532-nm Nd:YAG laser. Newer techniques and methods are evolving in tattoo removal with lasers. Choosing the right laser for the right tattoo color is necessary for a successful outcome. Current research in the field of tattoo removal is focused on faster lasers and more effective targeting of tattoo pigment particles including picosecond laser devices, multi-pass treatments, dermal scatter reduction, application of imiquimod, and the use of microencapsulated tattoo ink. However, there are complications that can occur such as dyspigmentation, allergic reactions, epidermal debris, ink darkening.

#### References

- 1.Kent, K.M., Graber, E.M. **Laser tattoo removal: a review.** *Dermatol Surg.* 2012;38:1–13.
- 2.Pinto F, Große-Büning S, Karsai S, Weiß C, Bäuml W, Hammes S, Felcht M, Raulin C. Neodymium-doped yttrium aluminium garnet (Nd:YAG) 1064-nm picosecond laser vs. Nd:YAG 1064-nm nanosecond laser in tattoo removal: a randomized controlled single-blind clinical trial.Br J Dermatol. 2017 Feb;176(2):457-464.
3. Naga LI, Alster TS.Laser Tattoo Removal: An Update.Am J Clin Dermatol. 2017.Feb;18(1):59-65.
4. Choudhary S1, Elsaie ML, Leiva A, Nouri K. Lasers for tattoo removal: a review. *Lasers Med Sci.* 2010 Sep;25(5):619-27.
5. Luebberding S, Alexiades-Armenakas M, New Tattoo Approaches in Dermatology *Dermatologic Clinics.*Volume 32, Issue 1, January 2014, Pages 91-96.





# 4<sup>th</sup> INDERCOS

## Dermatology and Cosmetology Congress with International Participants

27 - 30 MARCH, 2019  
HILTON ISTANBUL BOSPHORUS HOTEL  
ISTANBUL, TURKEY



### HYPERBARIC OXYGEN THERAPY IN DERMATOLOGY

**Burhan Engin**

Hyperbaric oxygen therapy works by breathing 100% oxygen while under increased atmospheric pressure inside a chamber. The first well-known chamber was built and run by a British clergyman named Henshaw. Henshaw built a structure called the domicilium that was used to treat a multitude of diseases. There are two types of chambers in which hyperbaric oxygen therapy may be performed: multiplace and monoplace chambers.

One of the most common uses for hyperbaric oxygen is for chronic wounds. Most wounds that fail to heal are usually hypoxic. In response to high concentrations of oxygen, angiogenesis is stimulated by release of growth factors and other mediators involved in wound healing process. One of benefits of hyperbaric oxygen therapy is in the treatment of diabetic ulcers. This has been one of the most researched aspects of hyperbaric medicine. The etiology behind these wounds are multifactorial and hyperbaric oxygen therapy can be used to address a multitude of these factors.

Another use of hyperbaric oxygen therapy is for pyoderma gangrenosum. Pyoderma gangrenosum is a rare type of neutrophilic dermatosis with an unknown etiology and variable presentation. It is a disorder that usually affects the skin but may rarely also affect the subcutaneous tissue. It is well documented its use as an adjuvant therapy together with local dressings and surgical debridement.

Hyperbaric oxygen therapy can also be used in patients with livedoid vasculopathy. Livedoid vasculopathy or livedoid vasculitis is a rare cutaneous disease mainly affecting the lower extremities and is clinically seen as recurrent ulcerations. These ulcers heal with an atrophic, porcelain white scar called atrophie blanche, which is an alternative name used for the disease. Inflammation, autoimmunity and hypercoagulability are the main pathogenetic factors with the latter being the most predominant among them. In patients with livedoid vasculitis it can be used as an adjuvant therapy together with pentoxifylline, low-dose aspirin and folic acid.

Hidradenitis suppurativa a disease characterized by comedo-like follicular occlusion, chronic relapsing inflammation, mucopurulent discharge, and progressive scarring which on its late stages is known to cause morbidities like pain, keloids, contractures, and immobility. It is one of the diseases known to benefit from hyperbaric oxygen treatment especially when used together with a combination of antibiotics like rifampicin and clindamycin.

The effect of hyperbaric oxygen therapy is achieved in compromised nutritive flow and oxygen supply to tissues caused by local injury or infection. The rationale for its use is that intermittent hyperoxia may stimulate the healing process through collagen synthesis and by enabling angiogenesis, increase erythrocyte deformability, and reduce edema and reperfusion injury. Hyperbaric oxygen therapy is considered as an important complementary treatment, if it can be instituted soon after the event.



# 4<sup>th</sup> INDERCOS

## Dermatology and Cosmetology Congress with International Participants

27 - 30 MARCH, 2019  
HILTON ISTANBUL BOSPHORUS HOTEL  
ISTANBUL, TURKEY



### HAIR TRANSPLANTATION IN DERMATOLOGY

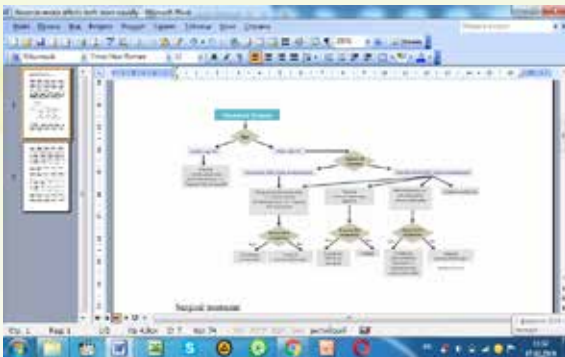Markabayeva Assel

Alopecia affects both sexes equally, affects patients of all ages, and is found in approximately 0.1% to 0.2% of the general population.

A meta-analysis of 2530 adult patients showed significant alopecia areata abnormalities in HRQOL, especially in the area of mental health. While AA affects both sexes equally, data from the Rochester Epidemiology Project revealed that men tended to be diagnosed earlier compared with women (mean age at diagnosis, 31.5 vs 36.2 years). Clinical manifestations varied from well-defined areas hair loss before diffuse alopecia. Main factors influencing the prognosis include age and stage of the disease. Recent pathogenesis studies also confirm autoimmune etiology and increased regulation inflammatory pathways, genes involved in congenital and adaptive immunity, oxidative stress and Janus kinase /signal transducers and transcription activators signal path.

Meta-analysis about effectiveness of treatments strongly suggests that minoxidil, finasteride, and low-level laser light therapy are effective for promoting hair growth in men with androgenetic alopecia and that minoxidil is effective in women with androgenetic alopecia.

**Pic 1. Strazzulla et al.** Treatment algorithm for the management of alopecia areata. DPCP, Diphenylcyclopropenone; JAK, Janus kinase; SADBE, squaric acid dibutylester.



#### Surgical treatment

In the research of satisfaction with the result after hair transplantation, it was determined that patients with a high level of self-esteem tend to have higher rates of postoperative satisfaction with their appearance, psychological well-being, social function and satisfaction with decision making compared with patients with low and medium self-esteem.

However, in the event of depletion of donor tissues, with a grim reaction to local pharmacotherapy, in all cases of androgenic alopecia in men and women, the implantation of artificial hair is an option to help such patients. In 1996, the artificial fibers (Biofibre®) produced by Medicap® Italy were approved by the UE and the Australian Therapeutic Goods Administration (TGA) as a medical implant for implantation into the scalp. In subsequent years, an effective medical protocol was developed to provide proper advice on the proper transplantation of artificial hair



# 4<sup>th</sup> INDERCOS

## Dermatology and Cosmetology Congress with International Participants

27 - 30 MARCH, 2019  
HILTON ISTANBUL BOSPHORUS HOTEL  
ISTANBUL, TURKEY



and reduce the possible complications associated with it. Biofibre® medical hair available in 13 colors, with different lengths (15, 30 or 45 centimeters) and in various shapes (straight, wavy, curly and afro) to satisfy different patients requests. This is a non-traumatic technique, which is performed under local anesthesia and enables the implantation by automatic machine with special hooked needles of the desired quantity of hair, the immediate aesthetic result with a natural appearance.

In an article on the evolution of artificial hair, one hundred thirty-three cases of patients with androgenic alopecia treated with Biofibre® were reported. Results were observed for 3 years. 96.2% of patients are stated as satisfied. A study on the safety and efficacy of implantation of 133 patients is considered an efficient surgical technique. Our experience associated with the transplantation of artificial hair as well as other doctors coincides in the opinion of choosing the right patient (androgenic alopecia in history, lack of response to pharmacological agents, dissatisfaction with the previous treatment, including transplantation of own hair, performance in implant care) individuality in approach (choice of a suitable hair color, length, direction of growth of implantable hair, repeated procedures for the purpose of an even gradual result, especially for men), is excluded Hair transplant in non-recommended areas (forehead line, temporal region, lower part of occipital region). We consider that, subject to the above rules, the transplantation of artificial hair is a viable option in the proposed methods of treatment of alopecia.

### References:

- Rencz F, Gulácsi L, Péntek M, Wikonkál N, Baji P, Brodszky V. Alopecia areata and health-related quality of life: a systematic review and meta-analysis. 2016. *Br J Dermatol*.175(3):561-71
- Mirzoyev SA, Schrum AG, Davis MDP, Torgerson RR. Lifetime incidence risk of alopecia areata estimated at 2.1 percent by Rochester Epidemiology Project, 1990e2009. *J Invest Dermatol*. 2014;134:1141
- Strazzulla, L. C., Wang, E. H. C., Avila, L., Lo Sicco, K., Brinster, N., Christiano, A. M., & Shapiro, J. (2018). Alopecia areata. *Journal of the American Academy of Dermatology*, 78(1), 1–12. doi:10.1016/j.jaad.2017.04.1141
- Adil, A., & Godwin, M. (2017). The effectiveness of treatments for androgenetic alopecia: A systematic review and meta-analysis. *Journal of the American Academy of Dermatology*, 77(1), 136–141.e5.
- Strazzulla, L. C., Wang, E. H. C., Avila, L., Lo Sicco, K., Brinster, N., Christiano, A. M., & Shapiro, J. (2018). Alopecia areata. *Journal of the American Academy of Dermatology*, 78(1), 15–24. doi:10.1016/j.jaad.2017.04.1142
- Liu, F., Miao, Y., Li, X., Qu, Q., Liu, Y., Li, K., ... Hu, Z. (2018). The relationship between self-esteem and hair transplantation satisfaction in male androgenetic alopecia patients. *Journal of Cosmetic Dermatology*.
- Agrawal M, Lotti J, França K, Fioranelli M, Roccia MG, Lotti T. 2017. The evolution of artificial hair implantation. *J Biol Regul Homeost Agents*. 2017 APR-JUN;31(2 Suppl. 2):169-177.
- Tchernev G, Sheta M, Rahoui M, Chokoeva AA, Wollina U, Maximov GK, Patterson JW, Fioranelli M, Roccia MG, Ananiev J1, Lotti T. 2011. Biofibre hair implant: what is new, what is true? *J Biol Regul Homeost Agents*. 2016 Apr-Jun;30(2 Suppl 2):27-34.
- Serdeev N, D. Erme AM, Hercogova J, Zarrab Z, Chokoeva AA, Tchernev G, Wollina U, Lotti T. Polyamide hair implant (biofibre®): evaluation of efficacy and safety in a group of 133 patients. 2016. *J Biol Regul Homeost Agents*. 2015 Jan-Mar;29(1 Suppl):103-9.
- Maria Roccia, Katlein França, David Castillo, Georgi Tchernev, Uwe Wollina, Michael Tirant, Yan Valle, Claudio Guarneri, Massimo Fioranelli, and Torello Lotti. Artificial Hair: By the Dawn to Automatic Biofibre® Hair Implant. *Open Access Maced J Med Sci*. 2018 Jan 25; 6(1): 156–162.



# 4<sup>th</sup> INDERCOS

## Dermatology and Cosmetology Congress with International Participants

27 - 30 MARCH, 2019  
HILTON ISTANBUL BOSPHORUS HOTEL  
ISTANBUL, TURKEY



### **ASSESSMENT OF INTRALESIONAL INJECTION OF BOTULINUM TOXIN FOR HYPERTROPHIC SCARS**

**Hasan Mete Aksoy**

Keloids and hypertrophic scars are characterized by fibroblast hyperproliferation and excess collagen deposition. Recent reports have demonstrated that botulinum toxin improves wound healing. So, it may play a role in treating hypertrophic scars. Clinical evidence indicates that botulinum toxin can be used to prevent and treat keloids and hypertrophic scars. Botulinum toxin may reduce skin fibrosis by decreasing fibroblast proliferation, modulating the activity of transforming growth factor- $\beta$ , and reducing transcription and expression of profibrotic cytokines in keloid-derived and hypertrophic scar-derived dermal fibroblasts. Botulinum toxin may also modulate collagen deposition. Intralesional injection was the preferred method of delivery at one- or three-months intervals for three to nine months (three sessions). In several clinical studies its effect of eliminating or decreasing hypertrophic scars was found to be promising. Treatment outcomes were generally favorable, and patient satisfaction was high. The injection of botulinum toxin in the treatment of resistant, invalidating keloid scars seems to show a very encouraging degree of effectiveness. The results on pain and aesthetic appearance were good to very good following treatment of keloids with botulinum toxin injections in clinical studies. There are also reports that give unfavorable results concerning botulinum toxin A therapy of proliferative scars.

The efficacy of botulinum toxin to reduce proliferative scars appears promising and the clinical literature seems currently to favor its use over placebo controls as a safe proliferative scar reduction alternative. The efficacy of this modality in comparison with other more widely accepted scar reduction methods is less clear. Further understanding of the molecular mechanism of action of botulinum toxin upon hypertrophic scars and comparisons of treatment modality cost-effectiveness remain to be explored.

Botulinum toxin is also a suitable potential therapy for the prevention of hypertrophic scars or obtaining better scars in patients undergoing skin laceration repair or elective surgeries in the maxillofacial and neck areas.





# 4<sup>th</sup> INDERCOS

## Dermatology and Cosmetology Congress with International Participants

27 - 30 MARCH, 2019  
HILTON ISTANBUL BOSPHORUS HOTEL  
ISTANBUL, TURKEY



### THE ROLE OF METABOLOMICS IN THE PATHOGENESIS OF HIDRADENITIS SUPPURATIVA

Bodo C. Melnik

Disintegration of the infundibula of terminal hair follicles (HFs) in intertriginous skin areas exhibits the histological hallmark of hidradenitis suppurativa (HS)/acne inversa, histopathologically featuring a dissecting terminal hair folliculitis.<sup>1</sup> Elevated serum levels of interleukin (IL)-17 and local increase in the ratio of pro-inflammatory T helper (Th)17 cells and anti-inflammatory regulatory T cells (Tregs) have been reported.<sup>2,3</sup> Recent evidence indicates that Tregs in HS as well exhibit increased expression of the master Th17 transcription factor, retinoic acid orphan receptor- $\gamma$ t (ROR $\gamma$ t), promoting enhanced expression of Th17 genes including IL-17 promoting an inflammatory Treg phenotype with pathological functional activity.<sup>4</sup> Importantly, it has been demonstrated that Tregs play a key role in HF maintenance and interact with HF stem cells via Notch signaling.<sup>5</sup> Notch signaling is compromised in familial forms of acne inversa.<sup>6</sup> We recently proposed that the disturbed Th17/Treg ratio or compromised Treg function in HS may impair the function of perifollicular Tregs resulting in disturbed HF stem cell homeostasis. This may explain the disturbed infundibular integrity finally resulting in dissecting terminal hair folliculitis.<sup>7</sup>

The well-known association of obesity and the metabolic syndrome in the pathogenesis of HS has attracted much interest within recent years.<sup>8</sup> In both, patients with metabolic syndrome and HS, increased mTORC1 activity is associated with insulin resistance.<sup>9</sup> Increased mTORC1 activity and downstream enhanced activity of S6K1 via inhibitory phosphorylation of insulin receptor substrate 1 (IRS-1) promotes insulin resistance. Furthermore, mTORC1 positively modulates IL-17 expression through several pathways, i.e. STAT3, hypoxia-inducible factor 1(HIF-1 $\alpha$ ), S6K1, and S6K2. HIF-1 inhibits the expression of FoxP3, the key suppressor of ROR $\gamma$ t. Increased mTORC1 activity is thus associated with increased Th17 cell polarization and IL-17 synthesis and secretion.<sup>10</sup> Increased mTORC1 signaling, a hallmark of the metabolic syndrome, links HS metabolomics and immune pathogenesis of HS and other Th17-dependent comorbidities of HS.

Metabolomic effects in HS pathogenesis. Obesity disturbs the Th17/Treg axis. It has been hypothesized that inappropriate generation of FoxP3+ Tregs impairs HF SC function. Obesity-mediated mechanistic target of rapamycin complex 1 (mTORC1) activation enhances the expression hypoxia-inducible factor (HIF)-1, which controls a critical checkpoint downregulating FoxP3 and promoting ROR $\gamma$ t signaling and thus Th17 differentiation with expression of pro-inflammatory interleukin (IL)-17. Functionally insufficient perifollicular Tregs may destabilize HF stem cell activity promoting the dissecting folliculitis, sebaceous gland (SG) involution, abscesses and sinus tract formation. ATRA, all-trans retinoic acid; STAT3, signal transducer and activator of transcription 3; TGF-, transforming growth factor- (Melnik BC *et al.* Br. J. Dermatol. 2018; 179:260-72).



# 4<sup>th</sup> INDERCOS

## Dermatology and Cosmetology Congress with International Participants

27 - 30 MARCH, 2019  
HILTON ISTANBUL BOSPHORUS HOTEL  
ISTANBUL, TURKEY



### References

1. Chen W, Plewig G. Should hidradenitis suppurativa/acne inversa best be renamed as “dissecting terminal hair folliculitis”? *Exp Dermatol.* 2017;26:544-47.
2. Moran B, Sweeney CM, Hughes R, Malara A, Kirthi S, Tobin AM, Kirby B, Fletcher JM. Hidradenitis suppurativa is characterized by dysregulation of the Th17:Treg cell axis, which is corrected by anti TNF therapy. *J Invest Dermatol.* 2017;137:2389-95.
3. Thomi R, Cazzaniga S, Seyed Jafari SM, Schlapbach C, Hunger RE. Association of hidradenitis suppurativa with T helper 1/T helper 17 phenotypes: A semantic map analysis. *JAMA Dermatol.* 2018;154:592-5.
4. Remedios KA, Zirak B, Sandoval PM, Lowe MM, Boda D, Henley E, Bhattarai S, Scharschmidt TC, Liao W, Naik HB, Rosenblum MD. The TNFRSF members CD27 and OX40 coordinately limit TH17 differentiation in regulatory T cells. *Sci Immunol.* 2018;3(30). pii: eaau2042.
5. Ali N, Zirak B, Rodriguez RS, Pauli ML, Truong HA, Lai K, Ahn R, Corbin K, Lowe MM, Scharschmidt TC, Taravati K, Tan MR, Ricardo-Gonzalez RR, Nosbaum A, Bertolini M, Liao W, Nestle FO, Paus R, Cotsarelis G, Abbas AK, Rosenblum MD. Regulatory T cells in skin facilitate epithelial stem cell differentiation. *Cell.* 2017;169:1119-9.
6. Melnik BC, Plewig G. Impaired Notch-MKP-1 signalling in hidradenitis suppurativa: an approach to pathogenesis by evidence from translational biology. *Exp Dermatol.* 2013;22:172-7.
7. Melnik BC, John SM, Chen W, Plewig G. T helper 17 cell/regulatory T-cell imbalance in hidradenitis suppurativa/acne inversa: the link to hair follicle dissection, obesity, smoking and autoimmune comorbidities. *Br J Dermatol.* 2018;179:260-72.
8. Ergun T. Hidradenitis suppurativa and the metabolic syndrome. *Clin Dermatol.* 2018;36:41-7.
9. De Vita V, Melnik BC. mTORC1 at the crossroad of metabolism and immunity in hidradenitis suppurativa. *J Eur Acad Dermatol Venereol.* 2018 Oct 5. doi: 10.1111/jdv.15270. [Epub ahead of print]
10. Ren W, Yin J, Duan J, Liu G, Tan B, Yang G, Wu G, Bazer FW, Peng Y, Yin Y. mTORC1 signaling and IL-17 expression: Defining pathways and possible therapeutic targets. *Eur J Immunol.* 2016;46:291-9.



# 4<sup>th</sup> INDERCOS

## Dermatology and Cosmetology Congress with International Participants

27 - 30 MARCH, 2019  
HILTON ISTANBUL BOSPHORUS HOTEL  
ISTANBUL, TURKEY



### ACNE NUTRIGENOMICS

**Bodo C. Melnik**

Acne vulgaris during adolescence is an epidemic disease of Western civilization.<sup>1</sup> Typical Western diet, characterized by high intake of hyperglycemic carbohydrates and milk/dairy consumption,<sup>2</sup> has been related to the nutritional acne exposome. Both, hyperglycemic carbohydrates and milk intake increase insulin- and insulin-like growth factor-1 (IGF-1) signaling and have been associated with increased acne prevalence and acne risk.<sup>3,4</sup> Insulin and IGF-1 activate the kinase AKT, which stimulates the nutrient- and growth factor-sensitive kinase mechanistic target of rapamycin complex 1 (mTORC1). AKT also phosphorylates mouse double minute 2 (MDM2), which degrades the transcription factor p53, the guardian of the genome. Over-expressed and over-activated mTORC1 has been detected in the skin and sebaceous glands of acne patients.<sup>5</sup> mTORC1 activates the kinase S6K1, which via phosphorylation of insulin receptor substrate 1 (IRS-1) promotes insulin resistance. mTORC1 promotes the expression of sterol regulatory element-binding factor 1 (SREBP-1), the master transcription factor of sebaceous lipogenesis (Figure). Expression of SREBP-1 is increased in sebaceous glands of acne patients and could be reduced by a low glycemic diet. Activated mTORC1 also promotes Th17 cell differentiation resulting in enhanced production of interleukin 17 (IL-17), observed in the skin of acne patients. Increased Th17 cell polarization has been associated with insulin resistance, obesity and type 2 diabetes mellitus (T2DM). Insulin resistance, a key feature of obesity, T2DM and the metabolic syndrome, has been associated with acne vulgaris. Thus, nutrigenomic effects in acne patients associated with over-activated mTORC1 signaling allow the conclusion that acne vulgaris represents the metabolic syndrome of the sebaceous follicle.<sup>6</sup>

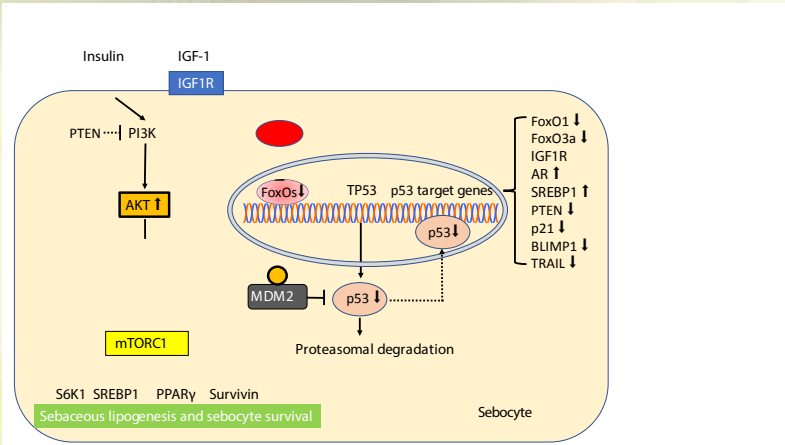
Remarkably, p53 has been identified as a negative regulator of IGF-1 receptor (IGF1R) and androgen receptor (AR) gene expression. In contrast, p53 induces the transcription factors FoxO1 and FoxO3 and AMPK, which function as negative regulators of mTORC1. Thus, p53 attenuates mTORC1 activity at multiple checkpoints including the suppression of SREBP-1,<sup>7</sup> the key transcription factor of sebaceous lipogenesis. Reduction of insulin/IGF-1 signaling by restriction of hyperglycemic carbohydrates, milk and dairy protein attenuates AKT and MDM2 activity, thereby enhances p53 signaling. Dietary intervention in acne via stabilization of p53 attenuates over-activated mTORC1. Recent evidence indicates that all anti-acne agents in clinical use all synergize in promoting the expression of p53.<sup>8</sup> In fact, it has been demonstrated in primary human keratinocytes that isotretinoin (13-cis retinoic acid), the most potent anti-acne agent, upregulates the expression of p53 and FoxO1.<sup>9</sup> The understanding of acne nutrigenomics thus presents a clear rationale for the prevention of acne vulgaris via restriction of Western diet, which over-stimulates insulin/IGF-1 signaling. The anti-acne diet should resemble a paleolithic diet with restriction of hyperglycemic carbohydrates and milk/dairy protein (Table). The gene-regulatory effects of dietary intervention in acne synergize with the activity of pharmacological treatment via activation of p53 and attenuation of over-stimulated mTORC1. In this regard, it is of critical concern that frequently used immortalized sebocytes (SZ95 and SEB-1) are not useful models to study anti-acne agents such as isotretinoin, because the procedure of immortalization via Simian virus large T antigen inactivates p53.<sup>10</sup>



# 4<sup>th</sup> INDERCOS

## Dermatology and Cosmetology Congress with International Participants

27 - 30 MARCH, 2019  
HILTON ISTANBUL BOSPHORUS HOTEL  
ISTANBUL, TURKEY



**Western-diet and acne nutrigenomics:** Hyperglycemic carbohydrates and milk consumption increase insulin and insulin-like growth factor 1 (IGF-1)-PI3K-AKT signaling in sebocytes of patients with acne vulgaris. Over-activated AKT phosphorylates tuberin (TSC2) enhancing mTORC1 activity, which activates S6K1-mediated translation, SREBP1- and PPAR $\gamma$ -mediated sebaceous lipogenesis and sebocyte survival. AKT phosphorylates nuclear FoxO1 and FoxO3 resulting in FoxOs export into the cytoplasm. AKT phosphorylates mouse double minute 2 (MDM2), thereby attenuates proteasomal degradation of p53. This results in reduced expression of p53 target genes including FoxO1, FoxO3, p21, and TRAIL. Reduced nuclear FoxO expression reduces the expression of sestrin 3, a key activator of AMPK. AMPK-mediated phosphorylation of TSC2 inhibits mTORC1 activation.

Abbreviations: AMPK, AMP-responsive protein kinase; AR, androgen receptor; BLIMP1, B lymphocyte-induced nuclear maturation protein 1; FoxO, forkhead box O transcription factor; IGF-1, insulin-like growth factor 1; IGF1R, IGF-1 receptor; MDM2, mouse double minute 2; p21, cell cycle inhibitor p21; p53, transcription factor p53; PI3K, phosphoinositide-3 kinase; PTEN, phosphatase and tensin homolog; S6K1, S6 kinase 1; SREBP1, sterol regulatory element binding protein 1; TRAIL, tumor necrosis factor-related apoptosis-inducing ligand.





# 4<sup>th</sup> INDERCOS

## Dermatology and Cosmetology Congress with International Participants

27 - 30 MARCH, 2019  
HILTON ISTANBUL BOSPHORUS HOTEL  
ISTANBUL, TURKEY



**Table. Dietary Intervention in Acne (Paleolithic-like diet)**

<b>Recommend</b>	<b>Restrict</b>
Balanced total calorie intake	Sugar and carbohydrates with high GI such as white bread, pizza, pasta, soft drinks, snacks
Sea fish and/or $\omega$ -3 fatty acids	Milk, especially skim milk
Vegetables and salads	Combinations of milk and sugar such as cornflakes, ice cream and milk chocolate
Fruits with low GI	Saturated and <i>trans</i> -fats (takeaway foods)
Plant-derived polyphenols such as green tea (EGCG), grapes and berries (resveratrol), curcumin and others	High iodide intake (seaweed, kelp)
Vitamin D substitution for individuals with proven vitamin D deficiency	Permanent snacking (hyperglycemic and salty foods)

### References:

1. Cordain L, Lindeberg S, Hurtado M, Hill K, Eaton SB, Brand-Miller J. Acne vulgaris: a disease of Western civilization. *Arch Dermatol.* 2002;138:1584-90.
2. Melnik BC, John SM, Schmitz G. Over-stimulation of insulin/IGF-1 signaling by western diet may promote diseases of civilization: lessons learnt from Laron syndrome. *Nutr Metab (Lond).* 2011;8:41.
3. Burris J, Rietkerk W, Shikany JM, Woolf K. Differences in dietary glycemic load and hormones in New York City adults with no and moderate/severe acne. *J Acad Nutr Diet.* 2017;117:1375-83.
4. Juhl CR, Bergholdt HKM, Miller IM, Jemec GBE, Kanter JK, Ellervik C7. Dairy intake and acne vulgaris: A systematic review and meta-analysis of 78,529 children, adolescents, and young adults. *Nutrients.* 2018;10(8). pii: E1049.
5. Agamia NF, Abdallah DM, Sorour O, Mourad B, Younan DN. Skin expression of mammalian target of rapamycin and forkhead box transcription factor O1, and serum insulin-like growth factor-1 in patients with acne vulgaris and their relationship with diet. *Br J Dermatol.* 2016;174:1299-307.
6. Melnik BC. Acne vulgaris: The metabolic syndrome of the pilosebaceous follicle. *Clin Dermatol.* 2018;36:29-40.
7. Feng Z. p53 regulation of the IGF-1/AKT/mTOR pathways and the endosomal compartment. *Cold Spring Harb Perspect Biol.* 2010;2:a001057.
8. Melnik BC. p53: key conductor of all anti-acne therapies. *J Transl Med.* 2017;15:195.
9. Shi G, Liao PY, Cai XL, Pi XX, Zhang MF, Li SJ, Quan JH, Fan YM. FoxO1 enhances differentiation and apoptosis in human primary keratinocytes. *Exp Dermatol.* 2018;27:1254-60.
10. Melnik BC, John SM, Agamia NF, Chen W, De Vita V, Karadag AS, Plewig G, Schmitz G. Isotretinoin's paradoxical effects in immortalized sebocytes. *Br J Dermatol.* 2018 Dec 22. doi: 10.1111/bjd.17579. [Epub ahead of print].



# 4<sup>th</sup> Indercos

## Dermatology and Cosmetology Congress with International Participants

27 - 30 MARCH, 2019  
HILTON ISTANBUL BOSPHORUS HOTEL  
ISTANBUL, TURKEY



### PROPIONIBACTERIUM IN DERMATOLOGY

Emin Özlü

Bacteria from the Propionibacterium genus is comprised of two main groups: cutaneous and classical. Cutaneous Propionibacterium comprises subtypes that are present on the human skin and in the mucosa of the digestive system, such as Propionibacterium acnes (P.acnes), Propionibacterium avidum, Propionibacterium propionicum, Propionibacterium granulosum, and Propionibacterium lymphophilum.

P. acnes is crucial for regulation of skin homeostasis, and prevents colonisation of harmful pathogens. P. acnes also contributes to the pathogenesis of acne vulgaris (AV). However, new findings on P. acnes suggest that its proliferation is not the triggering factor of AV. On the other hand, studies on the cutaneous microbiome show a decreased level of Propionibacterium in patients with psoriasis and atopic dermatitis. In this talk, the roles of propionibacterium in skin diseases will be reviewed and discussed.



# 4<sup>th</sup> INDERCOS

## Dermatology and Cosmetology Congress with International Participants

27 - 30 MARCH, 2019  
HILTON ISTANBUL BOSPHORUS HOTEL  
ISTANBUL, TURKEY



### ORAL CONTRACEPTIVES IN DERMATOLOGY

**Burçe Can Kuru**

Oral contraceptives can be divided into combined oral contraceptives (COCs) and mini-pills/progestin-only pills. They suppress ovulation and prevent pregnancy. The estrogen most commonly used is ethinyl estradiol while the progestin varies. Four COCs have FDA approval for acne in women who also want contraception. But in practice COCs are often prescribed solely for their androgen-modulating effects. COCs differ in the amount of synthetic estrogen (ethinyl estradiol or estradiol valerate) and the type of progestin, and are categorized as monophasic, multiphasic or extended cycle pills, depending on the distribution of hormones during the menstrual cycle. Most modern COCs contain between 20 mg (low dose pills) to 30/35 mg of ethinyl estradiol. Progestin evolves in four generations with four main structural classes: estranes (e.g. norethidrone), pregnanes (e.g. chlormandione acetate, norgestrel acetate), gonanes (e.g. levonorgestrel)/gonane derivatives (e.g. desogestrel), and non-ethylated estranes (e.g. drospirenone, dienogest). Progestins of the 3<sup>rd</sup> and 4<sup>th</sup> generations are potent progestational, antiestrogenic, antigonadotropic and minimally androgenic, while some can also reduce 5 $\alpha$ -reductase activity and partially block androgen receptor.

Estrogen's inhibition of ovarian and adrenal androgen production is dose-related. Estrogen also promotes synthesis of SHBG thereby reduce free testosterone and androgen receptors and inhibits 5 $\alpha$  reductase, decreases peripheral conversion of testosterone to DHT.

Main indications for dermatological use of COCs are acne and hirsutism, with generally low evidence of efficacy. Patients with mild to moderate acne, especially inflammatory acne associated with adult acne, polycystic ovary syndrome, and menstrual cyclical disorder seem to benefit more from the use of COCs. Anti-androgen effects of COCs decrease sebum production and sebocyte proliferation. COCs reduce inflammatory and non-inflammatory acne in women. However, there is limited data on the comparative effectiveness of various COC formulations, so the superiority of one type of COC can not be determined. COCs are an effective alternative for women with acne who have no contraindications. A meta-analysis found that although oral antibiotics appear to reduce lesion count more than COCs after three months of use, by six months, COCs and oral antibiotics had similar efficacy.

For an effective treatment of hirsutism, addition of other anti-androgens in combination with laser hair removal is normally required. COCs modulate hirsutism by reducing local testosterone levels and is considered first-line treatment for hirsutism. In a study comparing COCs to placebo or no treatment in women with hirsutism showed a greater reduction in hirsutism scores in patients treated with COCs. Improvements in hirsutism with COCs are not limited to those with abnormal serum androgen levels; studies comparing effects of COCs in normoandrogenic and hyperandrogenic women have shown similar improvement in hirsutism scores regardless of androgen status.

Some evidence suggests that COCs containing drospirenone (or cyproterone acetate, outside the US), which have minimal androgenic activity, are most effective for hirsutism. A meta-analysis found that drospirenone-containing COCs were associated with greater improvement than levonorgestrel-



# 4<sup>th</sup> INDERCOS

## Dermatology and Cosmetology Congress with International Participants

27 - 30 MARCH, 2019  
HILTON ISTANBUL BOSPHORUS HOTEL  
ISTANBUL, TURKEY



containing COCs which performed similarly to all other COCs.

Women over 35 years of age, smoking, obese, with hereditary thrombophilia, familial history of venous thromboembolism, liver disease and gynecological cancers are discouraged from using COCs. All the COCs bear certain risk for venous thromboembolism, with the risk of desogestrel, drospirenone, gestodene, and cyproterone 50-80% higher than that associated with the levonorgestrel. An increased risk of breast and cervical cancer that was seen in current and recent users appeared to be lost within approximately 5 years of stopping oral contraception, with no evidence of new cancer risks appearing later in life among ever users. Melasma is a common dermatologic side effect. The pathogenic role of synthetic estradiol/progesterone remains incompletely understood, in which the membrane-bound steroid hormone receptors were found to mediate the hormone actions.

### References

- Coenen CM, Thomas CM, Borm GF et al. Changes in androgens during treatment with four 481 low-dose contraceptives. *Contraception* 1996;53:171-6.
- De Bastos M, Stegeman BH, Rosendaal FR et al. Combined oral contraceptives: venous 507 thrombosis. *Cochrane Database Syst Rev* 2014;CD010813.
- Gierisch JM, Coeytaux RR, Urrutia RP et al. Oral contraceptive use and risk of breast, 515 cervical, colorectal, and endometrial cancers: a systematic review. *Cancer Epidemiol Biomarkers* 2013;22:1931-43.
- Sahin Y, Dilber S, Kelestimur F. Comparison of Diane 35 and Diane 35 plus finasteride in 575 the treatment of hirsutism. *Fertil Steril* 2001;75:496-500.
- Arowojolu AO, Gallo MF, Lopez LM et al. Combined oral contraceptive pills for treatment 610 of acne. *Cochrane Database Syst Rev* 2012;CD004425.
- Fruzzetti F, Bersi C, Parrini D et al. Treatment of hirsutism: comparisons between different 660 antiandrogens with central and peripheral effects. *Fertil Steril* 1999;71:445-51.





# 4<sup>th</sup> INDERCOS

## Dermatology and Cosmetology Congress with International Participants

27 - 30 MARCH, 2019  
HILTON ISTANBUL BOSPHORUS HOTEL  
ISTANBUL, TURKEY



### PHARMACOLOGICAL PROFILE OF BOTULINUM TOXIN

Kansu Büyükaşar

Botulinum toxin (BTX) is produced by autolysis of *Clostridium botulinum*, a gram-positive anaerobic bacterium. However, BTX-like proteins have also been identified in several non-clostridia. Chemically, BTX is a protein consisting of 7 related A-G toxins (serotypes). Each serotype can also be further divided into subtypes based on differences in amino acid sequence. BTXs are ~150 kDa proteins comprised of two major functional chains, i.e., a light chain (50kDa), and a heavy chain (100kDa), which are connected by a disulfide bond. The heavy chain is responsible for targeting the BTX to neuronal cell membrane. Each serotype binds via different mechanisms to different target receptors.

#### Botulinum Toxin Products

There are 4 most widely-used and commercially-available BTX products. These are the following:

**Botox**<sup>®</sup> (OnabotulinumtoxinA, Allergan-Ireland)

**Dysport**<sup>®</sup> (AbobotulinumtoxinA, Ipsen-France)

**Xeomin**<sup>®</sup> (IncobotulinumtoxinA, Merz-Germany).

**Myobloc**<sup>®</sup> (RimabotulinumtoxinB, Solstice Neuroscience-USA)

**Table 1.** Some features of most widely-used commercially-available botulinum toxin preparations.

	OnaA/BOTOX	AboA/Dysport	IncoA/Xeomin	RimaB/Myoblock
<b>Approval</b>	1989	1991	2005	2000
<b>Pharmaceutical forms</b>	Powder dissolved in injectable solution	Powder dissolved in injectable solution	Powder dissolved in injectable solution	Solution
<b>Serotype</b>	A1	A1	A1	B
<b>Size</b>	900 kDa	>500 kDa	150 kDa	700 kDa
<b>Excipients</b>	HSA (500 mg) NaCl	HSA (125 mg) Lactose	HSA (1 mg) Sucrose	HSA (500 mg/ml), NaCl Na-succinate
<b>pH value</b>	≈7	≈7	≈7	5.6
<b>Unit/vial</b>	50, 100, 200	300, 500	100, 200	2500, 5000, 10000
<b>Shelf life (months)</b>	36	24	36	24
<b>Toxin Quantity (ng/vial)</b>	5	4.35	0.6	25, 50, 100
<b>Re-constitution</b>	0.9% NaCl	0.9% NaCl	0.9% NaCl	Prepared solution
<b>Storage</b>	2-8 °C or <-5 °C	2-8 °C	Up to 25 °C	2-8 °C do not freeze

HSA: Human Serum Albumin. Modified from (1)



# 4<sup>th</sup> INDERCOS

## Dermatology and Cosmetology Congress with International Participants

27 - 30 MARCH, 2019  
HILTON ISTANBUL BOSPHORUS HOTEL  
ISTANBUL, TURKEY



All BTX-A clinical products currently available are dried-powder products that need to be reconstituted for use. Liquid formulation with different stabilizers and components, including the omission of excipients from animal origin and HSA is considered the next generation of toxin products (1).

**Industry Insights:** The global BTX market size is rising every year, and is expected to reach a value of USD 7.3 billion by 2025 due to the increasing number of aged people and demand to slow down aging. BTX offers a good alternative option to people to reach young phenotypic appearance with minimal invasive or non-invasive procedure.

### Pharmacology of Botulinum Toxin

**Mechanism of Action of BTX:** Botulinum toxin binds to neuronal cell membrane and is internalized by receptor-mediated endocytosis. Acidification of the endosome induces a conformational change of BTX-A structure, resulting in the translocation of the enzymatic light chain into the cytosol, which acts like a protease and cleaves **SNAP-25**, (synaptosomal nerve-associated protein 25), a presynaptic protein that takes an essential role in exocytosis of neurotransmitters. BTX blocks neuromuscular transmission in **motor** and **autonomic nerve** terminals by inhibiting the release of acetylcholine, resulting in a characteristic flaccid paralysis. BTX subtypes differ in cleavage SNARE complexes, e.g., BTX-A, BTX-C and BTX-E cleaves SNAP-25; however, BTX-B, BTX-D, BTX-F and BTX-G target synaptobrevin, the other important protein for exocytosis on the vesicle membrane. BTX-C also cleaves syntaxin, another key protein to neurotransmitter release (2,3,4,5,6,7).

**Table 2.** Cellular targets of BTX

BTX Type	BTX-A	BTX-B	BTX-C	BTX-D	BTX-E	BTX-F	BTX-G
Targets	SNAP-25	Synaptobrevin	SNAP-25 Syntaxin	Synaptobrevin	SNAP-25	Synaptobrevin	Synaptobrevin

**Site of Action of Botulinum Toxin:** BTX mainly exerts its action on motor neurons innervating striated voluntary muscles. However, BTX has also particular effects on smooth muscle reactivity and some other targets e.g., **sensory afferents**, whereby it induces an anti-nociceptive action via the inhibition of substance P release. Likewise, BTX can also attach to cell-surface proteins, such as E-cadherin, fibroblast growth factor receptor and vanilloid receptors. The toxin can also decrease the release of ATP, CGRP and NGF and down-regulate TRPV1 expression. Through the inhibition of vasodilator substances such as acetylcholine, CGRP and substance-P, and inhibition of muscle activity it may cause the reduction of vasodilatation within the affected muscle. High dose (50 U/mL) of BTX-A has also been demonstrated to inhibit release of norepinephrine from sympathetic nerve endings (that's why it is effective in Raynaud syndrome) (8). Interestingly, the BTX receptors and intracellular targets are not unique for neurotransmission, as several of these receptors and targets have been found in non-neuronal cells. Affected structures by BTX are mainly:

#### The neuromuscular junction

#### Autonomic ganglia

#### Postganglionic parasympathetic nerve endings

**Postganglionic sympathetic nerve endings** that release ACh such as those in some of skeletal muscles and eccrine sweat glands (Figure 1).



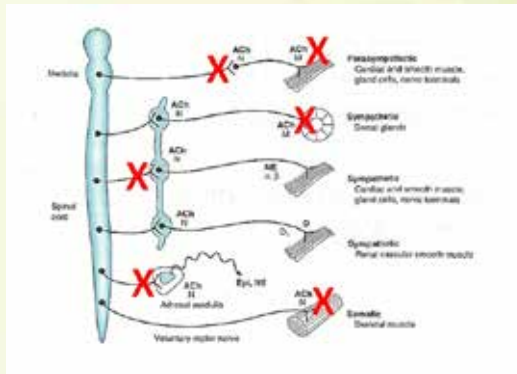
# 4<sup>th</sup> INDERCOS

## Dermatology and Cosmetology Congress with International Participants

27 - 30 MARCH, 2019  
HILTON ISTANBUL BOSPHORUS HOTEL  
ISTANBUL, TURKEY



**Non-neuronal targets** (SNAP-25-expressing non-neuronal cells such as epidermal keratinocytes, adipose-derived mesenchymal stem, nasal mucosal cells, urothelial cells, epithelial cells of intestine, prostate and alveoli, neutrophils, macrophages, dermal fibroblasts, sebocytes and vascular endothelial cells)



**Figure 1.** Site of action of botulinum toxin. BTXs act at neuromuscular junctions, autonomic ganglia, postganglionic parasympathetic nerve endings, postganglionic sympathetic nerve endings that release acetylcholine (e.g., eccrine sweat glands), modified from (9).

**Consequences of Action of Botulinum Toxin:** Once the action of BTX prevails, the neurotransmission is blocked and the muscle may atrophy. BTX induces weakness of striated muscle. Transmission is also inhibited at neurons in muscle spindles, which may alter reflex overactivity. BTX also induces an anti-nociceptive action via the inhibition of substance P. In human skin, BTX is good for all wrinkles evoked by persistent muscular contractions. It also elicits antiaging activity on the skin by increasing skin collagen production, decreasing to slow down muscle shortening, improving skin barrier and hydration, reducing sebum production, so improves skin quality. BTX facilitate wound healing and decrease thickness of hypertrophic scars. It also decreases axillary or palmar hyperhidrosis (1). Recovery from the toxin effect can occur by sprouting of nerve endings, and formation of new synaptic clefts. Additionally, extrajunctional acetylcholine receptors have been reported to develop.

**General Indications of BTX:** Approved uses of BTX are summarized in Table 3. However, the number of off-label indications of BTX is increasing day by day.



# 4<sup>th</sup> INDERCOS

## Dermatology and Cosmetology Congress with International Participants

27 - 30 MARCH, 2019  
HILTON ISTANBUL BOSPHORUS HOTEL  
ISTANBUL, TURKEY



**Table 3.** On-label indications of BTX.

Disorders	On-Label
<b>Skeletal Muscles</b>	Cervical dystonia Hemifacial spasm Blepharospasm Spasticity in adult and children
<b>Smooth Muscles</b>	Detrusor overactivity Neurogenic, idiopathic bladder overactivity
<b>Exocrine Gland Hyperfunction</b>	Sialorrhea Axillary hyperhidrosis
<b>Pain-Related Disorders</b>	Chronic migraine
<b>Aesthetic</b>	Glabellar lines Lateral canthal lines Front lines

**Off-Label Dermatological Indications of BTX:** BTX can also be used in a wide variety of unapproved indications such as, eye brow lifting, eye widening, gummy smile, jaw sculpting, Marionette lines, mental creases, dimpling of the chin, necklines and platysmal bands, perioral lines, masseter reduction, scarring, inflammatory skin diseases, alopecia, depression, chronic migraine, genodermatoses, pruritic diseases, hyperhidrosis, palmar hyperhidrosis, axillary bromhidrosis/chromhidrosis, other disorders of sweating, stump hyperhidrosis, pompholix, periorbital syringomas, eccrine angiomas, eccrine naevus, eccrine hydrocystoma, pruritic dermatoses, gustatory epiphora (crocodile tears), acantholytic disorders, genodermatoses (epidermolysis bullosa simplex and pachyonychia congenital), inflammatory dermatoses, pachydermoperiostosis pachydermia, wound healing, Raynaud phenomenon, persistent facial flushing/rosacea, spasticity, stroke, traumatic brain injury, cerebral palsy, multiple sclerosis, spinal cord injury, tics, chronic low back pain, disorders of localized muscle spasm and pain, tension headache, migraine headache, cervicogenic headache, achalasia cardia, Hirschsprung disease, Oddi sphincter dysfunction, chronic anal fissure, focal dystonias, cervical dystonia, blepharospasm, limb dystonia, laryngeal dystonia, oromandibular dystonia, orolingual dystonia, truncal dystonia. Unapproved uses of BTX are spreading day by day, e.g., refractory vulvodinia, vestibulodynia, vaginismus, dyspareunia, menopausal hot flashes, rosacea nasal tip, anterior neck and chest flushing.

**Adverse Effects of BTX:** Depending on its dose, site of injection, volume and individuals, there are numerous adverse effects of BTX. However, in general, it seems to be quite safe when injected locally without excess dose. The following are adverse effects of BTX: Allergic reactions, pain, edema, ecchymosis, and short-term hyperesthesia, bruising, infection (necrotizing fasciitis), delayed eyelid closure, brow ptosis, a decreased blink response, blepharoptosis, eye sensory disorders, excessive tearing and drooling, eyelid edema. In case of spreading of the toxin into the blood stream systemic side effects can be seen like generalized reactions such as nausea, malaise, flu-like symptoms and cutaneous eruptions. Headaches were





# 4<sup>th</sup> INDERCOS

## Dermatology and Cosmetology Congress with International Participants

27 - 30 MARCH, 2019  
HILTON ISTANBUL BOSPHORUS HOTEL  
ISTANBUL, TURKEY



the most frequent adverse events in the initial trial of BTX for the glabellar lines. Some of the side effects of BTX seem likely due to the injection technique. In the case of excessive doses of BTX it may be expected to produce neuromuscular weakness with a variety of symptoms. In the case overdose, the affected individual should be medically supervised for several weeks for signs and symptoms of systemic muscular weakness which could be local or distant from the site of injection. Antitoxin raised against botulinum toxin is available but it will not reverse any botulinum toxin-induced effects already apparent by the time of antitoxin administration.

**Contraindications:** Hypersensitivity reactions to formulation (toxin or albumin), neuromuscular disease (myasthenia gravis, Lambert-Eaton syndrome, ALS, motor neuropathies), psychological instability, pregnancy, lactating and children under 12-years, existing inflammatory lesions, like acne or psoriasis at the injection site(s). Besides, the patients with unrealistic expectations, and those using too much daily facial expressions (public performers) can also be considered in the list of contraindications. Furthermore, BTX does not work for the wrinkles not caused by muscular contractions.

**Drug Interactions:** The use of some medications decreasing neuromuscular transmission should be avoided in patients treated with BTX. Aminoglycoside-antibiotics, succinylcholine, curare-like neuromuscular-blockers and magnesium sulfate may increase effect of BTX. Some cholinergic medication (i.e., cholinesterase-inhibitors), penicillamine, quinine, chloroquine and hydroxychloroquine may reduce the toxin effect. Calcium channel blockers and anticoagulants, e.g., warfarin and aspirin may cause bruising and delay in coagulation.

**Application Routes of BTX:** Although BTX is given by i.m. injection there are some intradermal, transdermal, intradetrusor, transurothelial, and transepithelial delivery forms. Furthermore liquid and slow-release BTX formulations have also been developed. Topical liposomal BTX cream has also been developed for axillary hyperhidrosis. The use of BTX iontophoresis enhanced its penetration (for axillary hyperhidrosis). Transdermal delivery of BTX via jet nebulization for palmar, plantar, and axillary hyperhidrosis has also been tested. Topical formulation of BTX improves tolerability and adherence to therapy (1).

### Pharmacokinetics of Botulinum Toxin

**Metabolism/Elimination/Excretion:** The effect of blood on the structure, function, and biologic half-life of the toxin was investigated but it was found that blood did not alter the structure, catalytic activity, and the neuromuscular blocking activity of the toxin. Experimental studies conducted on mice and rats have shown that the elimination half-life for native (non-metabolized) toxin in blood and serum was around 230-260 min when given with the doses that produced clinical poisoning. On the other hand binding of BTX to plasma albumin was not so high (25-30%) and majority of the circulating toxin is free (around 70-75%) and available for distribution to vulnerable nerve-endings. Binding of neutralizing antibodies to BTX has been demonstrated to enhance the clearance of toxin from the circulation and enhance the tissue accumulation of toxin, particularly in liver and spleen (9).

**Action Duration of BTX:** The onset of action of BTX-A normally begins within 1-3 days; however, some individuals may necessitate as many as 5 days. Peak effects could be generally obtained at around 10 days. The toxin's effects last about 3-4 months. Some subtypes of BTX have different action duration, e.g., BTX-E



# 4<sup>th</sup> INDERCOS

## Dermatology and Cosmetology Congress with International Participants

27 - 30 MARCH, 2019  
HILTON ISTANBUL BOSPHORUS HOTEL  
ISTANBUL, TURKEY



and BTX-F have significantly shorter duration of response (3-6 weeks), which are especially required, in orthopedics and rehabilitation-medicine. However, novel formulations and delivery techniques enabling longer action duration, such as transdermal delivery or other formulations with a longer duration of response (i.e., 6-9 months) are needed for clinical interest.

**Spreading of BTX from Application Site:** It has been demonstrated that based on CMAP amplitude and/or cleaved SNAP-25 immunohistochemistry in remote muscles, all botulinum toxin products may spread from the area of injection to produce symptoms consistent with BTX effects. BTX-A has a potentially greater spread to nearby and remote non-injected muscles than BTX-B in mouse and primates. **BTX-CD** is the most prone to spread remotely; however, **BTX-D** is the least. Based upon safety index, the order was obtained: **BTX-F > BTX-C > BTX-D > BTX-E > BTX-A > BTX-CD > BTX-B**, with BTX-F being the safest. Some factors, e.g., volume, concentration, amount of toxin, formulation, serotype, needle-size, number of injections, precision of injection, biologic properties of the toxin, anatomy and tissue type of the target area, distribution of receptors, and SNARE proteins may influence spreading. Interestingly, when ranked Therefore, some effects of BTX conflict with the expected benefits, hence, require further attention (1, 10, 11,12, 13).

**Novel BTX Products:** Due to some disadvantageous features of BTX-A, more promising serotypes, e.g., biological and recombinant BTX-E products have already been developed for aesthetic and therapeutic indications. Another alternative to BTX-A, is serotype BTX-C, which induces similar efficacy and duration of action without secondary resistance after chronic use. This serotype was successfully tested in a pilot series of BTX-A-non-responsive patients with focal dystonia. The other promising subtype is **BTX-A2**, which seems to be more potent in vitro and in vivo than BTX-A1 due to its faster penetration to neuronal cells together with higher occupancy of the cellular receptors (SV2C). In addition, BTX-A2 has a less spreading and less immunogenic feature than BTX-A1, and it seems to be less susceptible to neutralization by human antisera raised to BTX-A1. However, accumulated data showing safety grade of BTX-A2 compared to BTX-A1 is needed.

**Novel Delivery Techniques for BTX:** The injection can be painful for patients and needs the specific training. Therefore, novel formulations of needle-free delivery and slow or sustained release formulations would be of clinical interest. These may include transdermal (TD) delivery or other products with a longer duration of response. FDA approved BTX cream based on ionic nanoparticle technology. There are several advantages of the cream over conventional injection such as self-application comfort, elimination of painful and traumatic needle use, For conditions such as hyperhidrosis, application can require multiple uncomfortable and painful subcutaneous injections in sensitive locations, such as the palm or axilla. Owing to the biological barriers limiting successful access of the BTX preparations to the intended tissue TD formulations will be for superficial delivery but not for deeper muscles, which means that they do not replace i.m. injections used for movement disorders at the moment. However, physical or chemical permeabilization that enables to BTX preparations to penetrate deeper layers has been developed. Accordingly, Revance Therapeutics Inc have progressed this approach for TD delivery of BTX-A to the clinic for both lateral canthal lines and axillary hyperhidrosis.

**Antibody Development against BTX:** One of the important issues in BTX use is antibody development



# 4<sup>th</sup> INDERCOS

## Dermatology and Cosmetology Congress with International Participants

27 - 30 MARCH, 2019  
HILTON ISTANBUL BOSPHORUS HOTEL  
ISTANBUL, TURKEY



against the toxin. Currently, in order to circumvent the issue of antibody development several other serotypes of BTX than BTX-A or BTX-B have been explored as potential therapeutic agents in humans. BTX-E and BTX-F seem to be alternative serotypes in patients who had become resistant to BTX-A and found to be effective in dystonic patients.

### References:

- Fonfria E, Maignel J, Lezmi S, Martin V, Splevins A, Shubber S, Kalinichev M, Foster K, Picaut P, Krupp J. The expanding therapeutic utility of botulinum neurotoxins. *Toxins (Basel)*. 2018;10(5), 208.
- Pearce LB, First ER, MacCallum RD, Gupta A. Pharmacologic characterization of botulinum toxin for basic science and medicine. *Toxicon*. 1997;35(9):1373-1412.
- Kim YI, Lomo T, Lupa MT, Thesleff S. Miniature end-plate potentials in rat skeletal muscle poisoned with botulinum toxin. *J Physiol*. 1984;356:587-599.
- Kumar R, Dhaliwal HP, Kukreja RV, Singh BR. The botulinum toxin as a therapeutic agent: Molecular structure and mechanism of action in motor and sensory systems. *Semin Neurol*. 2016, 36(1):10-9.
- Nakanishi ST, Cope TC, Rich MM, Carrasco DI, Pinter MJ. Regulation of motoneuron excitability via motor endplate acetylcholine receptor activation. *J Neurosci*. 2005;25(9):2226-2232.
- Whelchel DD, Brehmer TM, Brooks PM, Darragh N, Coffield JA. Molecular targets of botulinum toxin at the mammalian neuromuscular junction. *Mov Disord*. 2004;19 Suppl 8:S7-S16.
- Capek P, Dickerson TJ. Sensing the deadliest toxin: technologies for botulinum neurotoxin detection. *Toxins (Basel)*. 2010;2(1):24-53.
- Zhou Y, Liu Y, Hao Y, Feng Y, Pan L, Liu W, Li B, Xiao L, Jin L, Nie Z. The mechanism of botulinum A on Raynaud syndrome. *Drug Des Devel Ther*. 2018;12:1905-1915.
- Bertram G. *Katzung. Autonomic Drugs in Basic & Clinical Pharmacology*, Katzung, 9th Ed. 2004, pp.76
- Nigam PK, Nigam A. Botulinum toxin. *Indian J Dermatol*. 2010;55(1):8-14.
- Ravichandran E, Gong Y, Al Saleem FH, Ancharski DM, Joshi SG, Simpson LL. An initial assessment of the systemic pharmacokinetics of botulinum toxin. *J Pharmacol Exp Ther*. 2006 Sep;318(3):1343-1351.
- Shaari CM, George E, Wu BL, Biller HF, Sanders I. Quantifying the spread of botulinum toxin through muscle fascia. *Laryngoscope*. 1991;101(9):960-964.
- Yaraskavitch M1, Leonard T, Herzog W. Botox produces functional weakness in non-injected muscles adjacent to the target muscle. *J Biomech*. 2008;41(4):897-902.
- Yucesoy CA, Emre Arıkan Ö, Ateş F. BTX-A administration to the target muscle affects forces of all muscles within an intact compartment and epimuscular myofascial force transmission. *J Biomech Eng*. 2012;134(11):111002.
- Yucesoy CA, Ateş F. BTX-A has notable effects contradicting some treatment aims in the rat triceps surae compartment, which are not confined to the muscles injected. *J Biomech*. 2018;66:78-85.



# 4<sup>th</sup> INDERCOs

## Dermatology and Cosmetology Congress with International Participants

27 - 30 MARCH, 2019  
HILTON ISTANBUL BOSPHORUS HOTEL  
ISTANBUL, TURKEY



### **FILLERS: 8-POINT LIFT APPROACH**

**Andreas Katsambas**

The 8-point lift is a volumizing and lifting facial procedure also referred to as “non-surgical facelift” or “liquid facelift”. It is delivered in 8 distinct treatment areas to achieve the most natural results. Traditionally, there are many techniques whereby large boluses of fillers are placed in specific areas. This can create inappropriate projection resulting in unnatural results, both in repose and animation. In the 8-point lift technique, minimal amounts of the product are used, with specific placements, in order to achieve the desired lift effect with a more natural outcome.

Important aspects to consider are: “what product to inject”, “where to inject”, “where NOT to inject”, “what sequence to inject and how much to inject”.

In general, the 8-point lift approach is a safe treatment. Some side effects include mild swelling and redness which subsides within 24 hours. Possible bruising and needle marks may be evident but are temporary.

Results are best evaluated at week 2 and 4 after treatment. It is important to avoid touching the injected site for 24 hours and the use of make-up for 12 hours. Sunbeds and sunlight should also be avoided for 2 weeks as well as any further treatments or procedures for 7 days.





# 4<sup>th</sup> INDERCOS

## Dermatology and Cosmetology Congress with International Participants

27 - 30 MARCH, 2019  
HILTON ISTANBUL BOSPHORUS HOTEL  
ISTANBUL, TURKEY



### LONG PULSE ND: YAG LASERS IN AESTHETIC DERMATOLOGY

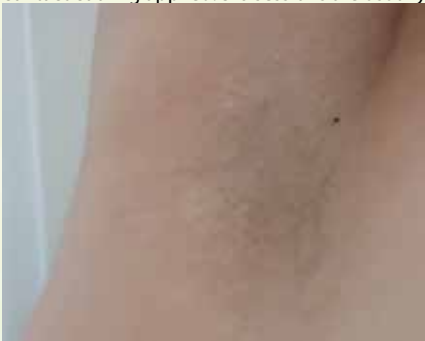**Tamer İrfan Kaya**

The Nd:YAG laser has been used mainly for leg veins, hair removal, and skin rejuvenation.

#### **Hair Removal**

The long pulsed Nd:YAG is the safest laser for hair removal in darker skin types. The wavelength of the Nd:YAG (1064 nm) is at the end of the absorption spectrum of melanin. This wavelength is sufficient to achieve significant thermal injury in dark coarse hairs while sparing epidermal pigment. The target chromophores, primarily melanin-rich hair shafts, are located deep in human skin (bulge around 1.5 mm and bulb at 2-7 mm). As a result, long pulse widths on the order of milliseconds and high fluencies capable of heating large volumes of tissue are required. Millisecond-domain Nd:YAG lasers using high light doses can produce selective injury to human hair follicles resulting in permanent hair loss. The Nd:YAG laser produces light with a wavelength of 1064 which is poorly absorbed by superficial tissues, pronounced scattering up to 5mm occurs. In this way, most follicles may be targeted (1-5).

We prefer to use 10mm spot size to treat medium to coarse hair. First, we determine the patient's skin type and select the settings accordingly. For skin type I-II, fluence 50-60J/cm<sup>2</sup>, with pulse width 50-65msec is preferred. For skin type III and IV, fluence 35-45J/cm<sup>2</sup>, with pulse width 50-60msec is preferred. We usually do not have skin type V and VI patients. The area to be treated should be shaved and ultrasound gel and contact cooling applied. 5-8 sessions are usually necessary (Figure 1).



**Figure 1.** Permanent hair removal of axillae after 8 sessions of Nd:YAG laser. The photo was taken 3 years after the last session.

#### **Leg Vein Treatment**

Nd:YAG laser (1064nm) was appointed as treatment of choice for unsightly leg vessels. Due to a low absorption coefficient of oxyhaemoglobin at 1064 nm, no gradient of light energy should appear inside large vessels. Thus, the homogeneous distribution of photons inside large vessels should lead to a



# 4<sup>th</sup> INDERCOS

## Dermatology and Cosmetology Congress with International Participants

27 - 30 MARCH, 2019  
HILTON ISTANBUL BOSPHORUS HOTEL  
ISTANBUL, TURKEY



homogeneous heating and longer wavelengths are more likely to heat the vessel uniformly. Therefore, Nd:YAG at 1064 nm is the preferred laser for treatment of large vessels such as leg veins (1,6).

In the treatment of leg veins with Nd:YAG laser at 1064 nm, clinical studies seem to use various pulse durations, which can range from 5 to 100 ms, or the fluence (100–400 J/cm<sup>2</sup>). Relatively high temperatures are obtained for a 6-mm, in comparison with a 2.5-mm spot size. Thus, the spot size of Nd:YAG laser at 1064 nm should be kept as small as possible. Spot size should be about 25% larger than the maximum vessel size of the leg veins that are being treated. Pulse duration of 30–60 ms range were used successfully in most clinical studies. The main goal of laser treatment of leg veins is vessel closure that can be seen clinically. If the vessel does not close in particular in small vessels with diameters < 0.5 mm. The problem with small vessels is due to the low light absorption of oxyhaemoglobin at 1064 nm together with the low number of light-absorbing erythrocytes in small vessels. To overcome this problem, one can increase the fluence up to 300 J/cm<sup>2</sup> to achieve coagulation. Such a high fluence leads to an increased risk of side-effects (1,6,7).

We prefer 3mm spot size for the leg veins 2mm or smaller than 2mm. The preferred pulse width is 50-60 msec and fluence is 250-340J/cm<sup>2</sup>. Ultrasound gel and contact cooling applied. Contact should be maintained with the treatment area, pressure should not be applied with the hand piece or the vessel will blanch. A longer pulse width should be chosen for darker skin types. Treatment should begin at the lowest fluence level, fluence can be increased until vessel blanches or disappears.

### **Skin Rejuvenation**

Different types of laser are used for resurfacing and collagen remodeling in cutaneous laser surgery. The effect of laser resurfacing is more powerful with the ablative fractional laser than with nonablative laser devices, although there has been growing demand for the short downtime and minimal side effects associated with ablative lasers, which has incited development of non-ablative lasers. Non-ablative laser devices exert their effects by inducing dermal collagen production while sparing the epidermis (8-10). Here are some of our experiences and suggestions. Wrinkle reductions are subtle and will begin to be evident after a series of treatments. Contact cooling must be maintained at all times. There are several important cautions for this treatment. Lower fluences over bony and thin-skinned areas should be used. Larger deeper facial vessels should be avoided, for example in the temporal area. Within the periorbital ridge never to be used. The eyebrow area and beard area in men should be avoided to reduce the chance of unintended hair reduction. Teeth should be protected with folded wet gauze pads while treating in that area. Longer pulse widths and lower fluence should be used on darker skin types. Forehead, upper lip and temples should be covered in one direction. Over the cheeks and chin, covering twice in different directions can be performed.



# 4<sup>th</sup> INDERCOS

## Dermatology and Cosmetology Congress with International Participants

27 - 30 MARCH, 2019  
HILTON ISTANBUL BOSPHORUS HOTEL  
ISTANBUL, TURKEY



### References:

1. Christiansen K1, Drosner M, Bjerring P. Optimized settings for Nd:YAG laser treatments of leg telangiectasias J Cosmet Laser Ther. 2015;17:69-76.
2. Puri N. Comparative Study of Diode Laser Versus Neodymium-Yttrium Aluminum: Garnet Laser Versus Intense Pulsed Light for the Treatment of Hirsutism. J Cutan Aesthet Surg. 2015;8:97-101.
3. Bencini PL1, Luci A, Galimberti M, Ferranti G. Long-term epilation with long-pulsed neodymium:YAG laser. Dermatol Surg. 1999 Mar;25(3):175-8.
4. Lévy JL1, Trelles MA, de Ramecourt A. Epilation with a long-pulse 1064 nm Nd:YAG laser in facial hirsutism. J Cosmet Laser Ther. 2001 Dec;3(4):175-9.
5. Ross EV, Ladin Z, Kriendel M, Dierickx CC. Theoretical considerations in laser hair removal. Dermatol Clin 1999; 17:333-355.
6. Bäumlér W, Ulrich H, Hartl A, Landthaler M, Shafirstein G. Optimal parameters for the treatment of leg veins using Nd:YAG lasers at 1064 nm. Br J Dermatol. 2006;155:364-71.
7. Parlette EC, G roff WF, K inshella MJ , D omankevitz Y , O ' Neill J , Ross EV . Optimal pulse durations for the treatment of leg telangiectasias with a neodymium YAG laser . Lasers Surg Med. 2006 ; 38 : 98 – 105 .
8. Robati RM, Asadi E, Shafiee A, Namazi N, Talebi A. Efficacy of long pulse Nd:YAG laser versus fractional Er:YAG laser in the treatment of hand wrinkles. Lasers Med Sci. 2018;33:461-467. doi: 10.1007/s10103-017-2351-2.
9. Oktem A, Kocyigit P. Comparison of effectiveness of 1,064-nm Nd:YAG laser and Nd:YAG laser-IPL combination treatments in hand skin rejuvenation. J Cosmet Laser Ther. 2016;18:270-4.
10. Trelles MA, Alvarez X, Martín-Vázquez MJ, Trelles O, Velez M, Levy JL, Allones I. Assessment of the efficacy of nonablative longpulsed 1064-nm Nd:YAG laser treatment of wrinkles compared at 2, 4, and 6 months. Facial Plast Surg. 2005;21:145-153.



# 4<sup>th</sup> INDERCOS

## Dermatology and Cosmetology Congress with International Participants

27 - 30 MARCH, 2019  
HILTON ISTANBUL BOSPHORUS HOTEL  
ISTANBUL, TURKEY



### **NASAL FILLER AUGMENTATION: TECHNICAL CONSIDERATIONS AND COMPLICATIONS**

**Tilemachos L. Anthopoulos**

Since ancient times, man has considered the nose to be the key feature, of facial appearance. As the central and most prominent part of the human face, the nose contributes to determine the beauty of a person significantly. Certain ancient populations, particularly in India, had the common tradition to cut off a person's nose as an act of humiliation to thieves and prisoners of war. Ancient Greeks (Hippocrates) described treatments and techniques applied to the restoration of injured noses. He classified nasal injuries, from simple contusions of soft tissues to complicated fractures. Even in our days, the nose is the central and most prominent feature on the human face; and on its shape, size, and appearance depends the relative facial beauty of the person.

Considering that, rhinoplasty is the most common facial procedure performed for women and the second most common for men and patients are increasingly requesting, low cost and less invasive but definitely effective, procedures with minimal downtime and instant results, make sense why, filler rhinoplasty, has grown fashionable in some countries. A variety of filler materials are currently available, of these, hyaluronic acid (HA), calcium hydroxyapatite (CaHA) and silicone have most frequently been used for treating nasal deformities. HA and CaHA are much safer than silicone (causing severe granulomatous reactions), but still may lead to complications (trivial to severe) such as infection, allergic reactions, thinning of skin envelope and necrosis. The mechanism leading to tissue necrosis after filler injection is mainly caused by intra- and extravascular factors. Physicians should always take under consideration, as an early stage diagnosis step, pain and skin color change to blue, due to the fact that these two factors could be the only early symptoms and signs.

Filler rhinoplasty is an alternative method for patients who, for any reason (medical, financial), do not wish to undergo surgery. This presentation will give information for technical considerations and complications regarding non-surgical rhinoplasty.

[The first «fillers», vaseline and paraffin. From miracle to disaster].Glicenstein J. *Ann Chir Plast Esthet.* 2007 Apr;52(2):157-61

Injection rhinoplasty: non-surgical nasal augmentation and correction of post-rhinoplasty contour asymmetries with hyaluronic acid: how we do it. Bray D, Hopkins C, Roberts DN. *Clin Otolaryngol.* 2010 Jun;35(3):227-30.

Nonsurgical rhinoplasty using dermal fillers. Jasin ME. *Facial Plast Surg Clin North Am.* 2013 May;21(2):241-52. Injection Rhinoplasty Using Filler. Moon HJ. *Facial Plast Surg Clin North Am.* 2018 Aug;26(3):323-330.

Use of Fillers in Rhinoplasty. Moon HJ. *Clin Plast Surg.* 2016 Jan;43(1):307-17.

Filler Rhinoplasty Evaluated by Anthropometric Analysis. Youn SH, Seo KK. *Dermatol Surg.* 2016 Sep;42(9):1071-81

Vascular complications of hyaluronic acid fillers and the role of hyaluronidase in management. Kim DW, Yoon ES, Ji YH, Park SH, Lee BI, Dhong ES. *J Plast Reconstr Aesthet Surg.* 2011 Dec;64(12):1590-5.

Soft tissue fillers in the nose. Humphrey CD, Arkins JP, Dayan SH. *Aesthet Surg J.* 2009 Nov-Dec;29(6):477-84

Nonsurgical rhinoplasty using dermal fillers. Jasin ME. *Facial Plast Surg Clin North Am.* 2013 May;21(2):241-52.

Extensive necrosis after injection of hyaluronic acid filler: case report and review of the literature. Kassir R, Kolluru A, Kassir MJ. *Cosmet Dermatol.* 2011 Sep;10(3):224-31.





# 4<sup>th</sup> INDERCOS

## Dermatology and Cosmetology Congress with International Participants

27 - 30 MARCH, 2019  
HILTON ISTANBUL BOSPHORUS HOTEL  
ISTANBUL, TURKEY



### **ADIPOSE TISSUE DERIVED STEM CELLS AND ANTIAGING**

**John C. Katsantonis**

Human body adipose tissue, as derived from embryonic mesenchyme, has been shown to contain a vast number of Multipotent Stem Cells (ASCs).

These cells are possessing 1) self-renewal capacity, 2) long-term viability, 3) multilineage potency and 4) have been demonstrated to display serious immunologic properties.

Based on the above, we tried to investigate the effect of infusing homologous ASCs mixed with a Hyaluronic Acid (HA) scaffold into the dermis of adult photodamaged – photoaged skin.

Serial skin biopsies demonstrated remarkable rejuvenating effect:

- increased epidermal -keratinocyte proliferation
- striking collagen remodeling
- intense neoangiogenesis.

To extend clinical observation of injected homologous ASCs bidden to a HA scaffold as an antiaging factor, we studied the effect on the face of middle aged females.

The study was concluded using the Visia computerized imaging system.

The results are highly suggestive of the ASCs antiaging properties.



# 4<sup>th</sup> INDERCOs

## Dermatology and Cosmetology Congress with International Participants

27 - 30 MARCH, 2019  
HILTON ISTANBUL BOSPHORUS HOTEL  
ISTANBUL, TURKEY



### **BLEPHAROPLASTRY TECHNIQUES & COMBINATION TREATMENTS**

**Konstantin Neamonitos**

Blepharoplasty is a surgical operation for cosmetic and functional purposes.

The target of blepharoplasty is to remove excess skin and parts of fat pads of the upper and lower eye lids. The combination treatments of Laser Blepharoplasty and Laser Resurfacing of the orbital area can be very effective if they are performed methodically and carefully and they have the desired results on the upper – lower eyelids, tear trough, periorbital and cheek wrinkles.



# 4<sup>th</sup> INDERCOS

## Dermatology and Cosmetology Congress with International Participants

27 - 30 MARCH, 2019  
HILTON ISTANBUL BOSPHORUS HOTEL  
ISTANBUL, TURKEY



### Q-SWITCHED ND YAG LASERS FOR DERMATOLOGY

Belma Türsen

Pigmented skin lesions are exceedingly common. They can be classified either based on location of pigment or causation as (epidermal/dermal/nevoid/hereditary/acquired). Pigmented lesions are previously treated with destructive nonselective lasers. In the last decade; nonablative highly pigment-specific QS laser devices are widely used. Melanin has a broad absorption spectrum (630-1100 nm); absorption decreasing with higher wavelengths. A property that allows to be treated with a wide variety of lasers. The length of the pulse duration is an important characteristic of any pulsed laser/light device. Pulses lasting a few milliseconds are generally characterized as long pulses. Nanosecond pulses are considered short. Q-switched NdYAG laser pulses are typically 3-10 nanoseconds in length. QS technique allows the delivery of extremely powerful laser pulses with high peak power within short pulse duration. Following the theory of selective photothermolysis, melanosomes and tattoo particles are selectively targeted without much damage to the surrounding area.

#### Types of QS Lasers

- Q-switched Ruby – An aluminum oxide crystal that lases at 694nm. These are used in the removal of blue black and green pigments.
- Q-switched Nd:YAG – is named after the laser medium, neodymium yttrium aluminum garnet, that lases at two wavelengths, 532nm (green) & 1064nm (IR). These are pulsed at 10ns with intensities. Spot size varies from 0.8-8mm and treatments of 1-2 J/cm<sup>2</sup> for red pigments and 5-6 J/cm<sup>2</sup> for blues/greens are common. These are used in the removal of red (532nm) and black and blue pigments (1064nm).
- Q-switched Alexandrite – a crystal which lases at 755nm. Useful in the removal of black, blue and green pigments.
- Q-switched is an abbreviation for 'quality-switched'

Pigmented epidermal lesions: Because deep tissue penetration is not necessary, the epidermal lesions respond best to 532 nm while the dermal lesions are better treated with 1064 nm.

Lentigines: Usually 1-2 sessions are enough to clear lentigines with 532 nm. There is a risk of hypo/hyperpigmentation. Avoidance of sun exposure for 4-6 weeks post-laser is very important.

Cafe-au lait macules: They can be treated effectively in 1-2 sessions. Recurrence is common in up to 50% of treated lesions; even when clearance is achieved which requires multiple treatments.

Freckles: Response is same as for lentigines. With one treatment at least 50% clearing of lentigines is expected. Although very effective, risk of dyspigmentation exists. Other epidermal lesions are nevus spilus and Becker's nevus.

Tattoo: QS lasers are gold standard for treatment of tattoos. Q-switched NdYAG 1064 nm, due to its longer wavelength, higher fluence, and shorter pulse, has emerged as a better laser for the black and dark blue/black tattoo pigment. The side effects of earlier lasers are remarkably low. However for colored pigments, use of multiple wavelengths is mandatory. Response to Q-switched 1064 nm depends on the type of tattoo. Types of tattoos are as below;

1. Professional tattoos: Most of such tattoos have even distribution of ink, mainly in subcutaneous tissue. Ink quality is good; hence, 6-10 treatments are usually required.

2. Decorative Amateur & Cultural tattoos: Usually these are easy to remove, but in some cases, if the ink is



# 4<sup>th</sup> INDERCOS

## Dermatology and Cosmetology Congress with International Participants

27 - 30 MARCH, 2019  
HILTON ISTANBUL BOSPHORUS HOTEL  
ISTANBUL, TURKEY



at deeper level, a few extra sessions could be required. These tattoos consist of primarily black India Ink. Tattoos are placed superficially and unevenly in the dermis and respond well to laser treatment with only 4-6 sessions.

**3. Cosmetic tattoos:** Cosmetic tattoos like eyebrows, and eye and lip line are mostly made of iron-based inks. This can sometimes oxidize and turn black, so a test patch must be given. Iron has two oxidation states: ferrous oxide which is black and ferric oxide which is red-brown in color.

**Dermal pigmented lesions:** Nevus of Ota, Nevus of Ito, mongolian spots, Hori's nevus, ABNOMs (acquired bilateral nevus of Ota like macules), other flat pigmented birthmarks and Riehl's melanosis respond well at 1064 nm. Multiple sessions are usually required with near-total clearing of the lesion in most cases. Recurrence rate for Ota nevus is %1-2. Sun exposure and pregnancy may be considered as the reason. They develop at the previous site usually.

**Medium depth nonablative skin resurfacing:** QSNLY is a well-established technology for treating photoaging. When used at lower fluences with a larger spot size, it is a medium depth laser peel, with less downtime and high patient satisfaction. Improvement of pore size, skin texture and tone summarizes the rejuvenation effect. In contrast to previous belief topical carbon application does not enhance laser efficacy.

**Melasma:** Numerous lasers and light devices are used in melasma with unsatisfactory results and pigmentation frequently recurs. It is clear that laser can not be the first line treatment but it can be used as an adjuvant therapy in resistant melasma with selected patients. Epidermal melasma responds better and faster than dermal/mixed melasma. Complete clearing of lesions may be expected in more than 50% of cases of epidermal melasma. Complete clearing of dermal/ mixed melasma may be seen in about 30-50% cases, while the remaining cases will show moderate improvement. Postinflammatory hyperpigmentation and rebound melasma are dreaded complications that may occur in the individual with sensitive skin. Lower energy and fewer repetitions are adequate to produce marked improvement. It is not recommended as monotherapy. Combination treatments (lasers peels and oral adjuvants) are recommended.

**Nonablative skin resurfacing for wrinkles and acne scars:** Using laser energy that penetrates deeply without injuring the top layer of skin, the deep dermis is stimulated to produce natural collagen and other vital proteins that make up healthy, youthful skin. Painlessly done in less than 20 minutes, your patient will leave the office with only mild redness that will fade within a few hours. After 3-6 treatments, done at monthly intervals, wrinkles soften, and skin gets toned. Hence it is also referred to as 'laser skin toning'. This is a good option for improving acne scars, wrinkles, and stretch marks without complicated procedures and long recovery times.

**Laser-assisted hair reduction:** Though the long-pulsed lasers are gold standards for the removal of terminal hair, Q-switched laser has been tried also with or w/o carbon. Q-switched pulses produce a photomechanical impact on the tissue and also on hair shaft and hair follicle, causing reduction as well as delay in hair growth cycle. Since it is not color dependent, it can be suited for all skin types, even on tanned skins.

**Vascular lesions:** QS lasers are shown to be effective in treating vascular lesions like telangiectasia, cherry angiomas, and small spider nevi. More than one treatment could be required. However, it can cause purpura which could take up to a week to clear.

**Dark lips:** They are a common cosmetic concern in India. Two to four sessions of Q-switched 532 nm are an effective treatment for lip lightening.





# 4<sup>th</sup> INDERCOS

## Dermatology and Cosmetology Congress with International Participants

27 - 30 MARCH, 2019  
HILTON ISTANBUL BOSPHORUS HOTEL  
ISTANBUL, TURKEY



**Tinea unguium:** QS-Ndyag laser appears to be a promising treatment for onychomycosis by both photothermal and photomechanical effect. By reducing yeast invasiveness in keratinocytes, downregulating the inflammation and helping the cytoprotection and antimicrobial defense against the fungus; laser may be combined with conventional therapy.

**Postinflammatory hyperpigmentations:** It might be due to drugs such as minocycline, amiodarone, imipramine, and also it can be paradoxical like parenteral gold.

The following complications are transient reactions and do not require termination of treatment:

- Immediate erythema
- Physical urticaria
- Acneiform eruption
- Minute petechiae
- Whitening of fine hair
- Rebound hyperpigmentation

The following complications need either stopping the laser therapy or modification of laser parameters:

- Mottled hypo and hyperpigmentation
- Leukoderma
- Severe urticaria
- Severe acneiform eruption
- Herpes simplex activation

Ghost shadows and scarring can occur with tattoo treatment at higher fluences

**Management of complication:** Prognosis is excellent once the right treatment indication; skin type; duration of the therapy is considered well before laser treatment. The most common complications observed with pigmented lesions are postinflammatory hyperpigmentation especially when treating dark skinned patients. It is better to use pretreatment hydroquinone for 4-6 weeks to reduce the recurrence and PIH. Hypopigmentation is less common and particularly occurs when treating tanned patients. If hypopigmentation occurs, the fluence should be reduced and also treatment interval doubled. If hypopigmentation is speckled, this required cessation of treatment and adopting the medical line of treatment like azelaic acid, kojic acid, etc. Hydroquinone containing preparations must be avoided. After a period of 2-3 months, once the hypopigmentation resolves, laser can be restarted at a lower fluence (less than 2.5 J/cm<sup>2</sup>).

**Combinations with QS-Lasers:** For faster resolution of lesions as well as to increase the efficacy, laser treatment in some conditions can be combined with topical bleaching agents, for example, 7% arbutin, Kligman's formula, intralesional or oral tranexamic acid; vitamin C, topical sunscreen, chemical peels such as glycolic acid, Jessner's peels, microdermabrasion, long pulsed lasers/IPL, microneedling/dermaroller

**Conclusion:** Considering its multiple applications; QSNDY is definitely a 'must' in a cosmetic setup. The search for an ideal laser for pigmented lesions is continuing. We still can not treat melasma effectively. We still have problems like scarring, ghost shadows, etc. with tattoos. However, with Q-switched technology we certainly have found answers to some of the previously untreatable conditions. Femtosecond domain lasers are being developed and picosecond lasers currently used for tattoo removal are being investigated for pigmented lesions. It will be interesting to see how the picosecond lasers will impact melasma patients.



# 4<sup>th</sup> INDERCOS

## Dermatology and Cosmetology Congress with International Participants

27 - 30 MARCH, 2019  
HILTON ISTANBUL BOSPHORUS HOTEL  
ISTANBUL, TURKEY



### References:

- Choi JE, Lee DW, Seo SH, Ahn HH, Kye YC. Low-fluence Q-switched Nd:YAG laser for the treatment of melasma in Asian patients. *J Cosmet Dermatol*. 2018; 17(6):1053-1058.
- Kwon HH, Choi SC, Jung JY, Park GH. Combined treatment of melasma involving low-fluence Q-switched Nd:YAG laser and fractional microneedling radiofrequency. *J Dermatolog Treat*. 2018; 28:1-5.
- Aurangabadkar SJ. Optimizing Q-switched lasers for melasma and acquired dermal melanoses. *Indian J Dermatol Venereol Leprol*. 2019;85(1):10-17
- Vachiramon V, Iamsung W, Triyankulsri K. Q-switched double frequency Nd:YAG 532-nm nanosecond laser vs. double frequency Nd:YAG 532-nm picosecond laser for the treatment of solar lentigines in Asians. *Lasers Med Sci*. 2018;33(9):1941-1947.
- Bakus AD, Yaghmai D, Massa MC, Garden BC, Garden JM. Sustained Benefit After Treatment of Acne Vulgaris Using Only a Novel Combination of Long-Pulsed and Q-Switched 1064-nm Nd:YAG Lasers. *Dermatol Surg*. 2018;44(11):1402-1410.
- Liu Y, Zeng W, Li D, Wang W, Liu FA. Retrospective analysis of the clinical efficacies and recurrence of Q-switched Nd:YAG laser treatment of nevus of Ota in 224 Chinese patients. *J Cosmet Laser Ther*. 2018; 20(7-8):410-414
- Sirithanabadeekul P, Srieakpanit R. Intra-dermal tranexamic acid injections to prevent post-inflammatory hyperpigmentation after solar lentigo removal with a Q-switched 532-nm Nd:YAG laser. *J Cosmet Laser Ther*. 2018; 5:1-7.
- Zawar V, Sarda A, De A. Clearance of Recalcitrant Onychomycosis Following Q-switched Nd:Yag Laser. *J Cutan Aesthet Surg*. 2017;10(4):226-227.
- Qin Y, Qin X, Xu P, Zhi Y, Xia W, Dang Y, Gu J, Ye X. Potential role of S100A8 in skin rejuvenation with the 1064-nm Q-switched Nd:YAG laser. *Lasers Med Sci*. 2018;33(3):581-588.
- Choi YJ, Nam JH, Kim JY, Min JH, Park KY, Ko EJ, Kim BJ, Kim WS. Efficacy and safety of a novel picosecond laser using combination of 1064 and 595 nm on patients with melasma: A prospective, randomized, multicenter, split-face, 2% hydroquinone cream-controlled clinical trial. *Lasers Surg Med*. 2017;49(10):899-907



# 4<sup>th</sup> INDERCOS

## Dermatology and Cosmetology Congress with International Participants

27 - 30 MARCH, 2019  
HILTON ISTANBUL BOSPHORUS HOTEL  
ISTANBUL, TURKEY



### **ACNE, PSORIASIS, AUTOIMMUNE BULLOUS DISEASE, SKIN CANCERS, SYSTEMIC MEDICATION AND DIET, GLUTEN IN DERMATOLOGY**

#### **Ilkin Zindanci**

Diet plays an important role in dermatological diseases, as it does in many other diseases. The requirement of a diet related to the disease is the leading question, that the dermatologists receive. The importance of nutrition becomes more prominent in the etiopathogenesis, progression, and treatment of some skin diseases.

In some diseases, such as Dermatitis herpetiformis (DH), the absolute role of nutrition is known and this profound the basis of the treatment process. DH is a rare autoimmune disease linked to gluten sensitivity. It is currently considered to be the specific cutaneous manifestation of celiac disease. The one of the major options for the treatment of DH is gluten-free diet (GFD). DH is related to the oral intake of the gluten proteins derived from wheat, barley and rye. Therefore, GFD is a cause-based therapy for DH. Both the rash and enteropathy improve with the diet treatment.

Recently, it is emphasized, that nutrition has a significant and irrefutable role in diseases, especially acne vulgaris, atopic dermatitis (AD), psoriasis, chronic urticaria (CU) and pemphigus vulgaris. High glycemic index foods, milk and dairy products has been shown as a reason of acne increasing. The role of diet in the cause and treatment of AD is very controversial. It is suggested that prenatal followed by postnatal probiotic supplementation and postnatal prebiotic supplementation decrease the risk of AD, exclusive breastfeeding and supplementation with hydrolyzed formula is protective against AD for high-risk infants. Weight loss and decreased alcohol consumption improve psoriasis symptoms and may increase the efficacy of some psoriasis medications. Dietary supplementation with polyunsaturated fatty acids, folic acid, vitamin D, and antioxidants can be considered as adjuncts in the management of some psoriasis patients. Interventional trials support the benefit of a pseudoallergen-free diet and vitamin D supplementation for patients with CU. Given its low cost and safety profile, a pseudoallergen-free diet can be recommended to a subset of CU patients. A GFD may ameliorate CU symptoms in patients who have concomitant celiac disease. Appropriate dose of vitamin D supplements can help in the treatment. Clinical evidence supports the role of dietary factors in the maintenance and exacerbation of pemphigus. Dietary factors suspected of being inducers of pemphigus are known to contain thiol compounds (garlic, leek, chives), phenols (black pepper, red chillies), tannins (tea, red wine, spices), isothiocyanates (mustard, horseradish, cauliflower), and phytyocyanins.

It is controversial that some supplement additions to or subtractions from the nutrition decreases the risk of the formation of melanoma, or nonmelanoma skin cancers (NMSC). Insufficient evidence exists to recommend supplementation with polyunsaturated fats, vitamins D and E, selenium, green tea, resveratrol, and lycopene to prevent the development or progression of melanoma in the general population. Decreased alcohol intake and vitamin D supplementation may lower melanoma risk in high-risk patients. Selenium supplementation may increase the risk of squamous cell carcinoma and total NMSC and should be avoided. The effect of retinol and retinoid supplementation on NMSC varies based on risk factors, comorbidities, and cancer type. On the other hand skin symptoms are the primary and prominent



# 4<sup>th</sup> INDERCOS

## Dermatology and Cosmetology Congress with International Participants

27 - 30 MARCH, 2019  
HILTON ISTANBUL BOSPHORUS HOTEL  
ISTANBUL, TURKEY



findings in many of the nutritional disorders, for example acrodermatitis enterophatica and pellegra. Another group of diseases associated with diet is gluten hypersensitivity. DH, nonceliac gluten hypersensitivity (NCGH) and wheat allergy (WA) are known as gluten related diseases. Skin symptoms associated to gluten related disorders are becoming more frequent, especially in NCGS and WA, and the complaints are mended with diet.

As conclusion, the relation of dermatologic diseases and diet gains importance gradually, and information upon this relation is extremely important, in order of both the diagnosis, and the treatment.

### References

- 1-Lakdawala N, Babalola III O, Fedeles F, MD. The role of nutrition in dermatologic diseases:Facts and controversies. *Clinics in Dermatology* (2013) 31, 677–700
- 2-Kaimal S, Thappa DM. Diet in dermatology: Revisited. *Indian J Dermatol Venereol Leprol* 2010;76:103-15.
- 3-Bronsnick T, Murzaku EC, Rao BK,Diet in dermatology. Part I. Atopic dermatitis, acne, and nonmelanoma skin cancer. *J Am Acad Dermatol* 2014;71:1039.e1-12.
- 4-Murzaku EC, Bronsnick T , Rao BK.Diet in dermatology. Part II. Melanoma, chronic urticaria, and psoriasis. *J Am Acad Dermatol* 2014;71:1053.e1-16.)
- 5-Faina V, Paolino G, Bavastrelli M et al. Classification of cutaneous manifestation in patients **with** non-celiac gluten sensitivity (NCGS) and wheat allergy (WA). *J Am Acad Dermatol*. **2017 Dec 13. pii: S0190-9622(17)32811-6. doi: 10.1016/j.jaad.2017.12.013.**





# 4<sup>th</sup> INDERCOS

## Dermatology and Cosmetology Congress with International Participants

27 - 30 MARCH, 2019  
HILTON ISTANBUL BOSPHORUS HOTEL  
ISTANBUL, TURKEY



### BIOTIN, FOLIC ACID, AND COENZYME Q FOR SKIN HEALTH

Göknur Kalkan

#### **Biotin**

Biotin (vitamin B7 or H) is an essential cofactor for mammalian carboxylase enzymes that are involved in important metabolic pathways in humans. Humans cannot synthesize biotin and obtain it through diet and synthesis from normal microflora that reside in the large intestine. The most common sources are egg yolk, milk, nuts, and supplements. Biotin deficiency is extremely rare in human beings, and the standard Western diet is considered to have adequate amounts of biotin such as 35-70 g/day.

Biotin deficiency is commonly implicated in hair and nail disorders. Improvement in xerosis and pruritus had been observed in children with atopic dermatitis by the administration of oral biotin. Oral biotin also had a beneficial effect on brittle nails, triangular worndown nails, trachyonychia and habit-tic nail deformity. Biotin has also been used for a number of hair disorders and prominent improvement on hair thickness, combability and hair loss has been detected. Seborrheic dermatitis can be also modulated by oral biotin supplements. The FDA recently introduced a warning regarding the interference of biotin with common laboratory tests especially with the levels of thyroid-stimulating hormone, pro-brain natriuretic peptide, parathyroid hormone and troponin. The FDA emphasizes that physicians should be aware of the possible interference and false results with laboratory tests in patients taking this vitamin.

#### **Folic acid**

Folic acid, or folate is a well-known water soluble vitamin of the B-complex group, necessary for the integrity and function of DNA. Relative deficiency of folic acid may arise in hyperproliferative or chronic inflammatory disorders. Folic acid is the most important dietary determinant of homocysteine; daily supplementation with 0.5 to 5.0 mg typically lowers plasma homocysteine levels by about 25 percent. Elevated homocysteine levels are frequent in patients with chronic immune-mediated disorders including, systemic lupus erythematosus, chronic plaque psoriasis and psoriatic arthritis. An increased incidence of folic acid deficiency has also been reported in psoriasis patients. This observed deficiency may be related to elevated homocysteine levels, decreased intestinal absorption caused by inflammation, and increased use by skin epidermal cells. Folate deficiency is also associated with psoriasis severity. Folic acid supplementation seems to be a rational therapeutic choice in patients affected by chronic inflammatory skin diseases, like psoriasis; especially, those with concomitant hyperhomocysteinemia and low plasma folate, because of the antithrombotic and cardioprotective function and beneficial properties in diminishing methotrexate side effects, such as hepatotoxicity and gastrointestinal intolerance.

#### **Coenzyme Q10**

Coenzyme Q10 (CoQ10) is an endogenous lipid-soluble antioxidant found in all organisms. Coenzyme Q can participate in several aspects of oxidation/ reduction control of signal origin and transmission in cells and it acts as a primary scavenger of free radicals. The human body biosynthesizes CoQ10; in the skin, found in both cells and skin surface lipids, however its skin levels and the levels in other tissues, decline progressively with increasing age. Primary dietary sources include oily fish (such as salmon and tuna), organ meats (such as liver), and whole grains. Most people get enough CoQ10 through a balanced diet, but supplements may help people with particular health conditions. CoQ10 is also commonly added



# 4<sup>th</sup> INDERCOS

## Dermatology and Cosmetology Congress with International Participants

27 - 30 MARCH, 2019  
HILTON ISTANBUL BOSPHORUS HOTEL  
ISTANBUL, TURKEY



to cosmetics, to protect the skin from free radical damage and reduce signs of ageing. CoQ10 is able to protect the skin from reactive oxidative species, prompt the proliferation of skin fibroblasts, inhibit MMP-1 enzymes that degrade extracellular matrix components, accelerate the production of epidermal basement membrane components and reduce DNA damage induced by UVA irradiation. CoQ10 was also clearly effective at reducing photoaging in vivo with a reduction in wrinkle depth and a decrease in the turnover time of the epithelium.

### REFERENCES

- Lipner SR. Rethinking biotin therapy for hair, nail, and skin disorders. *J Am Acad Dermatol.* 2018;78(6):1236-1238.
- Samarasinghe S, Meah F, Singh V, et al. Biotin interference with routine clinical immunoassays: understand the causes and mitigate the risks. *Endocr Pract.* 2017;23:989-998.
- Mock DM. Biotin: from nutrition to therapeutics. *J Nutr.* 2017; 147(8):1487-1492.
- Malerba M, Gisondi P, Radaeli A, Sala R, Calzavara Pinton PG, Girolomoni G. Plasma homocysteine and folate levels in patients with chronic plaque psoriasis. *Br J Dermatol* 2006; 155:1165-9.
- Cakmak SK, Gul U, Kilic, C, Gonul M, Soyulu S, Kilic, A. Homocysteine, vitamin B12 and folic acid levels in psoriasis patients. *J Eur Acad Dermatol Venereol* 2009;23:300-3.
- Žmitek K, Pogačnik T, Mervic L, Žmitek J, Pravst I. The effect of dietary intake of coenzyme Q10 on skin parameters and condition: Results of a randomised, placebo-controlled, double-blind study. *Biofactors.* 2017 Jan 2;43(1):132-140.
- Hojerová J1. Coenzyme Q10—its importance, properties and use in nutrition and cosmetics. *Ceska Slov Farm.* 2000 May;49(3):119-23.



# 4<sup>th</sup> INDERCOS

## Dermatology and Cosmetology Congress with International Participants

27 - 30 MARCH, 2019  
HILTON ISTANBUL BOSPHORUS HOTEL  
ISTANBUL, TURKEY



### **ABSTRACT: VITAMIN A/B/C/D IN DERMATOLOGY**

**Zennure Takci**

Vitamins are required constituents of the human diet as they are essential for development and maintenance of bodily functions. Some vitamins are valuable agents in the prophylaxis and treatment of photoaging, skin cancer, and numerous skin disorders. Vitamin A (Retinol) have many important biologic effects: regulating growth and differentiation in epithelial cells, inhibiting tumor promotion during experimental carcinogenesis, diminishing malignant cell growth, decreasing inflammation, and enhancing the immune system. B-Complex Vitamins like Niacin (B3), Biotin (B7), B5, B12, and B6 have shown the potential to help maintain healthy hair and skin. Vitamin C (ascorbic acid) acts as an antioxidant by scavenging and quenching free radicals. Vitamin D is a fat-soluble compound which is classically known for its role in calcium homeostasis and bone mineralization. Today, recent studies have shown that vitamin D exerts important effects on various types of cells, including immunomodulatory effects and prodifferentiating and antiproliferative effects on normal and cancer cells. In this oral presentation, the author reviewed selected articles from the literature about A/B/C/D vitamins in dermatology to elucidate specific roles and mechanism of action in dermatologic health and disease.



# 4<sup>th</sup> INDERCOs

**Dermatology and Cosmetology Congress  
with International Participants**

27 - 30 MARCH, 2019  
HILTON ISTANBUL BOSPHORUS HOTEL  
ISTANBUL, TURKEY



## **LASER TREATMENT FOR VASCULAR LESIONS**

**Ekrem Civaş**

In recent years medical therapies have also been used in the treatment of vascular lesions beside various laser and surgery. Vascular anomalies which are mostly congenital and occur in early infancy, it affects firstly parents psychologically and then the patients in the childhood period as well. Laser and IPL treatments can be used efficiently in the treatment of this vascular anomalies of childhood. In this study we want to share our results and experience of vascular anomaly treatments with Nd yag laser and IPL.





# 4<sup>th</sup> INDERCOS

## Dermatology and Cosmetology Congress with International Participants

27 - 30 MARCH, 2019  
HILTON ISTANBUL BOSPHORUS HOTEL  
ISTANBUL, TURKEY



### COMPLEMENTARY MEDICINE FOR SKIN CANCERS

Ömer Kutlu

Complementary and alternative medicine (CAM) represents a diverse set of healthcare systems, practices, and treatments that are grouped together because they are not considered part of conventional medicine. From another point of view, “complementary medicine” can be outlined as non-mainstream approaches used in conjunction with conventional medicine, whilst “alternative medicine” refers to the use of non-mainstream approaches in place of a conventional treatment.

Multiple studies reported that from 35% to 70% of patients with skin disease including cancer have used CAM. Cutaneous carcinoma is generally classified as malignant melanoma and non-melanocytic cutaneous carcinoma. The latter mostly include squamous cell carcinoma and basal cell carcinoma as the main subtypes in terms of origination. Development of cutaneous carcinoma is a multistep process including initiation, promotion, and progression. Due to epigenetic alterations and intracellular oxidative stress, some transcriptional factors that involve NF- $\kappa$ B,  $\beta$ -catenin, STAT3, HIF-1 $\alpha$ , and AP-1, as well as their downstream proteins, may be activated. This process may lead to carcinogenesis.

Over two-thirds of human cancers may be prevented by properly modifying the lifestyle, particularly by changing the dietary habit. Resveratrol, epigallocatechin gallate, and curcumin are chemopreventive phytochemicals have been reported to directly regulate a diversity of molecular signal transduction pathways, which contribute cancer initiation, promotion or progression. At the end, they can decrease the death rates of human neoplasms, such as cutaneous carcinoma. Some other well-defined chemopreventive phytochemicals are green tea polyphenols, sulforaphane and lycopene have been verified to affect various biological activities such as inactivation of protein kinases (PI3K/Akt and MAPK), modulation of the activities of transcriptional factors (AP-1, NF- $\kappa$ B, STAT3 and Nrf2), reduce of inflammatory and growth factors (TNF- $\alpha$ , VEGF and IL-1 $\beta$ ) and regulation of epigenetic alterations. Moreover, selenium, vitamin D and vitamin E also have some protective effects on the skin carcinogenesis, although there are contradictory results in previous studies. Nowadays, chemoprevention by using edible diet phytochemicals and supplement of vitamins have become a cheap, attainable and acceptable approach for cutaneous carcinoma.

CAM is still a mostly unknown scientific area in some countries which is overlooked for the prevention and treatment of skin diseases, especially including skin cancer. CAM would be more cost-effective cancer-preventive strategy than use of conventional drugs in the setting of healthcare costs being a key issue.



# 4<sup>th</sup> INDERCOS

## Dermatology and Cosmetology Congress with International Participants

27 - 30 MARCH, 2019  
HILTON ISTANBUL BOSPHORUS HOTEL  
ISTANBUL, TURKEY



### BASIC SCIENCES FOR THE CLINICIAN: EPIGENETICS

H. Bing Thio

Epigenetic mechanisms include DNA methylation, covalent post-translational modifications of histones, and noncoding ribonucleic acid regulation. All these epigenetic mechanisms determine chromatin architecture, accessibility of genetic loci to transcriptional machinery, and gene expression levels. Epigenetic changes are cell-type specific, and epigenetic regulation plays an important role in regulating the normal immune response, such as T cell differentiation. The dysfunction of these mechanisms results in abnormal gene expression and induction of diseases. As epigenetic changes occur early in the disease process, aberrant epigenetic regulators are ideal targets for disease diagnosis and treatment. Epigenetic alterations are increasingly recognized as playing an important role in the pathogenesis of a growing number of immune-mediated diseases. So far, most epigenome-wide studies in general medicine focused primarily on DNA methylation changes and have resulted in the identification of novel target genes and pathogenic mechanisms in immune-mediated diseases. The epigenome is dynamic, allowing for the development of novel biomarkers for disease activity, specific disease manifestations, and response to treatment. Some epigenetic changes reflect the effect of environmental triggers that cause disease in a genetically susceptible host. Ageing including immunosenescence is also accompanied by epigenetic modifications. The plasticity of DNA methylation and posttranslational histone modifications may have evolved to allow organisms to adapt to changing environmental conditions. An integrated “omics” approach would help to better understand physiological conditions and disease pathogenesis.

#### References

- Gaballa JM, Braga Neto MB, Ramos GP, Bamidele AO, Gonzalez MM, Sagstetter MR, Sarmiento OF, Faubion WA Jr. The Role of Histone Methyltransferases and Long Non-coding RNAs in the Regulation of T Cell Fate Decisions. *Front Immunol.* 2018 Dec 13;9:2955. eCollection 2018. Review.
- Richardson B. Epigenetically Altered T Cells Contribute to Lupus Flares. *Cells.* 2019 Feb 5;8(2). pii: E127. doi: 10.3390/cells8020127.



# 4<sup>th</sup> INDERCOS

## Dermatology and Cosmetology Congress with International Participants

27 - 30 MARCH, 2019  
HILTON ISTANBUL BOSPHORUS HOTEL  
ISTANBUL, TURKEY



### MICROBIOTA, IMMUNE SYSTEM AND SKIN

H. Bing Thio

The micro-organisms that colonise the human body (collectively known as microbiota) are rapidly emerging as important players in the regulation of immune homeostasis, such that alterations in the make-up of microbial communities (also known as states of dysbiosis) have been implicated in the pathogenesis of numerous immune-mediated disorders. Microbiota research is now at the top of its hype. Many associations with health and disease outcomes are investigated and several types of interventions are being developed. The human intestine on its own harbours a complex microbial community that is estimated to contain approximately 100 trillion cells, belonging to over 1000 species. Similar to the gut, the skin represents another important interface between the host and the environment. Microbial profiling has revealed the presence of highly diverse commensal communities along distinct topographical skin sites. Both the skin and the gut microbiome influence immune tissue development and function, as well as in promoting systemic inflammation in the context of autoimmunity. Main phyla inhabiting human skin are Actinobacteria, Firmicutes, Bacteroidetes, and Proteobacteria. A feature of human cutaneous microbiota is the existence of different microhabitats, which are characterized by the predominance of a specific taxa: sebaceous sites (occiput, glabella, alar crease, and manubrium) with *Propionibacterium* spp; moist sites (nare, axilla, and inguinal crease) with *Staphylococcus* and *Corynebacterium* spp; and dry sites (palms and buttock) with gram-negative microorganisms. *Fusobacteria* was also detected as a main phylum, when only considering the paws and the forehead and also in a recent study considering the groins. In humans, the variation is higher among different microhabitat skin sites of the same individual than among skin sites from the same microhabitat in different individuals. The skin harbors a wide range of different cell populations including keratinocytes, macrophages, dendritic cells, innate lymphocytes, and different T-cell populations that belong to or perform functions of the innate and adaptive immunity. All these cells can be affected by mediators produced by the skin microbiota. Strategies to manipulate the skin and gut microbiota for therapeutic reasons can be divided into three categories: antimicrobial (antibiotic) therapy, application of pre- and/or probiotics (and postbiotics), or transplantation of entire microbial consortia. While antibiotic treatment aims at an elimination of specific (pathogenic) microorganisms, the goal of the application of probiotics or microbiota transplantation is an increase of selected, potentially beneficial microorganisms.

#### References

- Almeida A, Mitchell AL, Boland M, Forster SC, Gloor GB, Tarkowska A, Lawley TD, Finn RD. A new genomic blueprint of the human gut microbiota. *Nature*. 2019 Feb 11. [Epub ahead of print]
- Dehner C, Fine R, Kriegel MA. The microbiome in systemic autoimmune disease: mechanistic insights from recent studies. *Curr Opin Rheumatol*. 2019 Mar;31(2):201-207.
- Johnson TR, Gómez BI, McIntyre MK, Dubick MA, Christy RJ, Nicholson SE, Burmeister DM. The Cutaneous Microbiome and Wounds: New Molecular Targets to Promote Wound Healing. *Int J Mol Sci*. 2018 Sep 11;19(9). pii: E2699.
- Benhadou F, Mintoff D, Schnebert B, Thio HB. Psoriasis and Microbiota: A Systematic Review. *Diseases*. 2018 Jun 2;6(2). pii: E47. doi: 10.3390/diseases6020047. Review.



# 4<sup>th</sup> INDERCOS

## Dermatology and Cosmetology Congress with International Participants

27 - 30 MARCH, 2019  
HILTON ISTANBUL BOSPHORUS HOTEL  
ISTANBUL, TURKEY



### IMMUNOTHERAPY CANCER AND THE SKIN

H. Bing Thio

There are several forms of immunotherapy in cancers. PD (programmed cell death)-1 or PD-L (ligand)1 inhibitors (nivolumab, pembrolizumab) target checkpoint molecules called PD-1 or PD-L1 that are present on T cells. These inhibitors provide an adequate antitumor response and are used to treat melanoma, non-small-cell lung cancer, kidney cancer, bladder cancer, head and neck cancers, stomach cancer, colorectal cancer, and Hodgkin's lymphoma. CTLA (cytotoxic T-cell associated antigen)-4 inhibitors (ipilimumab) turn off another checkpoint molecule called CTLA-4, which is also found on T cells. These inhibitors are used for melanoma, colorectal, and certain other cancer types. These therapies are often accompanied by various skin adverse effects varying from mild lichenoid reaction to severe toxic epidermal necrolysis. Corticosteroids are the mainstay of the treatment of these skin reactions. Preexisting immune-mediated skin diseases such as psoriasis usually exacerbate during these anti-cancer immunotherapies. There are other immunotherapies inducing similar skin toxicities. CAR T-cell (chimeric antigen receptor T-cell therapy) is similar as adoptive cell transfer therapy (ACT) and is used to treat two types of blood cell cancers: tisagenlecleucel for acute lymphoblastic leukemia (ALL) and xicabtagene ciloleucel (Yescarta) for some types of large B-cell lymphoma, such as non-Hodgkin's lymphoma. Cancer vaccine therapy with ipuleucel-T is approved to treat advanced prostate cancer. T-cell receptor therapy (TCR) and tumor-infiltrating lymphocytes (TIL) therapy are other forms of ACT. The dermatologist is playing an important role in making the proper diagnosis and in setting up the adequate management of these skin reactions. This is essential for optimal patient care and to avoid unnecessary cessation of these effective anti-cancer therapies.

#### References

- Koury J, Lucero M, Cato C, Chang L, Geiger J, Henry D, Hernandez J, Hung F, Kaur P, Teskey G, Tran A. Immunotherapies: Exploiting the Immune System for Cancer Treatment. *J Immunol Res.* 2018 Mar 14;2018:9585614. eCollection 2018.
- J B A G Haanen F Carbone C Robert K M Kerr S Peters J Larkin K Jordan on behalf of the ESMO Guidelines Committee. Management of toxicities from immunotherapy: ESMO Clinical Practice Guidelines for diagnosis, treatment and follow-up. *Annals of Oncology*, Volume 28, Issue suppl\_4, 1 July 2017, Pages iv119-iv142.





# 4<sup>th</sup> Indercos

## Dermatology and Cosmetology Congress with International Participants

27 - 30 MARCH, 2019  
HILTON ISTANBUL BOSPHORUS HOTEL  
ISTANBUL, TURKEY



### STEM CELL MODULATION IN DERMATOLOGY

**Özgür Timurkaynak**

A current summary of, evidence-based stem cell studies in the field of dermatology have been outlined. Stem cells (SCs), are undifferentiated self-replicating cells, having the ability to generate, sustain and replace terminally differentiated cells. Besides their expected regenerative properties; their consistent anti-inflammatory and immune modulatory nature, make them a convenient therapeutic alternative for various refractory inflammatory and autoimmune skin disorders. They can be isolated from embryonic as well as almost all adult tissues including the skin, but are also generated through genetic reprogramming of differentiated cells. These reprogrammed cells have also been used for certain genodermatoses. Further research is needed to improve the outcome and safety of SC based therapies.



# 4<sup>th</sup> INDERCOS

## Dermatology and Cosmetology Congress with International Participants

27 - 30 MARCH, 2019  
HILTON ISTANBUL BOSPHORUS HOTEL  
ISTANBUL, TURKEY



### CIRCADIAN RHYTHM AND SKIN DISEASES

**Berna Aksoy**

Chronobiology is the science of investigating and objectively quantifying phenomena and mechanisms of the biologic time structure, including the rhythmic manifestations of life. Biologic rhythm is described as a regularly recurring (periodic) component in a series of measurements of a biologic variable obtained as a function of time. Circadian rhythm is the regularly recurring biological rhythm at an interval of 24 hours (>20 to <28 hours). Circadian rhythm applies to bodily hormone (melatonin, ACTH, cortisol) production, serum cytokine levels (TNF- $\alpha$ , IL-10, GM-CSF), temperature regulation, and blood glucose levels. Jet-lag is a typical circadian rhythm disturbance. Melatonin is considered as a major chronobiotic hormone produced mainly by the pineal gland. Melatonin has been shown to act as an endogenous synchronizer either in stabilizing bodily rhythms or in reinforcing them. Melatonin is principally secreted at night and is centrally involved in sleep regulation, as well as in a number of other cyclical bodily activities. Circadian rhythm dysfunction has been shown in circadian rhythm sleep disorders, Alzheimer's and Parkinson's diseases, hypertension, glaucoma, depressive disorder, breast cancer, prostate cancer, ovarian and endometrial cancer, colon cancer, hepatoma, psoriasis and melanoma. Itch and eczema worsens at night. Various skin functions have a circadian rhythm. An interpretation of the cutaneous biorhythm in humans suggests that during the day the skin boosts its protective functions to ward off environmental threats. In the evening and at night, the major emphasis is on its renewal and diverse metabolic processes. Skin seems to be more reactive towards the late afternoon and evening than in the morning and early afternoon. Circadian rhythms are important in immune functions, wound healing and aging of the skin. Topical therapeutics may also be administered according to circadian rhythm as once-a-day dosing regimen of topical corticosteroids in the late afternoon may be sufficient for dermatologic therapy. Even skin care regimens could be adjusted to circadian rhythms; skin cleansing when transepidermal water loss (TEWL) is lowest (in the mornings), and application of actives when TEWL is the highest (in the evenings).



# 4<sup>th</sup> INDERCOS

## Dermatology and Cosmetology Congress with International Participants

27 - 30 MARCH, 2019  
HILTON ISTANBUL BOSPHORUS HOTEL  
ISTANBUL, TURKEY



### SEXUAL FUNCTION DISORDERS IN DERMATOLOGY

**Aylin Türel Ermertcan**

Sexual health is perceived as an integral part of general health as it can markedly affect quality of life. Sex is an ubiquitous subject in the society, vying for more of our attention in the media, on the Internet, and from other entertainment outlets. Beyond the popular fascination, experimental and clinical research on sex and sexuality also has been increasing. Although men with erectile dysfunction proved to be the initial beneficiaries of the surge in scientific investigation of human sexuality, women with sexual disorders are steadily gaining ground. Several scales were designed to evaluate sexual satisfaction in men. The Sexual Encounter Profile (SEP), the International Index of Erectile Function (IIEF) and the Sexual Health Inventory for Men (SHIM) (IIEF-5) are the most commonly used instruments to assess erectile function in men. Whereas the IIEF is mainly used in research setting, the IIEF-5 (SHIM) is widely used to assess erectile function in clinical practice. The female sexual function index (FSFI) and the Sexual Interest and Desire Inventory-Female (SIDI-F) were designed to evaluate sexual function in women. The scales used for male and female sexual functioning are listed in table 1 and 2. Arizona Sexual Experience Scale (ASEX), the Medex Sexual Dysfunction Subscale, the Relation and Sexuality Scale (RSS) and Sexual Self-Consciousness Scale (SSCS) has been developed to evaluate sexual functioning in both men and women. The scales used for both male and female sexual functioning are listed in table 3.

Chronic systemic diseases may cause psychosocial problems and effect quality of lives and sexual functioning of the patients. Previous studies have revealed a higher prevalence of sexual dysfunction in chronic pain patients supporting this hypothesis. In the literature there are reports about sexual dysfunction in patients with chronic obstructive pulmonary disease, fibromyalgia, chronic liver disease, myocardial infarction, diabetes mellitus, allergic rhinoconjunctivitis, Parkinson's disease, epilepsy, chronic renal failure and multiple sclerosis.

Apart from the clinical severity of the disease skin diseases may cause a variety of psychological problems, including poor self esteem, anxiety, depression, difficulties at work, social phobia, sexual dysfunction and suicidal ideation. In dermatology arena this subject is quite new. There are a few comprehensive studies about sexual dysfunction in dermatological diseases in the literature. It was reported that psoriasis, atopic dermatitis, vitiligo and chronic urticaria may cause sexual function disfunction. Niemeier et al compared the sexual behaviors of 53 patients with psoriasis, 24 patients with atopic eczema and 52 controls with healthy skin. For the test, they used questionnaires developed by Arentewicz as well as their own questionnaire on sexuality. Patients with skin diseases had a significantly impaired sex life, compared to those with healthy skin. Patients with psoriasis felt more impaired than those with atopic eczema. Sampogna et al investigated sexual life in psoriatic patients by using answers to specific items from two dermatology-specific questionnaires (Skindex-29 and Dermatology Life Quality Index-DLQI) and from two psoriasis-specific questionnaires (Psoriasis Disability Index-PDI and Impact of Psoriasis on Quality of Life Questionnaire-IPSO). Of 936 patients from 35,5% (PDI) to 71,3% (IPSO) reported to have experienced sexual problems because of psoriasis. A more severe disease and the presence of psychological problems were also associated with sexual impairment. They observed that sexual life was especially impaired in patients with psoriatic arthritis.



# 4<sup>th</sup> INDERCOS

## Dermatology and Cosmetology Congress with International Participants

27 - 30 MARCH, 2019  
HILTON ISTANBUL BOSPHORUS HOTEL  
ISTANBUL, TURKEY



We had published three studies about patients with psoriasis, chronic hand eczema and neurodermatitis that effects sexual functioning.

Since sexual functioning is an important part of life and quality of life, sexual dysfunction should be investigated and treated in patients with skin diseases. I suggest dermatologists to use especially FSFI (for women) and IIEF (for men) tests for detecting sexual function disorders in skin diseases.

### References

- Nicolosi A, Laumann EO, Glasser DB, et al. Sexual behavior and sexual dysfunctions after age 40: The global study of sexual attitudes and behaviors. *Urology* 2004; 64: 991-997.
- Bachmann G. Female sexuality and sexual dysfunction: Are we stuck on the learning curve? *J Sex Med* 2006; 3: 639-645.
- Rosen RC, Riley A, Wagner G, et al. The International Index of Erectile Function (IIEF): a multidimensional scale for assessment of erectile dysfunction. *Urology* 1997; 49: 822-830.
- Dalpiaz O, Kerschbaumer A, Mitterberger M, et al. Female sexual dysfunction: a new urogynaecological research field. *BJU Int* 2008; 101: 717-721.
- Rosen R, Brown C, Heiman J, et al. The Female Sexual Function Index (FSFI): A multidimensional self-report instrument for the assessment of female sexual function. *J Sex Marital Ther* 2000; 26: 191-208.
- Koseoglu N, Koseoglu H, Ceylan E, et al. Erectile dysfunction prevalence and sexual function status in patients with chronic obstructive pulmonary disease. *J Urol* 2005; 174: 249-252.
- Turel Ermertcan A, Temeltas G, Devenci A, et al. Sexual dysfunction in patients with psoriasis. *J Dermatol* 2006; 33: 772-778.
- Ergun M, Turel Ermertcan A, Ozturkcan S, et al. Sexual dysfunction in patients with chronic hand eczema in the Turkish population. *J Sex Med* 2007; 4: 1684-1690.
- Ermertcan AT, Gencoglan G, Temeltas G, Horasan GD, Devenci A, Ozturk F. Sexual dysfunction in female patients with neurodermatitis. *J Androl* 2011; 32: 165-169.
- Ermertcan AT. Sexual dysfunction in dermatological diseases. *J Eur Acad Dermatol Venereol* 2009; 23: 999-1007.





# 4<sup>th</sup> Indercos

## Dermatology and Cosmetology Congress with International Participants

27 - 30 MARCH, 2019  
HILTON ISTANBUL BOSPHORUS HOTEL  
ISTANBUL, TURKEY



### SKIN MANIFESTATIONS in FORENSIC MEDICINE and SEXUAL ABUSE

Hakan Kar

**Introduction & Objectives:** Accurate identification and documentation of dermatological lesion are significant in terms of forensic science. Skin and the lesions on the skin can provide us a lot of information about the individual and the subject. In this presentation, we aimed to present the general view of dermatological findings and the importance of lesions from the forensic perspective.

**Materials & Methods:** Cases of dermatological lesion which are significant in terms of forensic science are reviewed in this study.

**Results:** In terms of forensic medicine, skin lesions should be well defined and distinguished whether they are pathological or traumatic lesions. The location, three dimensional size (width, height, depth), shape, color, trace, age of the lesion give us information about its origin.

Ecchymosis and abrasions should be examined in detail in terms of neglect and abuse in childhood period. Skin injuries that can range from superficial injuries such as first-degree burns, abrasions and bite marks to severe injuries such as incisions and 2 or 3 degrees burns (i.e. cigarette burns) are the most common and easily recognized lesions in an abused child (See Fig.1,2). The ecchymosis are very important in terms of providing the best evidence of abuse against the child and their localization, shape and color, and information about the cases.

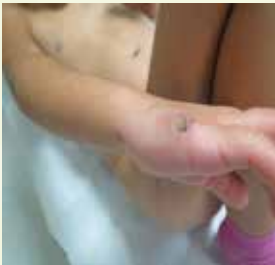

Fig.1: Cigarette Burn

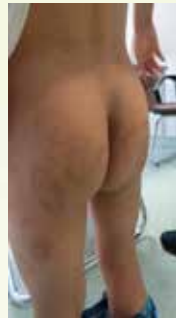

Fig.2: Bite marks

The other important field of forensic medicine is sexual assault cases. We should pay attention to dermatological lesions caused by sexually transmitted diseases and required samples should be taken from the cases of sexual abuse. Especially common sexually transmitted infections are Human Papilloma Virus (See Fig.3) and syphilis in sexual assaults. Erythema, abrasions and ecchymotic lesions we have encountered during external genital examination support sexual assaults. Constipation, parasitic infections and scratching are important causes to be considered in the differential diagnosis of sexual assault (See Fig.4). There are also we can observe thumbprints and linear abrasions caused by fingernails in forced sexual assault cases (See Fig.5).



# 4<sup>th</sup> INDERCOS

Dermatology and Cosmetology Congress  
with International Participants  
27 - 30 MARCH, 2019  
HILTON ISTANBUL BOSPHORUS HOTEL  
ISTANBUL, TURKEY



Fig.3: Anal Condyloma

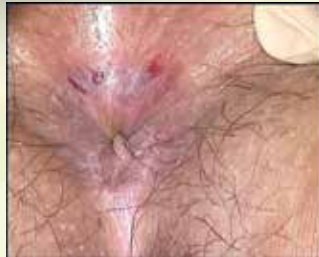

Fig.4: Anal laceration

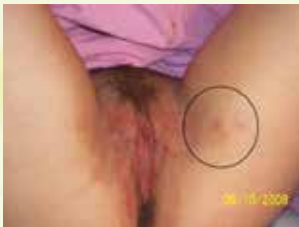

Fig.5: Linear abrasion caused by fingernails and thumbprint

Medical malpractice is one of the comprehensive subjects of the medical profession with its legal and ethical dimensions and requires a multidisciplinary evaluation of the situations that arise. In recent years, we are frequently encountered with medical malpractice especially in dermatocosmetology field. Common malpractice claims are arisen from laser hair removal process. Hyperpigmented, hypopigmented scars and burns are common complications of the process (See Fig.6). These cases differs from dermatomedical cases by their different legal regulations. Malpractice claims of dermatocosmetic cases are evaluated as esthetical practices rather than medically and to be subjected to special legal regulations.



# 4<sup>th</sup> INDERCOS

## Dermatology and Cosmetology Congress with International Participants

27 - 30 MARCH, 2019  
HILTON ISTANBUL BOSPHORUS HOTEL  
ISTANBUL, TURKEY

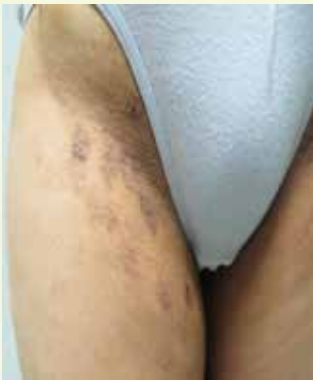
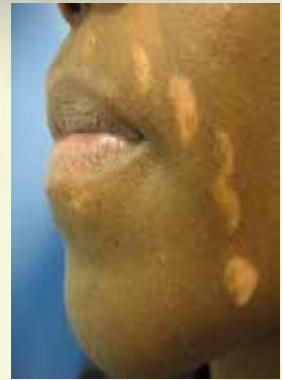
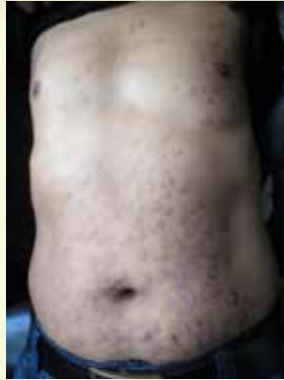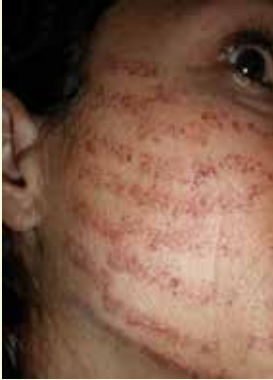Fig.6: Hyperpigmented, hypopigmented scars and burns

**Conclusion:** Evaluation of skin lesions is critical in defining injury type. Dermatological lesions may present information about the origin of the event in the forensic cases such as accident, murder, abuse, neglect, sexual assault, suicide, torture, poisoning and may play a decisive role in the judgment processes. The lesions detected may indicate child sexual abuse, for example sexually transmitted diseases may be a symptom indicating sexual abuse. In addition, Forensic Medicine and Dermatology should work together with medicolegal approach in malpractice claims.

Keywords: Dermatology, forensic medicine, sexual assault, sexually transmitted diseases, ecchymosis, abrasions.



# 4<sup>th</sup> INDERCOs

## Dermatology and Cosmetology Congress with International Participants

27 - 30 MARCH, 2019  
HILTON ISTANBUL BOSPHORUS HOTEL  
ISTANBUL, TURKEY



### STDs RELATED TO OROGENITAL CONTACT

**Soner Uzun**

Orogenital contact is commonly practiced by sexually active male-female and homosexual couples of various ages. The various type of orogenital contact practices are fellatio, cunnilingus and anilingus. Sexual activities as orogenital contact may be related to several STDs, including HIV. These types of sexual activities may play role as an efficient mode of transmission for syphilis, gonorrhea, herpes and HIV. Chlamydia and HPV can also be transmitted through orogenital contact. Due to different subtypes of HPV, oral papilloma/wart, focal epithelial hyperplasia, dysplastic wart, verrucous carcinoma and condyloma acuminatum are the most frequent clinical pictures can be developed in the oral cavity mucosa. HPVs also have received considerable attention as a risk factor of oral cancers in recent years. It is important to use protection and safer sex precautions in prevention from STDs related to orogenital sexual contact. Vaccination of teenage males and females will potentially decrease spread of oral HPV infection.





# 4<sup>th</sup> INDERCOS

## Dermatology and Cosmetology Congress with International Participants

27 - 30 MARCH, 2019  
HILTON ISTANBUL BOSPHORUS HOTEL  
ISTANBUL, TURKEY



### **SURGICAL AND NON-SURGICAL MANagements OF THE WOMEN'S SEXUAL DYSFUNCTIONS**

**Ayten Olgun**

Women's sexual dysfunctions have been classified as sexual interest-arousal disorders, genitopelvic pain-penetration disorders, and orgasmic disorders in DSM-5. Vaginismus and Dyspareunia are both included in genitopelvic pain and penetration disorders that have psychologic and organic origins dependent upon congenital abnormalities or acquired problems of genitalia. If organic problems exist, they should be solved previously and then psychogenic components should be managed. On the other hand, some surgical operations and non-invasive methods may ensure satisfactory results in treatments of sexual interest and arousal disorders. Genital radiofrequency, CO2 laser managements, PRP and Stem cell treatments seem to be very promising.



# 4<sup>th</sup> INDERCOs

**Dermatology and Cosmetology Congress  
with International Participants**  
27 - 30 MARCH, 2019  
HILTON ISTANBUL BOSPHORUS HOTEL  
ISTANBUL, TURKEY



## **SYPHILIS IN RELATION TO HIV-WHAT EVERY DERMATO-VENEREOLOGIST SHOULD KNOW?**

**Michael Waugh**

We have known for over 30 years that mucosal genital ulceration is a major factor in the transmission of human immunodeficiency virus (HIV). From 1990 onwards after the break up of the Soviet Union syphilis reached epidemic proportions in some parts of Eastern Europe.

World Health Organisation has reported HIV prevalence is much the same in Turkey as many other countries in the Middle East. But there is a feeling that it may well be under-reported. There are now several studies from Turkey especially from Istanbul of increasing HIV positivity in men who who have sex with men (MSM) and the difficulties of being tested and receiving advice and treatment. Some of the same problems are found in many other countries where there is a general negative public feeling to revealing homosexual behaviour (MSM). But any social historian of sexology will be able to give references for it in literature over the last 1000 years.

In Turkey, reported by clinicians and from syphilis testing on blood donor samples there has been over the last 20 years a rise in syphilis positivity.

For HIV, advice, treatment and follow up is readily available throughout Western Europe and even in other countries such as Thailand. It is cost effective and not only saves lives, but prevents infection to others and thus HIV prevalence drops.

In Western Europe if any sexually transmitted infection (STI) is found, other STIs including HIV are tested for and also Hepatitis B and C. This is not just a nice idea but should always be done. Yes, You will find more unknown cases of HIV in all groups when this is adhered to but with adequate current medical treatment not only is health enhanced, but infection to others prevented and generally a lowering of prevalence of syphilis and HIV in future years.



# 4<sup>th</sup> INDERCOS

## Dermatology and Cosmetology Congress with International Participants

27 - 30 MARCH, 2019  
HILTON ISTANBUL BOSPHORUS HOTEL  
ISTANBUL, TURKEY



### VIBRATION AND NITROUS OXIDE ANESTHESIA IN COSMETIC PROCEDURES, SYMPATHECTOMY IN DERMATOLOGY

Mustafa Tunca

**INTRODUCTION:** In dermatology and cosmetology, many procedures such as local anesthetic injections, cosmetic injections and other cosmetic interventions may cause significant pain and distress to patients (1, 2). Injectable cosmetics form a major proportion of the cosmetic procedures, and minimizing the pain caused by injections greatly enhances compliance and patient experience. Therefore, it is very important to alleviate pain and anxiety related to cosmetic procedures.

Methods used for anesthesia and analgesia in cosmetic procedures are varied. Psychological interventions, such as music, talking during the intervention for distraction and hypnosis, rubbing or pinching the injection site, cooling, warming, using topical anesthesia and injecting the substance slowly are some of the measures that can be taken to reduce pain and patient distress (1). Vibration and nitrous oxide anesthesia will be discussed here.

Also we will briefly discuss the role of sympathectomy in dermatology .

#### ***Vibration Analgesia in Cosmetic Procedures***

Vibration anesthesia is one of the methods for reducing pain during injections and is thought to be effective through the gate control theory. In 2004, commercially available inexpensive massagers were used to alleviate pain associated with dermatologic procedures (2). The technique was later started to be used by dentists for reducing pain during infiltration anesthesia and nerve blockade (3).

#### Mechanism of Action

The gate control theory involves the inhibition of pain-conveying A-delta C-fibers by input from the A alpha and beta fibers, which are myelinated and convey neural stimulation faster than C-fibers (4).

#### Efficacy

There are multiple reports showing efficacy of vibration analgesia during various dermatologic and cosmetic procedures in the literature. It has been used for palmar/plantar botulinum toxin injections, mild cauterization of facial warts, facial toxin injections, and dermal filler injections.

#### Conclusions

Vibration analgesia is a safe, cheap and effective method for pain alleviation during dermatologic and cosmetic procedures. Especially when used together with other methods such as "talkesthesia", premedication with analgesics, cooling/warming vibration stimulus can be very helpful in reducing pain and increasing patient comfort.

#### ***Nitrous Oxide Anesthesia in Cosmetic Procedures***

Nitrous oxide (N<sub>2</sub>O) has been widely used as an analgesic/anesthetic agent for a longtime, previously as a component of general anesthesia (5). It is most commonly used during dental and pediatric procedures (6). It has no significant effects on major body systems except central nervous system.

#### Mechanism of Action

It stimulates the beta endorphin system and antagonizes the NMDA receptor, thus having analgesic and anxiolytic effects (7)μ . .

#### Advantages

Rapid onset of action and fast recovery, easily controllable duration of action, low side effect profile, patient satisfaction and convenience are among the advantages of nitrous oxide anesthesia (6).



# 4<sup>th</sup> INDERCOS

## Dermatology and Cosmetology Congress with International Participants

27 - 30 MARCH, 2019  
HILTON ISTANBUL BOSPHORUS HOTEL  
ISTANBUL, TURKEY



### **Efficacy**

It has been showed as an effective analgesia method for palmar/plantar toxin injections, fractionated radiofrequency/CO<sub>2</sub> laser for facial rejuvenation, intense pulsed light treatment for rosacea, tattoo laser removal, laser treatment of acne scars, hair transplantation, dermabrasion, excision and repair.

### **Safety**

Common adverse events reported during N<sub>2</sub>O analgesia are laughter, euphoria, nausea and dizziness (6). Besides laughter, although less often, N<sub>2</sub>O may also cause other mood lability symptoms (8).

### **Conclusions**

N<sub>2</sub>O may be a good adjunctive agent for pain control in dermatologic and cosmetic interventions. The studies at present provide evidence for efficacy and safety of N<sub>2</sub>O anesthesia during dermatologic procedures. However, larger well designed randomized controlled studies are warranted to support these findings.

### **Sympathectomy in Dermatology**

Video-assisted thoracoscopic sympathectomy has been shown to be safe and minimally invasive for the treatment of palmar and axillary hyperhidrosis (9). Although it is highly effective in eliminating palmar and axillary perspiration, compensatory hyperhidrosis occurs in at least half of the patients. Surgical treatment of hyperhidrosis should be restricted to patients who are refractory to non-invasive treatments. Sympathectomy has also been used to relieve pain and help healing digital ulcers in systemic sclerosis patients, and for the treatment of idiopathic livedo reticularis, recalcitrant erythromelalgia and aquagenic syringal acrokeratoderma.

### **REFERENCES**

1. Babamiri K, Nassab R. The evidence for reducing the pain of administration of local anesthesia and cosmetic injectables. *J Cosmet Dermatol.* 2010;9:242-245.
2. Smith KC, Comite SL, Balasubramanian S, et al. Vibration anesthesia: a noninvasive method of reducing discomfort prior to dermatologic procedures. *Dermatol Online J.* 2004;10:1.
3. Nanitsos E, Vartuli R, Forte A, et al. The effect of vibration on pain during local anaesthesia injections. *Aust Dent J.* 2009;54:94-100.
4. Quaba O, Huntley JS, Bahia H, et al. A users guide for reducing the pain of local anaesthetic administration. *Emerg Med J.* 2005;22:188-189.
5. Leslie K, Myles PS, Kasza J, et al. Nitrous Oxide and Serious Long-term Morbidity and Mortality in the Evaluation of Nitrous Oxide in the Gas Mixture for Anaesthesia (ENIGMA)-II Trial. *Anesthesiology.* 2015;123:1267-1280.
6. Brotzman EA, Sandoval LF, Crane J. Use of Nitrous Oxide in Dermatology: A Systematic Review. *Dermatol Surg.* 2018;44:661-669.
7. de Vasconcellos K, Sneyd JR. Nitrous oxide: are we still in equipoise? A qualitative review of current controversies. *Br J Anaesth.* 2013;111:877-885.
8. Sadick NS, Militana CJ. Use of nitrous oxide in hair transplantation surgery. *J Dermatol Surg Oncol.* 1994;20:186-190.
9. Ambrogi V, Campione E, Mineo D, et al. Bilateral thoracoscopic T2 to T3 sympathectomy versus botulinum injection in palmar hyperhidrosis. *Ann Thorac Surg.* 2009;88:238-245.





# 4<sup>th</sup> INDERCOS

## Dermatology and Cosmetology Congress with International Participants

27 - 30 MARCH, 2019  
HILTON ISTANBUL BOSPHORUS HOTEL  
ISTANBUL, TURKEY



### TOPICAL ANTICHOLINERGICS AND ANTIANDROGENS IN DERMATOLOGY

Betül Şerefican

#### **Topical anticholinergics**

Topical anticholinergic preparations have been shown to be an efficacious treatment in certain patients with hyperhidrosis. The most common of these is topical glycopyrrolate (1). Glycopyrrolate is a quaternary ammonium anticholinergic which cannot penetrate the blood–brain barrier and therefore has only little effect on the central nervous system. It exerts its anhidrotic effect by competing with acetylcholine at the muscarinic receptors of the eccrine glands.

To avoid the systemic anticholinergic adverse effects, topical formulations of glycopyrrolate have the potential to treat several different types of hyperhidrosis and several different body areas such as axillary, craniofacial hyperhidrosis. Mostly, topical glycopyrrolate is well tolerated, with few reported adverse effects including headache, dry mouth, mydriasis, sore throat, skin irritation, and difficulty with accommodation (2).

Drug efficacy differs between studies, a study evaluated the efficacy of 1% glycopyrrolate cream for axillary hyperhidrosis and was unable to indicate a consistent benefit, in contrast another study demonstrated improvement in axillary hyperhidrosis by using 2% glycopyrrolate spray, but showed less improvement using 1% spray. Topical glycopyrrolate is indicated mainly for hyperhidrosis of the head and neck and gustatory sweating (1).

Topical glycopyrrolate may be used twice daily, but it is more usually applied at night. Nightly applications of glycopyrrolate help to better tolerate possible side effects. A local inconvenience may be pruritus. Care should be taken to avoid the nose, mouth, and particularly the eyes.

Oxybutynin is another anticholinergic. A study evaluated a topical formulation of oxybutynin for the treatment of primary localized axillary, palmar or plantar hyperhidrosis. They found that a twice daily application of 10% topical oxybutynin gel resulted in a significant reduction in 'hyperhidrosis disease severity scale' scores and a significant improvement in 'dermatology life quality index' scores. Topical application of oxybutynin 10% gel appears to be an effective, safe and well-tolerated treatment for focal primary hyperhidrosis (3). Also, another study indicated that, oxybutynin topical gel applied for 1 week had no clinically meaningful effect on recent memory or other cognitive functions in healthy, older adults.

Glycopyrronium tosylate is a topical anticholinergic approved by the US Food and Drug Administration (2018) for primary axillary hyperhidrosis in patients 9 years and older. It resulted in significant reductions in severity of sweating and sweat production with favorable tolerability in 2 phase 3 randomized, vehicle-controlled trials in patients with primary axillary hyperhidrosis (4).

Umeclidinium (UMEC) is a long-acting muscarinic antagonist. Nasir et al. researched the clinical effect of topically applied 1.85% UMEC following once daily administration to axillae for 14 days in subjects with primary axillary hyperhidrosis. Systemic exposure of UMEC after topical application was measurable in the majority of participants and suggested a slow absorption rate. Acceptable safety and preliminary clinical activity observed in this double-blind, randomized, vehicle-controlled study suggested the potential clinical benefit of topical UMEC in subjects with axillary hyperhidrosis (5).

Multiple hidrocystomas of the face are rare benign cystic lesions. They typically occur in middle-aged or older women and are associated with excessive sweating. The successful use of topical atropine and topical scopolamine preparations has been reported in a limited number of cases. In a study with five patients, 1% topical atropine therapy was effective and safe in patients with multiple hidrocystomas. The few adverse effects



# 4<sup>th</sup> INDERCOS

## Dermatology and Cosmetology Congress with International Participants

27 - 30 MARCH, 2019  
HILTON ISTANBUL BOSPHORUS HOTEL  
ISTANBUL, TURKEY



were either asymptomatic or well tolerated. Miliaria rubra can be almost completely suppressed by topical applications of the anticholinergic agent, hexopyrronium bromide.

Syringomas are common benign tumors of eccrine origin. In a case report, treatment with 1% topical atropine resulted remission of pruritus and reduction in the size of multiple pruritic eruptive syringomas.

### **Topical antiandrogens**

Antiandrogens are substances capable of blocking androgen action. Antiandrogens such as spironolactone, cyproterone acetate, flutamide bind to the androgen receptor and competitively inhibit dihydrotestosterone binding. Systemic antiandrogens are frequently used in female pattern hair loss. In men, they cause loss of libido, impotence and gynecomastia. New safe and effective approaches are needed because of the displeasing side effects. Topical administration of antiandrogens offers the hope of delivering a high local concentration of the medication to the scalp for androgenetic alopecia, while avoiding systemic side effect. Fluridil, a topical antiandrogen similar in structure to flutamide has been developed for use in androgenetic alopecia. It is highly hydrophobic, with high local efficacy and tolerance. It suppresses androgen receptors in hair follicles and degrades into inactive metabolites without systemic anti-androgenic effects. A study showed that males with androgenetic alopecia using topical fluridil had an increase in the anagen to telogen ratio and the maximum attainable effect was achieved within the first 90 days of daily use. Sexual function, hematology and blood chemistry values were normal over the duration of the research (6). In one open study performed on patients with female androgenetic alopecia with topically applied 2% fluridil demonstrated that the anagen/telogen % ratio after 6 and 9 months showed no significant changes, but after 9 months there was no androgenetic alopecia progression. Fluridil is being used throughout Europe.

Alfatradiol (17 $\alpha$ -estradiol) is a topical antiandrogen that acts by blocking 5 $\alpha$ -reductase. The proposed application is 0.025% alfatradiol twice daily. Studies on the alfatradiol showed contradictory findings. In females, a study showed that participants treated with 0.025% alfatradiol lotion had decreased total hair counts at 24 weeks while 2% minoxidil solution supported increased hair counts. In contrast, another study showed that alfatradiol significantly increased the ratio of frontal anagen/telogen hair after 30 weeks of treatment in both genders.

Topical flutamide is absorbed into the skin and systemic absorption has been reported. In a study to test the efficacy of topical formulations of finasteride and flutamide to re-enlarge hair follicles in male-pattern baldness was performed by an experimental model of human scalp skin graft transplanted onto SCID mice. A comparison was made between finasteride and flutamide in terms of the mean hairs per graft, length, diameter of the shafts, and structures of the growth stages of the hair. Flutamide and finasteride had a significantly higher effect than the placebo in all the parameters, but flutamide (representing the anti-androgenic mechanism) indicated more hair per graft and longer hair shafts than finasteride (7).

In the 'evidence-based guideline for the treatment of androgenetic alopecia in women and in men' which was published recently; authors reported that they cannot make a recommendation for topical alfatradiol in male patients at the present time and they suggested that topical fluridil should not be used in male patients with androgenetic alopecia. Also, authors reported that they cannot make a recommendation for the use of topical alfatradiol and topical fluridil to improve or prevent progression of androgenetic alopecia in female patients at the present time (8).

Taheri et al. reported a woman presented with becker nevus. The patient stated the unsuccessful response of the prior treatments with Q-switch lasers and topical hydroquinone. A topical 4% solution of flutamide was applied twice daily to the affected area. After 8 weeks of therapy, the hyperpigmentation was significantly reduced. No significant change to the hypertrichosis in the area was observed. There was not any cutaneous or



# 4<sup>th</sup> INDERCOS

## Dermatology and Cosmetology Congress with International Participants

27 - 30 MARCH, 2019  
HILTON ISTANBUL BOSPHORUS HOTEL  
ISTANBUL, TURKEY



systemic adverse effects. Since becker nevus is thought to be an androgen dependent lesion, this case report presented a potential treatment process for this disorder (9). An experimental study in mice with the use of topical flutamide ointment showed that androgen receptor antagonists may facilitate reepithelialization of the wound by promoting keratinocyte migration.

Hormonal factors play a role in melasma pathogenesis. In a study with 74 women with melasma, the participants were divided into two groups as patients treated with 4% hydroquinone cream, and patients treated with 1% flutamide cream. The authors reported that the results of patient satisfaction and melasma area and severity index score were statistically significant in the patients treated with topical flutamide. The result suggested that topical flutamide may be considered in the treatment of melasma.

Androgens have long been implicated in acne pathogenesis. They regulate genes responsible for sebaceous gland growth and sebum production. Cortexolone 17 $\alpha$ -propionate is a new potent topical antiandrogen. A study evaluated the safety and efficacy of cortexolone 17 $\alpha$ -propionate 1% cream in acne vulgaris comparing with placebo and tretinoin cream. Cortexolone 17 $\alpha$ -propionate 1% cream was well tolerated, and was significantly better than placebo in clinical efficacy parameters. In the comparison with tretinoin, cortexolone 17 $\alpha$ -propionate cream was clinically more effective without reaching a statistically significant level (10). ASC-J9 selectively promotes the degradation of the androgen receptor and in this way performs its antiandrogenic effects. A topical formulation of ASC-J9 has been shown to reduce the sebaceous gland size and decrease sebum production.

### References

1. Brown AL, Gordon J, Hill S. Hyperhidrosis: review of recent advances and new therapeutic options for primary hyperhidrosis. *Curr Opin Pediatr.* 2014;26(4):460-5.
2. Glaser DA, Galperin TA. Managing hyperhidrosis: emerging therapies. *Dermatol Clin.* 2014;32(4):549-53.
3. Artzi O, Loizides C, Zur E, Sprecher E. Topical Oxybutynin 10% Gel for the Treatment of Primary Focal Hyperhidrosis: A Randomized Double-blind Placebo-controlled Split Area Study. *Acta Derm Venereol.* 2017;97(9):1120-1124.
4. Glaser DA, Hebert AA, Nast A, Werschler WP, et al. Topical glycopyrronium tosylate for the treatment of primary axillary hyperhidrosis: Results from the ATMOS-1 and ATMOS-2 phase 3 randomized controlled trials. *J Am Acad Dermatol.* 2019;80(1):128-138.
5. Nasir A, Bissonnette R, Maari C, DuBois J, et al. A phase 2a randomized controlled study to evaluate the pharmacokinetic, safety, tolerability and clinical effect of topically applied Umeclidinium in subjects with primary axillary hyperhidrosis. *J Eur Acad Dermatol Venereol.* 2018;32(1):145-151.
6. Sovak M, Seligson AL, Kucerova R, Bienova M, Hajdich M, Bucek M. Fluridil, a rationally designed topical agent for androgenetic alopecia: first clinical experience. *Dermatol Surg.* 2002;28(8):678-85.
7. Sintov A, Serafimovich S, Gilhar A. New topical antiandrogenic formulations can stimulate hair growth in human bald scalp grafted onto mice. *Int J Pharm.* 2000 Jan 20;194(1):125-34.
8. Kanti V, Messenger A, Dobos G, Reygagne P, et al. Evidence-based (S3) guideline for the treatment of androgenetic alopecia in women and in men - short version. *J Eur Acad Dermatol Venereol.* 2018;32(1):11-22.
9. Taheri A, Mansoori P, Sandoval LF, Feldman SR. Treatment of Becker nevus with topical flutamide. *J Am Acad Dermatol.* 2013;69(3):e147-8.
10. Trifu V, Tiplica GS, Naumescu E, Zalupca L, et al. Cortexolone 17 $\alpha$ -propionate 1% cream, a new potent antiandrogen for topical treatment of acne vulgaris. A pilot randomized, double-blind comparative study vs. placebo and tretinoin 0.05% cream. *Br J Dermatol.* 2011;165(1):177-83.



# 4<sup>th</sup> INDERCOS

## Dermatology and Cosmetology Congress with International Participants

27 - 30 MARCH, 2019  
HILTON ISTANBUL BOSPHORUS HOTEL  
ISTANBUL, TURKEY



### AMPUTEE PROBLEMS IN DERMATOLOGY

Ercan Arca

Skin problems are common in amputee patients because the stump of the lower limb amputees is exposed to several unnatural conditions when prosthesis is used, such as shear and stress forces, increased humidity and prolonged and moist contact with the prosthesis, resulting in exposure to its constituent chemical compounds. In general population, extremity amputation is performed due to various indications, such as peripheral vascular diseases, trauma, diabetes mellitus, congenital anomalies and malignancies, but in some conditions like continuous stream of terrorism-related skirmishes and the frequent use of land mines by terrorist groups the main cause of amputations are wounds from mine explosions, gunshots.

The skin problems in amputee patients may vary from simple abrasions to very serious clinical conditions. The most common problems are burning sensation, erythema, and desquamation. With chronicity, painful fissures, secondary eczematization, blister and erosions, skin thickening, lichenification, callosities, and hyperkeratosis may also occur. Allergic and irritant contact dermatitis, bacterial and fungal infections, miliaria, verrucous hyperplasia, follicular hyperkeratosis, epidermoid cysts, Kaposi-like acroangiadermatitis and neoplasia have also been reported.

In this presentation the skin problems of amputee patients will be summarized.

#### References

- Colgecen E, Korkmaz M, Ozyurt K, Mermerkaya U, Kader C. A clinical evaluation of skin disorders of lower limb amputation sites. *Int J Dermatol* 2016;55:468-72.
- Koc E, Tunca M, Akar A, Erbil AH, Demiralp B, Arca E. Skin problems in amputees: a descriptive study. *Int J Dermatol* 2008;47:463-6.
- Meulenbelt HEJ, Geertzen JHB, Jonkman MF, Dijkstra PU. Skin problems of the stump in lower limb amputees: 2. influence on functioning in daily life. *Acta Derm Venereol* 2011;91:178-82.
- Meulenbelt HEJ, Geertzen JHB, Dijkstra PU, Jonkman MF. Skin problems in lower limb amputees: an overview by case reports. *J EADV* 2007;21:147-55.
- Meulenbelt HEJ, Geertzen JHB, Jonkman MF, Dijkstra PU. Skin problems of the stump in lower limb amputees: 1. A clinical study. *Acta Derm Venereol* 2011;91:173-7.
- Meulenbelt HEJ, Geertzen JHB, Jonkman MF, Dijkstra PU. Determinants of skin problems of the stump in lower-limb amputees. *Arch Phys Med Rehabil* 2009;90:74-81.





# 4<sup>th</sup> INDERCOS

## Dermatology and Cosmetology Congress with International Participants

27 - 30 MARCH, 2019  
HILTON ISTANBUL BOSPHORUS HOTEL  
ISTANBUL, TURKEY



### EGG, MILK AND NUTS IN DERMATOLOGY

#### D. Deniz Demirseren

Food allergies are very common in children. Common causative foods include egg, cow's milk and nuts. Skin and mucous membrane symptoms are frequently observed in addition to the gastrointestinal and respiratory system. Skin symptoms are; erythema, urticaria, angioedema, pruritus, burning, sensation, eczema. Mucosal symptoms are conjunctival hyperemia and edema, pruritus, lacrimation, blepharidema rhinorrhea, nasal congestion, sneezing discomfort, swelling of the oral cavity, pharynx, lips or tongue. The most common mechanism of food allergy is IgE-mediated reactions, which cause immediate reactions within 2 hours after the exposure to food allergens. Non-IgE mediated reaction is a food allergic reaction that occurs independent of IgE.

Infantile atopic dermatitis is the most common food allergy during childhood. Eczema often remits with the elimination of allergenic foods. Common causative foods include egg, cow's milk and nuts. In the Immediate-type food allergy develops immediate symptoms after ingestion through IgE-dependent mechanisms. Infants may develop immediate symptoms when they ingest egg, cow's milk and other causative foods for the first time.

On the other hand, Human Breast Milk (HBM) has been analyzed for its various medicinal properties. HBM's specialized immune components have exhibited antimicrobial properties that are responsible for HBM's notable efficacy in decreasing antimicrobial colonization in vitro. Topical HBM apply twice a day has been shown to significantly decrease post-treatment severity scores (EASI, TEWL and IDQLI).

In this speech, I will mention about the skin symptoms and diseases caused by eggs, milk and nuts, as well as the use of HBM in the treatment.



# 4<sup>th</sup> INDERCOS

## Dermatology and Cosmetology Congress with International Participants

27 - 30 MARCH, 2019  
HILTON ISTANBUL BOSPHORUS HOTEL  
ISTANBUL, TURKEY



### **PDL1, BTK/ITK AND PROTEOSOME PATHWAYS FOR SKIN DISEASES**

**Ezgi Erdal**

The PD-1 (programmed cell death-1) receptor is expressed on the surface of activated T cells. Its ligand, PD-L1 expressed on the surface of dendritic cells or macrophages or tumor cells. Engagement of PD-L1 with PD-1 of T cell creates T cell dysfunction, exhaustion, neutralization, and interleukin-10 production in a tumor mass. The anti-PD1 antibodies, nivolumab and pembrolizumab demonstrate an improved response rate and survival as compared to ipilimumab and chemotherapy in patients with melanoma. On 2014, the FDA approved using Nivolumab for treating patients suffer from metastatic or unresectable melanoma and disease that worsens after ipilimumab treatment. Cutaneous drug eruption was reported 14.3% for nivolumab, hopefully respond well to topical corticosteroids. Other side effects reported pruritus 13%, vitiligo 7.5%, xerosis 5.3%, alopecia 2%, de novo psoriasis, and rarely autoimmune bullous dermatosis. (1, 2)

Ibrutinib, an oral inhibitor of BTK (Bruton tyrosine-kinase inhibitor), exerts anti-cancer effects by inhibiting BTK required for replication and metastasis of tumor cells. There are some case reports with successful use in treatment cutaneous diffuse large B-cell lymphoma, mantle cell lymphoma.(3)

Bortezomib is a proteasome inhibitor, it is reported that bortezomib alleviates atopic dermatitis by increasing claudin 1 protein expression. And also there is going on researches about using on melanoma patients.

1. Philips GK, Atkins M. Therapeutic uses of anti-PD-1 and anti-PD-L1 antibodies. *International immunology*. 2015;27(1):39-46.
2. Siegel J, Totonchy M, Damsky W, Berk-Krauss J, Castiglione F, Jr., Sznol M, et al. Bullous disorders associated with anti-PD-1 and anti-PD-L1 therapy: A retrospective analysis evaluating the clinical and histopathologic features, frequency, and impact on cancer therapy. *J Am Acad Dermatol*. 2018;79(6):1081-8.
3. Fox LC, Yannakou CK, Ryland G, Lade S, Dickinson M, Campbell BA, et al. Molecular Mechanisms of Disease Progression in Primary Cutaneous Diffuse Large B-Cell Lymphoma, Leg Type during Ibrutinib Therapy. *International journal of molecular sciences*. 2018;19(6).



# 4<sup>th</sup> INDERCOS

## Dermatology and Cosmetology Congress with International Participants

27 - 30 MARCH, 2019  
HILTON ISTANBUL BOSPHORUS HOTEL  
ISTANBUL, TURKEY



### CAMELLIA SINENSIS, FLAVONOIDS AND TEA TREE OIL IN DERMATOLOGY

Ufuk Kavuzlu

Today, a growing number of patients prefer herbal medicine as a complementary dermatological treatment. Patients sometimes consider these treatments as the only option left. In recent years, more evidence has been obtained about the effectiveness of herbal medicine in dermatology as a result of understanding different cultures together with globalization.(1,2) Tea (camellia sinensis) is one of the most commonly consumed beverages across the globe. Sin catechins are green tea leaf extract obtained from camellia sinensis plant. Sin catechins have immunomodulatory, antioxidative, antiviral and antitumoral properties. (3,4) Flavonoids are polyphenolic compounds found especially in fruits and vegetables. Flavonoids inhibit ultraviolet A dependent DNA damage and they have sun-protective effects on skin. (5) Tea tree oil (TTO) is a monoterpene-rich oil obtained from the plant melaleuca alternifolia. There are studies reported that it is effective in acne vulgaris, seborrheic dermatitis and wound healing as well as antibacterial, antiviral and antifungal efficient.(6,7)

#### References :

1. Reuter J, Merfort I, Schempp CM. Botanicals in dermatology: an evidence-based review. Am J Clin Dermatol. 2010;11(4):247-67.
2. Jakus J, Siegel DM. Commentary: Complementary dermatology. Clin Dermatol. 2018 May-Jun;36(3):279-281.
3. Katiyar S, Elmets CA, Katiyar SK. Green tea and skin cancer: photoimmunology, angiogenesis and DNA repair. J Nutr Biochem. 2007 May;18(5):287-96.
4. Padilla Espana L, Mota-Burgos A, Martinez Amo JL, et al. Recalcitrant molluscum contagiosum successfully treated with sin catechins. Dermatol Ther. 2016 Jul;29(4):217-8.
5. Di Francesco S, Savio M, Bloise N, et al. Red grape (Vitis vinifera L.) flavonoids down-regulate collagen type III expression after UV-A in primary human dermal blood endothelial cells. Exp Dermatol. 2018 Sep;27(9):973-980.
6. Bagherani N, Smoller BR. Role of tea tree oil in treatment of acne. Dermatol Ther. 2015 Nov-Dec;28(6):404.
7. Pazyar N, Yaghoobi R, Bagherani N, Kazerouni A. A review of applications of tea tree oil in dermatology. Int J Dermatol. 2013 Jul;52(7):784-90.



# 4<sup>th</sup> INDERCOS

## Dermatology and Cosmetology Congress with International Participants

27 - 30 MARCH, 2019  
HILTON ISTANBUL BOSPHORUS HOTEL  
ISTANBUL, TURKEY



### SECONDARY SKIN MANIFESTATIONS AFTER INTERNAL SURGERY (BARIATRIC SURGERY AND MASTECTOMY)

**Cahit Yavuz**

All surgical procedures have outcomes about skin. Most of them related with surgical technique. Secondary skin manifestations after bariatric surgery and mastectomy will be discussed in this paper.

Obesity is a serious health problem. According to World Health Organisation, obesity is the fifth leading cause of death leading to over 2,8 million deaths annually. Bariatric surgery is considered when non-surgical treatments fail. Three main categories of bariatric surgery exists. It can be restrictive, malabsorptive or combined restrictive-malabsorptive. These procedures have several complications, some of them related to procedure and the others related to long term changes.

Direct cutaneous complications of bariatric surgery: Infections, wound dehiscence, necrosis, scarring, suture granuloma, lymphedema and neuropathy are the cutaneous complications of bariatric surgery. Many of these complications related to performed technique except neuropathy.

Skin diseases that may benefit from bariatric surgery: Psoriasis vulgaris, acne inversa or hidradenitis suppurativa and necrobiosis lipoidica are the dermatoses that benefit from bariatric surgery.

Skin diseases may develop or aggravated after bariatric surgery : Bowel associated dermatosis arthritis syndrome (BADAS), glossitis, angular cheilitis, erythematous desquamative dermatitis, pellegra like eruption and phrynoderma, alopecia, fungal infections, eczema, pruritis, excessive perspiration and hygien issues, and vasculitis are dermatoses that may develop or aggravate after bariatric surgery.

Patient education and follow-up after bariatric surgery:

Obtain full anamnesis of patient; surgery type, current and past nutritional status, dermatological history, and present complains.

Physical exam; complete examination of skin and mucosal areas.

Educate patient for personal hygien care for surplus skin

Suggest to use emolients; there are many deficiencies lead to xerosis

Let to know patient for delayed healing after surgery

Follow-up patient in personalized periods after surgery for other skin conditions.

Mastectomy is the surgical term for used for usually breast cancer treatment but it can also be used to prevent the disease in people with a high probability of developing it. Mastectomy is an umbrella term, there are differences among the procedures that comprise the surgical category. There are several different types of mastectomies, based on how surgery done and how much tissue is removed.

Pain or tenderness, swelling at the surgery site, infection, haematoma, seroma, numbness in the chest or arm, neuropathic pain also called post-mastectomy pain syndrome, are the side effects. Most important post-mastectomy issue is cutaneous metastasis. Cutaneous metastases can have different clinical patterns, the most common manifestations are nodules. Other less common presentations may include ulcers, erythema (carcinoma erysipeloides), plaques, or zosteriform distribution. Carcinoma erysipeloides is a rare variant of metastatic disease and is usually associated with intraductal breast carcinoma.

Cutaneous metastasis must be first diagnosis after mastectomy. All mastectomy patients must be follow-up regularly and be confirmed about newly developed skin lesions.





# 4<sup>th</sup> INDERCOS

## Dermatology and Cosmetology Congress with International Participants

27 - 30 MARCH, 2019  
HILTON ISTANBUL BOSPHORUS HOTEL  
ISTANBUL, TURKEY



### THE LIFE CYCLES AND THE BIOLOGICAL END PATHWAYS OF DERMAL FILLERS

Dilek Başaran

Soft tissue augmentation is one of the most frequent performed procedure among all aesthetic procedures. There is a wide range of products that can provide correction via different mechanisms. Understanding the biological pathways of each material is necessary for the clinician to achieve the maximum clinical outcome.

Temporary fillers such as hyaluronic acid is mostly used for their physically space occupying properties. They are catabolised over time and the treated area returns its pretreated status in months. In contrast, dermal fillers like CaHA and PLLA produce effects through mechanisms that involve the stimulation of fibroblast ingrowth and the production of extracellular matrix. Their clinical effect lasts 1–2 years or longer. It is essential for the practitioners to know and understand the life cycles and the biological end pathways of dermal fillers to develop an algorithm for their practice.

#### REFERENCES

- Ahn CS, Babar KR. The life cycles and the biological end pathways of dermal fillers. *Journal of Cosmetic Dermatology*. 2014 Sep; 13: 212—223.
- Mochizuki M, Aoi N, Gonda K, Hirabayashi S, Komuro Y. Evaluation of the in vivo kinetics and biostimulatory effects of subcutaneously injected hyaluronic acid filler. *Plast Reconstr Surg*. 2018 Jul;142(1):112-121.
- Maytin EV. Hyaluronan: More than just a wrinkle filler. *Glycobiology*. 2016 Jun; 26(6): 553-9.
- Wollina U, Wiegand C, Hipler UC. Calcium hydroxylapatite microspheres- biocompatibility and clinical effects. *Georgian Med News*. 2018 May; (278): 62-68.
- Kadouch JA. Calcium hydroxylapatite: A review on safety and complications. *J Cosmet Dermatol*. 2017 Jun; 16(2): 152-161.
- Stein P, Vitavska O, Kind P. The biological basis for poly-L-lactic acid-induced augmentation. *J Dermatol Sci*. 2015 Apr ;78(1) :26-33.

Hyaluronic products such as Restylane, Perlane, and Juv Mederm provide esthetic effects by physically occupying space within the tissue. After these biological materials are metabolized by normal catabolic processes, the correction is lost over the course of months and the treated area returns to pretreatment status. In contrast, the long-lasting dermal fillers are characterized by a clinical effect that lasts 1–2 years or longer. These products produce esthetic effects through mechanisms that involve the stimulation of fibroblast ingrowth and the production of extracellular matrix.



# 4<sup>th</sup> INDERCOS

## Dermatology and Cosmetology Congress with International Participants

27 - 30 MARCH, 2019  
HILTON ISTANBUL BOSPHORUS HOTEL  
ISTANBUL, TURKEY



### IS THERE A RIGHT WAY FOR TREATING TEMPORAL REGION WITH FILLERS?

Sadiye Kuş

Similar to any other cosmetic unit of the face, temporal region also undergoes through age-related changes. The appearance of temporal crest, the lateral superior orbital ridge, and the zygomatic arch becomes more prominent and create a skeletonized effect on the face<sup>1</sup>. Overly scaphoid temporal hollows occur as a result of skin thinning, temporalis muscle atrophy and superficial and deep temporal fat pad atrophy.

Temporal region is often missed during filler treatments. The correction of temporal hollowness is a great opportunity to give back to face its oval shape naturally. Besides treating the skeletonized appearance of the face, temporal fillers can also reduce the signs of age-related changes in the middle and lower face, ie "marionette line" and jowl deformity due to lifting effect.<sup>1</sup>

Techniques for treating temporal volume loss are primarily based on the injection of soft-tissue fillers into two different planes: superficial—into the subcutaneous plane; and deep - onto the bone.<sup>2,3</sup> Product selection and the amount of filler to be used depend on the superficial and deep plane techniques, skin thickness, and the degree of temporal hollowing.

The dangers in temporal area are superficial temporal artery, middle temporal artery, anterior and posterior deep temporal arteries and superficial plexus of veins.<sup>2,4</sup> Intracranial penetration is also a possible concern.<sup>5</sup>

In order to treat the senescent face as a whole, considering the safe correction of temporal region with fillers is very rewarding.

Suwanchinda A, Webb KL, Rudolph C, et al. The posterior temporal supraSMAS minimally invasive lifting technique using soft-tissue fillers. *J Cosmet Dermatol*. 2018 Aug 9

Sykes JM, Cotozana S, Trevidic P, et al. Upper Face: Clinical Anatomy and Regional Approaches with Injectable Fillers. *Plast Reconstr Surg*. 2015 Nov;136(5 Suppl):2045-2185

Moradi A, Watson J. Current Concepts in Filler Injection. *Facial Plast Surg Clin North Am*. 2015 Nov;23(4):489-94.

Van Loghem JAJ. Use of calcium hydroxylapatite in the upper third of the face: Retrospective analysis of techniques, dilutions and adverse events. *J Cosmet Dermatol*. 2018 Dec;17(6):1025-1030.

Philipp-Dormston WG, Bieler L, Hessenberger M. Intracranial Penetration During Temporal Soft Tissue Filler Injection-Is It Possible? *Dermatol Surg*. 2018 Jan;44(1):84-91.



# 4<sup>th</sup> INDERCOS

## Dermatology and Cosmetology Congress with International Participants

27 - 30 MARCH, 2019  
HILTON ISTANBUL BOSPHORUS HOTEL  
ISTANBUL, TURKEY



### TREATMENT OF FACIAL ERTHEMA WITH INTENSE PULSED LIGHT LASER

**Zeynep Demirçay**

Telangiectasia and redness are among the most common visible signs of rosacea in patients presenting to dermatology clinics.<sup>1</sup> These features frequently become a psychological burden and can substantially impact patients' quality of life and self-esteem.<sup>2</sup> Because these are the results of vascular abnormalities, they can be treated with lasers and light devices, which target oxyhemoglobin, deoxyhemoglobin and methemoglobin.<sup>3</sup> Pulse dye laser (PDL), the potassium titanyl phosphate (KTP) laser, the 1064-NDYAG laser and intense pulsed light laser (IPL) sources are popular treatment option. While lasers use selective photothermolysis, IPL devices emit noncoherent light at a wavelength of 500 to 1200 nm. Different wavelengths can be emitted from the IPL using various filters. Selective Wave Band Technology (SWT) is an advanced form of IPL that uses dual mode filtering to restrict the wavelengths not necessary for the target. SWT made it possible to create a narrowband pulse of light as short as 0.5 ms.<sup>4,5</sup> SWT allows safer and more effective treatments. Recently, Kim et al found no significant difference between PDL and short-pulsed IPL for treatment of rosacea.<sup>5</sup> Multiple pass techniques also can be used to enhance efficacy of IPL devices.<sup>6</sup> Data on the latest generation of IPL suggest that it is safe and effective treatment of erythematotelangiectatic rosacea.

#### References

- Baldwin HE. Diagnosis and treatment of rosacea: state of the art. *J Drugs Dermatol* 2012;11:725-30.
- Tan SR, Tope WD. Pulsed dye laser treatment of rosacea improves erythema, symptomatology, and quality of life. *J Am Acad Dermatol* 2004;51:592-99.
- Tangetti EA, Mirkov M, Sierra RA. Common vascular lesions. In: Raulin C, Karsai S, eds. *Laser and IPL Technology in Dermatology and Aesthetic Medicine*. Berlin, Germany : Springer-Verlag Berlin Heidelberg;2011:227-240.
- Moy WJ, Yakel JD, Osorio tSUOC, et al. Targeted narrowband intense pulsed light on cutaneous vasculature. *Lasers Surg Med* 2015;47:651-657.
- Kim BY, Moon H-R, Ryu HJ. Comparative efficacy of short -pulsed intense pulsed light and pulsed dye laser to treat rosacea. *J Cosmet Laser Ther* 2018;00:1-6.
- Tsunoda K, Akasaka K, Akasaka T et al. Successful treatment of erythematotelangiectatic rosacea with intense pulsed light: Report of 13 cases. *J dermatol* 2018;45:1113-1116.



# 4<sup>th</sup> INDERCOS

**Dermatology and Cosmetology Congress  
with International Participants**

27 - 30 MARCH, 2019  
HILTON ISTANBUL BOSPHORUS HOTEL  
ISTANBUL, TURKEY



## **BLEPHAROPLASTRY TECHNIQUES & COMBINATION TREATMENTS**

**Konstantin Neamonitos**

Blepharoplasty is a surgical operation for cosmetic and functional purposes.

The target of blepharoplasty is to remove excess skin and parts of fat pads of the upper and lower eye lids. The combination treatments of Laser Blepharoplasty and Laser Resurfacing of the orbital area can be very effective if they are performed methodically and carefully and they have the desired results on the upper - lower eyelids, tear trough, periorbital and cheek wrinkles.





# 4<sup>th</sup> INDERCOS

## Dermatology and Cosmetology Congress with International Participants

27 - 30 MARCH, 2019  
HILTON ISTANBUL BOSPHORUS HOTEL  
ISTANBUL, TURKEY



### **PERSISTENT ADVERSE SIDE EFFECTS OF HYALURONIC ACID FILLERS**

**John Katsantonis**

Hyaluronic Acid fillers for aesthetic indications, are in general considered safe and effective. However, side effects may sometimes occur. Although most of them are mild and easily managed, cases of serious complications have been repeatedly reported. To a great degree, the following reactions should be noted: Persistent swelling, redness along with Tyndall phenomenon, solid tenacious firm nodules or even diffuse skin hardening (sometimes painful, together with prolonged perilesional edema), late insistent foreign body granulomas, tissue necrosis and in fortunately extremely rare cases even blindness due to embolism. Precautions and proper treatment - relieve strategies are to be discussed.



# 4<sup>th</sup> INDERCOS

## Dermatology and Cosmetology Congress with International Participants

27 - 30 MARCH, 2019  
HILTON ISTANBUL BOSPHORUS HOTEL  
ISTANBUL, TURKEY



### **AESTHETIC EAR RECONSTRUCTION FOR DERMATOLOGIST**

**Hasan Mete Aksoy**

Reconstruction of partial ear defects is one of the most challenging areas within reconstructive surgery of the head and neck region. As a result of the exposed position the auricle is a frequent site of neoplastic and traumatic injury that can result in structural deformity and tissue loss. Acquired deformities of the auricle are most commonly caused by bite injuries (35–72%). Approximately 5 to 8% of skin cancers develop on the external ear and squamous and basal cell carcinomas are the most common cancers in this location. Auricular melanoma is rare and represents only 1% of all cutaneous melanomas. A deformity or partial defect of the auricle can disrupt facial aesthetics and lead to significant psychological morbidity for the affected patient. Each case of auricular reconstruction is unique and requires a systematic approach that involves defect size and location, the quality of the surrounding skin, patient preference, and experience of the operator. The various convexities and concavities of the external ear combined with concomitant differences in tissue rigidity and elasticity explain the wide variety of partial auricular defects observed in clinical practice. The relevant anatomy must be known in detail. There are different reconstructive approaches for defects of the upper-, middle-, and lower-third of the auricle.

Small full-thickness defects (< 1.5 cm) of the helix and antihelix in upper part of the auricle can be repaired by conversion to a wedge-shaped resection and this is followed by primary layered closure. For reconstruction of auricular defects up to 2.5 cm in size, crescentic or star excisions can be used to distribute tension of closure throughout the auricle. Composite grafts obtained from the contralateral ear are another option for helical rim defects of this size. For auricular defects > 2.5 cm and confined to the helical rim, multi staged pre- or postauricular tubed flaps may be considered. In situations with a skin deficit, composite pedicled flaps can be used.

Reconstruction of middle-third auricular defects is based on similar surgical principles to those of the upper third defects.

The lobule forms the lower third of the auricle and does not contain a cartilage framework. Soft tissue mobility and redundancy of the lower ear region often allow for direct closure of small, soft tissue only defects in this region. Defects comprising upto 50% of the lobule can be closed directly with minimal resulting deformity. For larger or total lobular defects, staged reconstruction with autologous cartilage grafting using either conchal or septal cartilage can be performed. Fat grafting for lobular augmentation is very useful to treat volume asymmetry.

In conclusion, successful results in auricular reconstruction depend on the surgeon's careful analysis of the defect as well as knowledge of the different reconstructive options available for each defect.



# 4<sup>th</sup> INDERCOS

## Dermatology and Cosmetology Congress with International Participants

27 - 30 MARCH, 2019  
HILTON ISTANBUL BOSPHORUS HOTEL  
ISTANBUL, TURKEY



### TRUES AND MYTHS ABOUT INJECTABLE THREADS

**Tilemachos Anthopoulos**

One of the main goals of Cosmetic Dermatology is the rejuvenation, tightening and lifting, of the body and face tissues, with the safest, fastest, non-surgical with minimal down time and low risk of complications for the patient, procedure.

The history of threads and their application to the face, begins several decades ago. In 1956, Buttkevitiz published the improvement of the depth of nasolabial folds with a nylon suture technique. In contrast of what, most companies claim that, PDO threads is a relatively new treatment, they have been used for soft tissue lifting at early nineties. In 1992, G. Ruff, a plastic surgeon, successfully applied them to treat a patient's post-traumatic ectropion of lateral canthus after multiple unsuccessful surgical treatments. Since then, several types of threads and their application techniques have been published. Although, complications such as, asymmetry and 'cheese wiring', as well as the tendency for rapid treatments with minimal down time and long lasting results have prompted doctors and companies to develop new techniques such as injectable threads.

For all these reasons, their application to rejuvenate and lift tissues is becoming more and more popular. On the other hand, however, there is a strong concern in the medical community about the effectiveness and duration of this treatment. Is it really, a revolutionary and reliable method (such as the injection of botulinum toxin, hyaluronic acid, etc.) or is it a «firework»? Is the physician's credibility with his patient at risk, if he does not consulting properly?

We will try to analyze the above-mentioned benefits and concerns, based on the latest scientific facts.

Thread-lift for facial rejuvenation: assessment of long-term results. Abraham RF, DeFatta RJ, Williams EF 3rd. Arch Facial Plast Surg. 2009 May-Jun;11(3):178-83.

Outcomes in threadlift for facial rejuvenation. Garvey PB, Ricciardelli EJ, Gampper T. Ann Plast Surg. 2009 May;62(5):482-5.

Incidence of complications and early recurrence in 29 patients after facial rejuvenation with barbed suture lifting. Rachel JD, Lack EB, Larson B. Dermatol Surg. 2010 Mar;36(3):348-54.

Barbed sutures: a review of the literature. Villa MT, White LE, Alam M, Yoo SS, Walton RL. Plast Reconstr Surg. 2008 Mar;121(3):102e-108e.

Thread-Lift Sutures: Still in the Lift? A Systematic Review of the Literature. Gülbitti HA, Colebunders B, Pirayesh A, Bertossi D, van der Lei B. Plast Reconstr Surg. 2018 Mar;141(3):341e-347e.

Facial thread lifting with suture suspension. Tavares JP, Oliveira CACP, Torres RP, Bahmad F Jr. Braz J Otorhinolaryngol. 2017 Nov - Dec;83(6):712-719.

Barbed sutures for aesthetic facial plastic surgery: indications and techniques. Paul MD. Clin Plast Surg. 2008 Jul;35(3):451-61.

Incidence of complications and early recurrence in 29 patients after facial rejuvenation with barbed suture lifting. Rachel JD, Lack EB, Larson B. Dermatol Surg. 2010 Mar;36(3):348-54.

Suspension Threads. De Masi EC, De Masi FD, De Masi RD. Facial Plast Surg. 2016 Dec;32(6):662-663.

Rejuvenating the Face: An Analysis of 100 Absorbable Suture Suspension Patients. Ogilvie MP, Few JW Jr, Tomur SS, Teven CM, Semersky AJ, Bruno CR, Kulick NT. Aesthet Surg J. 2018 May 15;38(6):654-663.



# 4<sup>th</sup> INDERCOs

**Dermatology and Cosmetology Congress  
with International Participants**

27 - 30 MARCH, 2019  
HILTON ISTANBUL BOSPHORUS HOTEL  
ISTANBUL, TURKEY



## **ABSTRACT COSMETICAL PROCEDURES FOR CHILDREN**

**Zennure Takci**

In worldwide, cosmetic dermatology has increased in popularity. Adults receive most of the cosmetic treatments; however, procedures are being performed in children with increased frequency. Pediatric cosmetic procedures involve laser treatment of vascular, epidermal, and pigmentary disorders; laser hair removal; acne scar revision; chemical peels; dermal stimulatory agents and fillers; laser hair removal; sclerotherapy for vascular lesions; management of keloids; and botulinum toxin for hyperhidrosis. The field of cosmetic dermatology is evolving fastly, with limited safety and efficacy studies in the pediatric age group. In this oral presentation the author tried to review the selected articles from the literature about cosmetical procedures for children.





# 4<sup>th</sup> INDERCOS

## Dermatology and Cosmetology Congress with International Participants

27 - 30 MARCH, 2019  
HILTON ISTANBUL BOSPHORUS HOTEL  
ISTANBUL, TURKEY



### LIPOFILLING IN PERIORBITAL AREA

Assel Markabayeva

#### Introduction

Lipofilling or autologous fat transplantation has become one of the popularity treatment procedures for facial rejuvenation. By reason of the presence of stem cells in the ASC (Adipose stem Cells) lipograft, the treatment results in tissue regeneration improving the surface texture and her elasticity. Since the introduction of Coleman's fat grafting technique, the fat itself is a natural filler of lost volumes due to gravity, fat atrophy in tissues and bone resorption. Autologous fat grafting can produce variable results, and objective, credible evaluation of volume replacement therapy is still lacking. Scant data exist on the retention of fat volume in a clinical setting. The volume of fat to inject in each facial compartment during autologous fat grafting remains poorly standardized, leading to unsatisfactory results in some patients.

**Aim:** Determine the effect of lipofilling considering each patient individually

**Materials & Methods:** Retrospective study between January 2017 and December 2018 involved 10 women in the medical clinic of Almaty, Kazakhstan. The Global Aesthetic Improvement Scale (GAIS) was used to assess satisfaction with the results. Clinical efficacy was assessed by the researcher and patient after 10 days, 3 months.

**Results:** Post-treatment clinical evaluations showed a marked improvement of lipofilling procedure quality and high patient satisfaction in Skin rejuvenation periorbital rejuvenation at the 10 days to 3 months after baseline. At each visit, patients were queried about adverse events, such as pain, tenderness, swelling, redness, and bruising. Also, the injection sites were examined for erythema, edema, induration, and nodules. None of these symptoms was noted in this research.

#### Conclusions

Post-treatment clinical evaluations showed a marked improvement of lipofilling procedure quality and high patient satisfaction in Skin rejuvenation periorbital rejuvenation at the 10 days to 3 months after baseline. We consider that the lipofilling procedure in the periorbital area justified in order to correct the periorbital fold depression, reduce wrinkles and improve skin texture.

#### References

- Coleman S.R. Long-term survival of fat transplants: controlled demonstrations. *Aesthet. Plast. Surg.* 1995;19:421–425
- Coleman SR. Structural fat grafting: More than a permanent filler. *Plast Reconstr Surg.* 2006;118(Suppl):1085–1205
- Shue S, Kurlander D, Guyuron B. (2017) Fat Injection: A Systematic Review of Injection Volumes by Facial Subunit. *Aesthetic Plast Surg.* 24:1-10
- Rauso R(1), Curinga G, Santillo V, Corvo G, Tartaro G. (2011) Comparison between lipofilling and a nonabsorbable filler for facial wasting rehabilitation in HIV-positive patients. *J Craniofac Surg.* 2011 Sep;22(5):1684-8.
- Elodie B, Benoit C, Sahar B, Christian H, Antoine D, Raphael C, Bruno M, Frederic M, Eric W, Nicolas B. Eyelid fat grafting: Indications, operative technique and complications; a systematic review. *Journal of Cranio-Maxillo-Facial Surgery.* 2016 Apr;44(4):P374–380
- Choi SY, Lee YH, Kim H, Koh HJ, Park SY, Park WS, Bae IH, Park KY, Kim BJ (2014) A combination trial of intradermal radiofrequency and hyaluronic acid filler for treatment of nasolabial fold wrinkles: a pilot study. *J Cosmet Laser Ther* 16(1):37–42
- Gir P, Brown S.A., Oni G., Kashefi N., Mojallal A., Rohrich R.J. Fat grafting: evidence-based review on autologous fat harvesting, processing, reinjection, and storage. *Plast. Reconstr. Surg.* 2012;130:249–258



# 4<sup>th</sup> INDERCOs

**Dermatology and Cosmetology Congress  
with International Participants**

27 - 30 MARCH, 2019  
HILTON ISTANBUL BOSPHORUS HOTEL  
ISTANBUL, TURKEY



## **DERMAL FILLERS FOR FACIAL ANTIAGING**

### **Ulaş Güvenç**

Injectable skin fillers are viable alternative to surgery for the patients seeking a safe, minimally invasive and affordable means of maintaining a youthful appearance. An ideal skin filler should be non-immunogenic, non-carcinogenic, non-teratogenic, non-infectious and non-migratory. It should look and feel natural and show reproducible long-term benefit. There are mainly four techniques for filler injection: serial puncture, linear threading, fanning and cross-hatching. There is no an algorithm for these techniques. Traditional treatments have evolved favorably that, they can eliminate some shortfalls of surgery or can become an alternate approach for appropriate patients. In this article, especially dermal fillers is discussed on facial rejuvenation.

ORAL  
PRESENTATIONS





# 4<sup>th</sup> INDERCOS

## Dermatology and Cosmetology Congress with International Participants

27 - 30 MARCH, 2019  
HILTON ISTANBUL BOSPHORUS HOTEL  
ISTANBUL, TURKEY



### OP-01

## SKIN DISEASES IN RURAL NYALA, SUDAN (IN A RURAL HOSPITAL, IN 12 ORPHANAGES AND IN 2 REFUGEE CAMPS)

*Melike Kibar Ozturk*

*Department of Dermatology, Umraniye Training and Research Hospital, Istanbul, Turkey*

**BACKGROUND AND AIM:** Skin diseases are considered to be common in Nyala, Sudan. This study was carried out to verify the prevalence of skin diseases in Nyala.

**METHODS:** This community-based observational study included skin examination of a total of 1802 people: 620 patients that were evaluated in the outpatient clinic and 1182 people from orphanages and refugee camps in Nyala, Sudan.  $\chi^2$  test was used.

**RESULTS:** A total 1802 people, 620 patients from the outpatient clinic and 1182 people from orphanages and refugee camps in Nyala, Sudan were included in this study.

The total prevalence of skin disorders in the whole study population was 92.6% (1670/1802). 1050 of 1182 (88.8%) people from orphanages and refugee camps had a skin disorder. The most common skin diseases in Nyala were: fungal infections (32.6%), dermatitis/eczema (10.5%), bacterial skin infections (10.3%), disorders of skin appendages (8.7%), parasitic infestations (7.7%), atrophic skin disorders (7.4%), disorders of pigmentation (7.4%), hypertrophic skin disorders (6.4%), viral infections (5.8%), benign neoplasm (1.9%), dermatoses due to animal injury (0.4%), bullous dermatoses (0.1%), and malignant neoplasm (0.1%). The details of the skin diseases in this population are given in Table 1. Forty three percent of fungal infections was tinea capitis superficialis in this study. It was statistically more common in orphanages and refugee camps ( $p < 0.0001$ ) (figure 1). Twenty four percent of parasitic infestations resulted in elephantiasis in this study (figure 2). Hypertrophic and atrophic disorders of the skin were mainly lesions of scarification (mostly atrophic) (5.7%) and keloids (5.6%) (figure 3). Skin disorders like benign neoplasm (1.9%), dermatoses due to animal injury (0.4%), bullous dermatoses (0.1%) and malignant neoplasm (0.1%) were relatively scarce. Five of 8 patients who had dermatoses due to animal injury had full-thickness skin necrosis after bite by an endemic pink lizard (figure 4). Two patients with bullous dermatoses had pemphigus vulgaris confirmed by skin biopsy (figure 5). The proportion of infectious skin diseases at orphanages and refugee camps (65.8%) was significantly higher than the proportion of 41.1% that presented to the outpatient clinic due to an infectious skin disease ( $p < 0.00001$ ). Fungal infection, bacterial infection and parasitic infestation were more common in orphanages and refugee camps while dermatitis and eczema, disorders of skin appendages, hypertrophic and atrophic disorders of the skin, disorders of pigmentation and benign neoplasms were more common in patients that were evaluated in the outpatient clinic.

**CONCLUSION:** The prevalence of skin diseases in the rural Nyala was more than our expectation and was dominated by infectious skin diseases, in contrast with findings in the urban setting. In addition to this, infectious skin diseases were more common in orphanages and refugee camps rather than hospitals.

**Keywords:** Skin diseases, Nyala, Sudan, Sub-Saharan Africa, orphanages, refugee camps





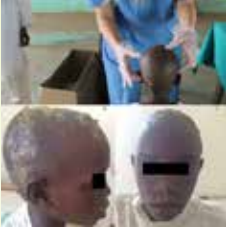# 4<sup>th</sup> INDERCOS

Dermatology and Cosmetology Congress  
with International Participants

27 - 30 MARCH, 2019  
HILTON ISTANBUL BOSPHORUS HOTEL  
ISTANBUL, TURKEY

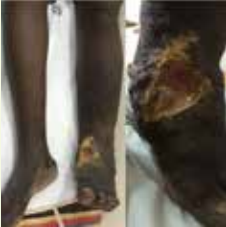

**figure 1**



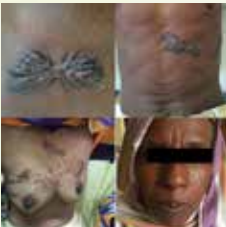*Figure 1a: A child with tinea capitis superficialis in an orphanage. 1b&1c: A child with tinea capitis favosa in our outpatient clinic.*

**figure 2**



*Figure 2: A patient from a refugee camp with elephantiasis and chronic ankle ulcer on her medial malleolus.*

**figure 3**



*Figure 3a&b&c: Minor and major keloids on three different patients in our outpatient clinic, 3d: Atrophic scarification mark (tribal mark) in a woman in a refugee camp.*



# 4<sup>th</sup> INDERCOs

Dermatology and Cosmetology Congress  
with International Participants

27 - 30 MARCH, 2019  
HILTON ISTANBUL BOSPHORUS HOTEL  
ISTANBUL, TURKEY



**figure 4**



Figure 4a: Picture of a pink lizard, 4b: First day of the bite by a pink lizard, 4c: 1 week later after treatment, 4d: 2 weeks later after treatment

**figure 5**

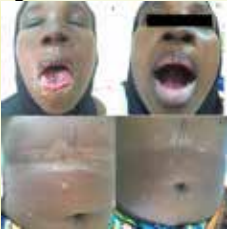

Figure 5a&c: A patient with pemphigus vulgaris before treatment, 5b&d: after treatment.



# 4<sup>th</sup> INDERCOS

## Dermatology and Cosmetology Congress with International Participants

27 - 30 MARCH, 2019  
HILTON ISTANBUL BOSPHORUS HOTEL  
ISTANBUL, TURKEY



**table 1**

Skin disease groups	Patients at our outpatient clinics	Patients at orphanages and refugee camps	Total N	Percentage (%)	P value
All skin disorders	620	1050	1670	92.6	
Fungal infection	148	397	545	32.6	p<0.00001
Dermatitis and eczema	132	44	176	10.5	p<0.00001
Bacterial infection	41	132	173	10.3	p=0.0001
Disorders of skin appendages	102	44	146	8.7	p<0.00001
Parasitic infestation	32	98	130	7.7	p=0.002
Atrophic disorders of the skin	67	57	124	7.4	p=0.00005
Disorders of pigmentation	62	62	124	7.4	p=0.002
Hypertrophic disorders of the skin	63	45	108	6.4	p<0.00001
Viral infection	34	64	98	5.8	p=0.6
Benign neoplasm	26	6	32	1.9	p<0.00001
Dermatoses due to the animal injury	2	6	8	0.4	p=0.4
Bullous dermatoses	2	1	3	0.1	p=0.2
Malignant neoplasm	2	1	3	0.1	p=0.2

*Table 1: Skin disease groups in 620 patients in our outpatient clinic and 1050 patients from orphanages and refugee camps in Nyala.*



# 4<sup>th</sup> Indercos

## Dermatology and Cosmetology Congress with International Participants

27 - 30 MARCH, 2019  
HILTON ISTANBUL BOSPHORUS HOTEL  
ISTANBUL, TURKEY



### OP-02

#### A RARE VARIANT OF CICATRICIAL PEMPHIGOID: BRUNSTING-PERRY TYPE

Emin Ozlu<sup>1</sup>, Yunus Ozcan<sup>1</sup>, Mehmet Gamsızkan<sup>2</sup>

<sup>1</sup>Düzce Üniversitesi Tıp Fakültesi, Dermatoloji Anabilim Dalı, Düzce

<sup>2</sup>Düzce Üniversitesi Tıp Fakültesi, Patoloji Anabilim Dalı, Düzce

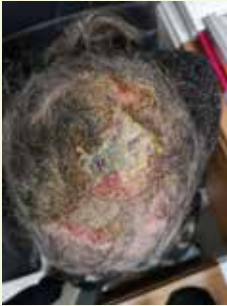Brunsting-Perry pemphigoid (BPP) is a rare subepidermal autoimmune blistering disease is characterized by bullous lesions limited to the head, neck and scalp, with no mucosal involvement. It is as a rare variant of cicatricial pemphigoid and a rare cause of secondary cicatricial alopecia. Autoantibodies to BP180, type VII collagen, and laminin-332 have already been detected; however, the pathomechanisms and autoantigens of BPP remain unknown.

A 61 year-old woman presented with widespread erythema, erosions, and infected areas accompanied by heavy crusting, covering most of her scalp around frontoparietal region (Figure 1). It started ten years ago with a tendency to enlarge. She described no other cutaneous lesions since then. Examination of the oral cavity and ocular mucosa yielded no findings. Histopathologically, subepidermal bulla formation was revealed (Figure 2). Direct immunofluorescence (DIF) examination exhibited linear depositions of IgG and C3 in dermoepidermal junction. Immunohistochemically, type IV collagen staining in the floor of the subepidermal blisters were revealed (Figure 3). She was diagnosed with BPP based on the clinical, histopathological, DIF and immunohistochemical findings. She was started on systemic methylprednisolone and topical clobetasole propionate cream and significant improvement of symptoms and clinical findings were achieved after two weeks. We report this case because of its rarity.

**Keywords:** Alopecia, Brunsting-Perry type pemphigoid, immunoflorescence.

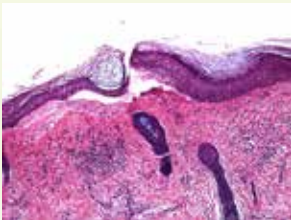


**Figure 1**



*Intense crusting and erosions with erythematous skin in the frontoparietal region of the scalp*

**Figure 2**



*Presence of subepidermal blister*

**Figure 3**



*Immunopositivity of type IV collagen in the floor of the bullae.*



# 4<sup>th</sup> INDERCOS

## Dermatology and Cosmetology Congress with International Participants

27 - 30 MARCH, 2019  
HILTON ISTANBUL BOSPHORUS HOTEL  
ISTANBUL, TURKEY



### OP-03

## CAMELLIA SINENSIS, THE TEA PLANT, EXERTS ANABOLIC EFFECTS ON EXTRACELLULAR MATRIX COMPONENTS OF SKIN

*Erkin Pekmezci*

*Department of Dermatology, Gozde Hospital, Malatya, Turkey*

**INTRODUCTION AND OBJECTIVES:** Tea obtained from *Camellia sinensis* (Cs), a member of Theaceae family, is one of the most ancient, and after water, the most widely consumed beverage in the world. The polyphenolic compounds called catechins are thought to be responsible for the majority of health benefits associated with this plant. The potential health benefits of Cs on skin include; protecting from the damage caused by ionizing and ultraviolet (UV) radiation, improving wound healing, and cancer chemoprevention. It seems certain that hyaluronic acid (HA), collagen and elastin bind each other and make up a three dimensional structure that is impaired in aged or damaged skin due to internal or external causes. It is a common thought that these three components must be increased in order to give skin a younger and healthier appearance. In this study we aimed to reveal the probable direct causes of the mentioned cutaneous health, provided by Cs, and also the effects of this plant on the major extracellular matrix (ECM) components of the human integumentary system.

**MATERIALS-METHODS:** After preparation an extract of Cs and performing its phytochemical analysis, we detected the gene expression levels of selected three enzymes, i.e. hyaluronic acid synthase-2 (HAS-2), matrix metalloproteinase-9 (MMP-9) and elastase which are crucial in the metabolism of HA, collagen, and elastin respectively; in a human dermal fibroblast cell line treated with this phytoextract. Cell proliferation assay was performed by XTT reagent. RNA isolations were carried out from both treated and untreated cell groups by using TRI reagent. Gene expressions of the relevant enzymes, and as control GAPDH were determined by RT-qPCR analysis.

**RESULTS:** Results were represented as "Target/GAPDH Fold Change". Cs phytoextract caused statistically significant downregulation of MMP-9 ( $p=0.011$ ) and elastase ( $p<0.001$ ) gene expressions compared to untreated control cells. Treatment ended up with 0.353 and 0.240 fold change for MMP-9 and elastase respectively. HAS-2 gene expression ended up with 1.518 fold change, which is a positive outcome also, and the upregulation was highly significant ( $p<0.001$ ).

**CONCLUSION:** Cs has substantial anabolic effects on HA, collagen and elastin. With these results it may be referred some direct causes of the protective and preventive features of Cs against the threats to ECM such as excessive UV exposure, radiotherapy, and chronic inflammatory wounds. Breakdown and disorganisation of ECM components are main features of skin aging, and inhibition of pathologic enzymatic activities by natural plant compounds might be a promoting approach to prevent these. In terms of cosmetic dermatology, the revealed encouraging positive effects of Cs on the structural components of skin, render it a promising candidate for long term clinical anti-aging studies.

**Keywords:** *Camellia sinensis*, HAS-2, MMP-9, elastase, anti-aging

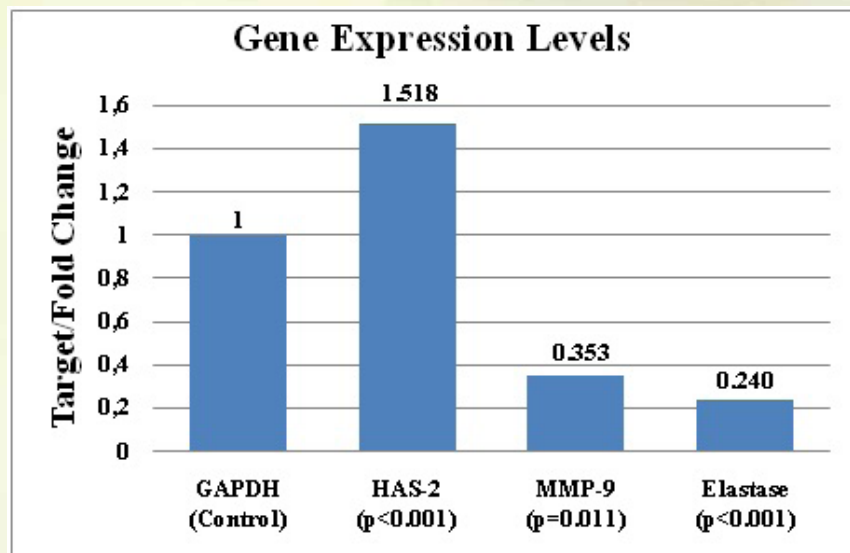


# 4<sup>th</sup> INDERCOS

Dermatology and Cosmetology Congress  
with International Participants  
27 - 30 MARCH, 2019  
HILTON ISTANBUL BOSPHORUS HOTEL  
ISTANBUL, TURKEY



Figure Cs





# 4<sup>th</sup> Indercos

## Dermatology and Cosmetology Congress with International Participants

27 - 30 MARCH, 2019  
HILTON ISTANBUL BOSPHORUS HOTEL  
ISTANBUL, TURKEY



### OP-04

#### **SWEET'S SYNDROME ASSOCIATED WITH BRUCELLOSIS AND URINER TRACT INFECTION**

*Mehmet Melikođlu, Hatice Gencer Bařol, Erdal Pala*

*Department of Dermatology, Atatürk University, Erzurum, Turkey*

Sweet's syndrome or acute febrile neutrophilic dermatosis is characterized by fever, polymorphonuclear leukocytosis, painful erythematous skin lesions as papules, plaques or nodules and dense dermal infiltrate of neutrophils without vasculitis at the site of the lesions. It has been associated with various infections, pregnancy, autoimmune diseases and malignancies. The lesions of Sweet's syndrome often present on the face, trunk, upper and lower extremities, and hands. This syndrome may be associated with upper respiratory tract infection, lung infection, gastrointestinal tract infections.

We report a case of Sweet's syndrome in a 55-year-old woman with urinary tract infection and Brucellosis. The characteristic Sweet's syndrome lesions of the patient started three days ago and increased. The lesions were located on both wrists, palms and back of hands. C-reactive protein, erythrocyte sedimentation rate and Brucella IgG were high in the laboratory tests of the patient. There were findings related to urinary tract infection in the patient's urinalysis. Systemic antibiotic treatment which was effective for both infections and topical steroid treatment was begun. Systemic steroid therapy, which was accepted as the first option in treatment of Sweet 's syndrome, was never used. As a result, after treatment of these infections, all the lesions of the patient were healed.

When we encounter a patient with Sweet's syndrome, we need to keep in mind that the infections might be one of the underlying causes. By presenting this case, we emphasized that it is possible to treat infection-induced Sweet's syndrome with systemic antibiotic treatment without systemic steroid treatment.

**Keywords:** Sweet's Syndrome, Uriner Tract Infection, Brucellosis





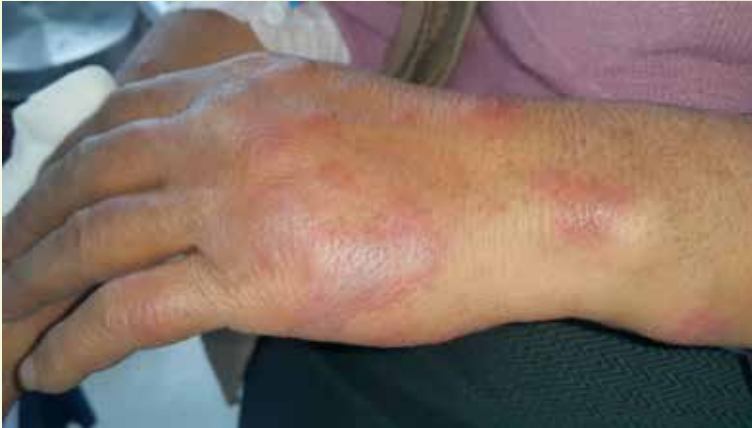# 4<sup>th</sup> INDERCOS

Dermatology and Cosmetology Congress  
with International Participants

27 - 30 MARCH, 2019  
HILTON ISTANBUL BOSPHORUS HOTEL  
ISTANBUL, TURKEY

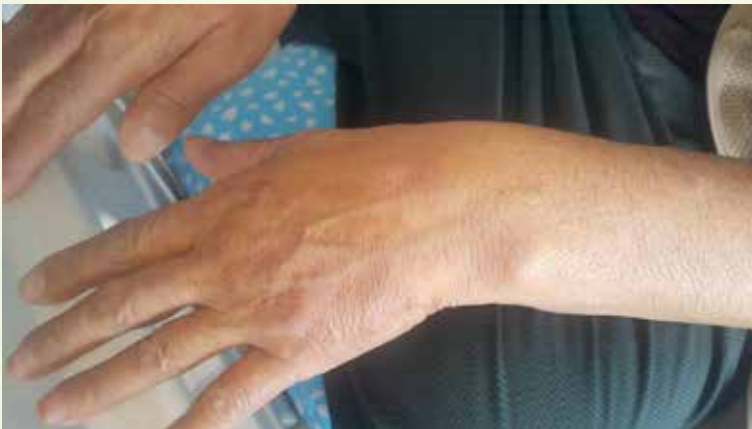

**Picture 1**



*Before Treatment*

**Picture 2**



*After Treatment*



# 4<sup>th</sup> Indercos

## Dermatology and Cosmetology Congress with International Participants

27 - 30 MARCH, 2019  
HILTON ISTANBUL BOSPHORUS HOTEL  
ISTANBUL, TURKEY



### OP-05

#### EVALUATION OF PATCH TEST RESULTS IN PATIENTS WITH ALLERGIC CONTACT DERMATITIS: A SINGLE-CENTER RETROSPECTIVE STUDY

*Ersoy Acer, Hilal Kaya Erdoğan, Tayfun Batan, Zeynep Nurhan Saraçoğlu*  
Department of Dermatology, Eskişehir Osmangazi University, Eskişehir, Turkey

**AIM:** Patch test is used to determine the allergens which cause allergic contact dermatitis. In this study we aimed to evaluate the patch test results in patients with allergic contact dermatitis.

**MATERIALS-METHODS:** Patch test results (European Standard Series) of patients with allergic contact dermatitis between 2017 and 2018 were evaluated retrospectively.

**RESULTS:** Of 135 patients 65 (48.1%) were male, 70 (51.9%) were female. The mean age of patients were  $41.43 \pm 14.26$  (11-78) years. The mean duration of disease was  $35.33 \pm 54.23$  (1-240) months. The most common localization of the lesions were hand (37%), body (27.4%) and face (19.3%), respectively. The most common occupation of patients were construction worker (16.3%) and worker in other fields (10.4%). In 78 (57.8%) of one hundred and thirty five patients, positive reaction against at least one allergen in patch test was detected. The most frequently allergens with positive reaction were nichel (27.4%), potassium dichromate (14.8%) and cobalt (11.9%). Accordingly to gender, localization of the lesions and occupation of patients, there was no significant difference in positive reactions against at least one allergen ( $p > 0.05$ ). And also there was no relation between duration of disease and positive reaction against at least one allergen ( $p = 0.827$ ).

**CONCLUSIONS:** Nichel, potassium dichromate and cobalt were the most common allergens with positive reaction.

**Keywords:** Allergic contact dermatitis, cobalt, nichel, patch test, potassium dichromate

### OP-06

#### EXTRACTION OF ESSENTIAL OILS OF NIGELLE SEED; APPLICATION TO THE FORMULATION AN ANTI-INFLAMMATORY CREAM

*Djedri Bani Safia, Mohandkaci Lamia, Bouderbala Khalida, Fettaka Mohamed*  
Functional Analysis of Chemical Processes Laboratory, Saâd Dahlab Blida 1 University, P.O. Box 270, 09000 Blida, Algeria.

Our work focused id on the extraction by hydrodistillation on microwive of the essential oil of nigella seeds "Nigella sativa L.". An optimization of the formulation parameters of stable and homogeneous parapharmaceutical BIO creams and a study of their anti-inflammatory and antimicrobial activities have been carried out. It has been shown that the formulated cream is a product that has a significant antiinflammatory activity with a percentage of edema reduction of 59.93%. The antimicrobial activity tests carried out by the disk method on five bacterial strains, show that the formulated cream has properties better than the nigella seed hydrolate while retaining the physicochemical properties of a conventional cream with a rheological behavior. rheolfluidifier and a viscosity of 243.35 Pa.s.

**Keywords:** Nigella sativa L, essential oil, parapharmaceutical cream BIO, antimicrobial, anti-inflammatory.



# 4<sup>th</sup> INDERCOS

Dermatology and Cosmetology Congress  
with International Participants  
27 - 30 MARCH, 2019  
HILTON ISTANBUL BOSPHORUS HOTEL  
ISTANBUL, TURKEY



## OP-07

### PICOSURE LASER IN THE TREATMENT OF DIFFERENT SKIN DISORDERS

*Mohammed Abdul Qader Al Malmi<sup>1</sup>*

<sup>1</sup>*Dermatology and Aesthetic medicine*

<sup>2</sup>*Medical village*

<sup>3</sup>*United Arab Emirates*

**BACKGROUND:** - Picosure laser is a new machine designated for the treatment of different aesthetic human skin persistent disorders. It is FDA approved. It is picosecond technology.

**OBJECTIVE:** - The objective of this study is to identify the efficacy of new picosure laser in aesthetic medicine.

**PATIENTS AND METHODS:** - Adults males and females patients presented to medical village clinic in Dubai. They have tattoo, scars, wrinkles, melasma and freckles in different parts in their bodies. We use picosure laser machine in the management wavelength 532 nm and 755 nm or combined.

**RESULTS:** - All the patients presented and treated with picosure laser are cured after one session without any complications and recurrent. The results are impressive without typical downtime or discomfort.

**CONCLUSION:** - Picosure laser is safe, fast and effective in the aesthetic treatment of 1-6 skin types.

**Keywords:** Medical village, Dubai, PicoSure laser. Treatment, Different skin, disorders



# 4<sup>th</sup> INDERCOs

## Dermatology and Cosmetology Congress with International Participants

27 - 30 MARCH, 2019  
HILTON ISTANBUL BOSPHORUS HOTEL  
ISTANBUL, TURKEY



### OP-08

#### VITAMIN D LEVELS AND ITS IMPACT ON THE QUALITY OF LIFE IN PATIENTS WITH CHRONIC SPONTANEOUS URTICARIA

Ragıp Ertas<sup>1</sup>, Kemal Ero<sup>2</sup>

<sup>1</sup>Department of Dermatology, Kayseri City Hospital, Kayseri, Turkey

<sup>2</sup>Department of Rheumatology, Kayseri City Hospital, Kayseri, Turkey

**INTRODUCTION:** Vitamin D has been reported to be associated with chronic spontaneous urticaria (CSU) that limited number of the studies of vitamin D levels in patients with CSU. This study aims to compare the vitamin D levels in CSU patients and healthy controls, secondly to assess the relationship between vitamin D levels and disease activity scores.

**METHODS:** We assessed the 51 patients with CSU for 25 (OH) vitamin D levels with HPLC in a tertiary outpatient clinic. Patients disease activity were assessed by the urticaria control test (UCT), urticaria activity score (UAS) and visual analog scale of physician and patient's global assessment. Furthermore, patients completed a questionnaire to assess the quality of life (QoL) for urticaria and dermatologic diseases.

**RESULTS:** 51 patients with CSU and 20 healthy controls, age and gender were similar ( $p>0,5$ ), enrolled to the study. 25 (OH) vitamin D levels of patients with CSU (mean: 15.30, SD: 7.664) was significantly lower than the healthy controls (mean: 22.34, SD: 11.053) ( $p: 0.003$ ). There was a significant negative correlation between 25 (OH) vitamin levels and dermatologic quality of life index ( $p=0,001$ ,  $r= - 0,451$ ), urticaria quality of life index ( $p=0,025$ ,  $r= - 0,333$ ), and Patient global scores ( $p=0,044$ ,  $r= - 0,242$ ).

**CONCLUSION:** The exact mechanism of the relationship between vitamin D deficiency and chronic urticaria is so far not clear. Considering the obvious effect on the QoL, it shouldn't overlooked the assessment of vitamin D levels in patients with CSU.

**Keywords:** Chronic Urticaria, Vitamin D, Quality of Life





# 4<sup>th</sup> INDERCOS

## Dermatology and Cosmetology Congress with International Participants

27 - 30 MARCH, 2019  
HILTON ISTANBUL BOSPHORUS HOTEL  
ISTANBUL, TURKEY



### OP-09

#### **ASSESSMENT OF QUALITY OF LIFE, DEPRESSION AND ANXIETY LEVELS OF PATIENTS WITH MYCOSIS FUNGOIDES AND COMPARISON WITH HEALTHY CONTROLS**

*Burhan Engin<sup>1</sup>, Aslıhan Özge Birben<sup>1</sup>, Ayşegül Sevim Keçici<sup>2</sup>, Murat Yalçın<sup>3</sup>, Ea Camcıoğlu<sup>4</sup>, Zekayi Kutlubay<sup>1</sup>*

<sup>1</sup>Department of Dermatology and Venerology, Cerrahpaşa Medical Faculty, Istanbul, Turkey

<sup>2</sup>Department of Dermatology and Venerology, University of Medical Sciences, Haydarpaşa Numune Training and Research Hospital, İstanbul, Turkey

<sup>3</sup>Department of Psychiatry, Erenköy Ruh ve Sinir Hastalıkları Training and Research Hospital, İstanbul, Turkey

<sup>4</sup>Department of Public Health, Cerrahpaşa Medical Faculty, Istanbul, Turkey

**OBJECTIVE:** This study was designed to measure depression and anxiety levels in mycosis fungoides patients, together with the quality of life assessments and to compare the results with healthy controls.

**METHODS:** Fifty-two patients with a diagnosis of mycosis fungoides and 52 age and sex matching healthy controls were enrolled in this study. Beck Depression Inventory, Beck Anxiety Inventory and the 36-Item Short Form Health Survey were administered to all patients and healthy controls.

**RESULTS:** Mean Beck Anxiety Inventory scores of the patients with mycosis fungoides were significantly higher than healthy controls. In case of the 36-Item Short Form Health Survey, general health perception and social functioning scores were significantly lower in patient group. Depression scores of the patients' were positively correlated with the age of disease onset and negatively correlated with physical functioning scores. Significant negative correlation was detected between subscales of the 36-Item Short Form Health Survey, such as physical functioning, pain, general health perceptions, physical, emotional and social role functioning and Beck Depression Inventory and Beck Anxiety Inventory scores.

**CONCLUSION:** This study has demonstrated that there is significant impairment of quality of life in patients with mycosis fungoides, with increased levels of anxiety. As the disease progresses, level of depression increases and general health perception of the patients' deteriorates. Increased levels of anxiety and depression were associated with poorer quality of life scores. Quality of life assessments for chronic diseases such as mycosis fungoides can increase patient's cooperation during the long treatment process.

**Keywords:** Quality of Life, Depression and Anxiety Levels, Mycosis Fungoides



# 4<sup>th</sup> INDERCOS

Dermatology and Cosmetology Congress  
with International Participants  
27 - 30 MARCH, 2019  
HILTON ISTANBUL BOSPHORUS HOTEL  
ISTANBUL, TURKEY



## Sociodemographic characteristics of patients and control group

	Patient number (n)	Percentage (%)	Control group (n)	Percentage (%)	P value
Gender					1.000
female	24	46,2	24	46,2	
male	28	53,8	28	53,8	
Education					0.683
Primary school	20	38,5	16	30,8	
High school	14	26,9	17	32,7	
University	18	34,6	19	36,5	
Marital status					0.845
married	38	73,1	37	71,1	
single	10	19,2	12	23,1	
divorced	4	7,7	3	5,8	
Age	46,44±16,22		45,25±13,83		0.706

## Sociodemographic characteristics of patients and control group

## Beck depression and anxiety scores and Short form-36 subscores of patients and control group

	Patient	Control	p value
BDS	10.81±6.90	7.96±4.24	0.052
BAS	10.17±9.26	6.33±6.05	0.022
SF-36			
General health perception	55.77±17.27	80.96±18.29	0.001
Pain	77.23±25.81	80.96±18.29	0.913
Social function	69.23±23.15	79.47±18.03	0.026
Mental health	67.69±18.86	72.77±12.92	0.187
Vitality	60.00±21.05	61.25±18.12	0.822
Emotional role	68.57±39.84	75.63±36.83	0.320
Physical role	71.15±39.10	80.77±34.87	0.159
Physical function	88.85±10.27	86.35±15.34	0.744

## Beck depression and anxiety scores and Short form-36 subscores of patients and control group



# 4<sup>th</sup> INDERCOS

## Dermatology and Cosmetology Congress with International Participants

27 - 30 MARCH, 2019  
HILTON ISTANBUL BOSPHORUS HOTEL  
ISTANBUL, TURKEY



### OP-10

#### EVALUATION OF PSYCHOSOCIAL EFFECTS OF LONG-TERM GENITAL HPV INFECTION

Nermin Karaosmanoğlu<sup>1</sup>, Ali Şahan<sup>2</sup>

<sup>1</sup>Department of Dermatology, Ankara Training and Research Hospital, Ankara, Turkey

<sup>2</sup>Special Lonicera Dermatology Clinic, Ankara, Turkey

**INTRODUCTION AND OBJECTIVES:** Genital human papilloma virus (HPV) infection is a viral infection disease which occurs in humans. It is one of the most common sexually transmitted diseases. Mostly, the patients having anogenital warts feel uncomfortable and ashamed of these unattractive lesions. The aim of this study was to evaluate the psychosocial effects of long-term genital HPV infection on men, by using anxiety- depression tests and with psychological evaluation by an expert psychiatrist.

**MATERIALS-METHODS:** A total of 77 male patients with genital HPV infection longer than 3 months duration who admitted to the department of dermatology between December 2013 and May 2014 were included in the study. All of the participants were evaluated by a dermatologist and a psychiatrist, respectively. Sociodemographic information; including age, smoking, alcohol, drug use story, marital status, having one or multiple sexual partners, educational status, working status and the duration of the disease were recorded. Three validated questionnaires-Dermatological Life Quality Index (DLQI), Stait Trait Anxiety Inventory scales (STAI 1-2), Beck Depression Inventory (BDI)-were used to assess the psychological burden of the patients. After all these consideration, the patients were evaluated by an expert psychiatrist one by one and they were again tested by SCID 1-2 (Structured Clinical Interview for DSM-III-R) tests.

**RESULTS:** Of the 77 patients, all were men and the mean age was 37,68±11,67. The mean duration of the disease was 9,74±7,76 months. Fifty one of the patients (66,2 %) had more than 5 lesions. Sixty eight of them (88,3 %) had a history of taking some medications for the disease. Nine of them (11,7 %) had no treatment before. The mean score of DLQI scale was found as 4,58±4,42. The patients were mostly (26 of them, 33,8 %) classified as "small effect on patient's life", at a score of 2-5. STAI-1 mean score was 41,74±11,77. Thirty eight of the patients (49,4 %) were found to be highly anxious. According to the STAI-2 scale, the mean score was 42,69±9,71 and again most of them (40 patients, 51,9 %) was found to be highly anxious. The mean score of BDI was 16,43±11,929 and 27 of the patients (35,1 %) were found to be moderately depressive, while most of them (37 patients, 48,1 %) had a normal mood. Finally, after the evaluation of all of the patients by an expert psychiatrist and according to the results of SCID 1-2 tests; 63 patients (81,8 %) were found to have a normal mood and needed no medication, while 14 of them (18,2 %) needed psychiatric medication.

**CONCLUSIONS:** Patients suffering from genital HPV longer than 3 months are generally negatively affected psychosocially. The physician who wants to achieve success in the treatment of these patients should approach the patient with kindness, compassion and patience in a more sensitive way. And if necessary, support from an expert psychiatrist should be taken.

**Keywords:** genital warts, depression, anxiety



# 4<sup>th</sup> INDERCOS

## Dermatology and Cosmetology Congress with International Participants

27 - 30 MARCH, 2019  
HILTON ISTANBUL BOSPHORUS HOTEL  
ISTANBUL, TURKEY



### OP-11

#### COMBINED INTENSE PULSED LIGHT AND LONG-PULSED 1064-NM ND: YAG LASER FOR THE TREATMENT OF NEVUS FLAMMEUS

*Leyla Baykal Selcuk, Deniz Aksu Arica*

*Department of Dermatology, Karadeniz Technical University, Trabzon, Turkey*

**INTRODUCTION & OBJECTIVES:** The long-pulsed 1064-nm Nd: YAG lasers and Intense pulsed light (IPL) systems are used separately effectively for treating nevus flammeus. This study evaluated the efficacy and safety of these systems in combination in the treatment of nevus flammeus.

**MATERIALS & METHODS:** IPL and Nd:YAG therapies were applied in combination in twelve patients with nevus flammeus. Hypertrophic areas were first treated with Nd:YAG laser. In the subsequent sessions, the two therapeutic options were used consecutively in combination at two to four-week intervals.

**RESULTS:** Nd:YAG laser was applied at spot diameters of 3-7 mm, with a 60-140 j/cm<sup>2</sup> energy, and pulse widths of 10-40 ms. IPL was used at doses of 14-27 j/cm<sup>2</sup> in A or B mode. Treatment results were classified as 0-25% mild improvement, 25-75% moderate improvement, and over 75% excellent improvement. Following between three and nine sessions, treatment concluded with excellent improvement in five patients and moderate improvement in seven. Five patients were still receiving treatment when our study period ended. Almost complete eradication of lesions was achieved with IPL alone in another patient with nevus flammeus on the neck. No complications were observed at controls during sessions performed at two-week intervals.

**CONCLUSIONS:** Our study is the first to assess the effectiveness of combined Nd:YAG and IPL in the treatment of nevus flammeus. We think that combination therapy at two-week intervals can extend the treatment period while bestowing additional benefit with no extra risk.

**Keywords:** Nd:Yag, IPL, nevus flammeus





# 4<sup>th</sup> INDERCOS

## Dermatology and Cosmetology Congress with International Participants

27 - 30 MARCH, 2019  
HILTON ISTANBUL BOSPHORUS HOTEL  
ISTANBUL, TURKEY



### OP-13

#### **DERMATOLOGICAL SIDE EFFECTS OF TARGETED ANTINEOPLASTIC DRUGS: PROSPECTIVE STUDY**

*Şenay Ağırçöl<sup>1</sup>, Ceyda Caytemel<sup>1</sup>, Kezban Nur Pıllancı<sup>2</sup>*

*<sup>1</sup>Haseki Eğitim ve Araştırma Hastanesi, Dermatoloji Kliniği*

*<sup>2</sup>Haseki Eğitim ve Araştırma Hastanesi, Onkoloji bölümü*

**INTRODUCTION:** Epidermal growth factor inhibitors (EGFR) have dermatological side effects, especially papulopustular lesions, are observed. Managing the diagnosis and treatment process in these side effects can make a significant contribution to the continuation of chemotherapy and the maintenance of quality of life. The aim of this study was to determine the cutaneous side effects of EGFR inhibitors and to share treatment management.

**MATERIALS AND METHODS:** 59 patients who underwent EGFR in the oncology unit of our hospital were evaluated. Patients who underwent EGFR in the prospectively planned study were examined at the beginning of the treatment, at the 2nd and 4th weeks. The study was conducted between February 2016 and February 2018 and was approved by the local ethics committee. Papulopustular side effects and other dermatological findings were recorded. Grading and treatment plans of acneiform side effects were reported.

**RESULTS:** Acneiform side effects were seen in 22 of 47 female and 12 male patients using EGFR inhibitor. 45 patients had early stage and 14 patients had advanced stage carcinoma. Sixteen patients had colorectal carcinoma, 1 patient had renal disease and 42 patients had breast cancer. Trastuzumab was the most commonly used drug group in 29 patients with a single drug and in 13 patients. All patients, except for one patient who used trastuzumab, had facial and upper body and back lesions. Xerosis, paronychia, pyogenic granuloma, trichomegaly and madarosis were rare. Patients with acneiform rash were treated with topical and systemic antibiotics, mild keratolytics and emollients. All patients were able to complete the chemotherapy process.

**CONCLUSION:** Dermatologists need to know the specific eruptions occurring with chemotherapy drugs, especially EGFR inhibitors in order to develop the best approach without discontinuation of cancer therapy

**Keywords:** Epidermal growth factor receptor inhibitors, targeted chemotherapy, acneiform eruption, skin toxicity



# 4<sup>th</sup> INDERCOS

## Dermatology and Cosmetology Congress with International Participants

27 - 30 MARCH, 2019  
HILTON ISTANBUL BOSPHORUS HOTEL  
ISTANBUL, TURKEY



### OP-14

#### HOW I USE SPORT PRODUCTS IN DERMATOLOGIC SURGERY

*Patricia Liana Cristodor, Justin Hancu, Laurentiu Ilinca, Iasmina Maria Hancu*

*Department of Dermatology, "Victor Babes" University of Medicine and Pharmacy, Timisoara, Romania*

**INTRODUCTION & OBJECTIVES:** When closed under tension, surgical wounds are likely to heal with hypertrophic or keloid scars and – if the surgical act involves the lower eyelid, with permanent ectropion. We assumed that kinesiologic tapes would be appropriate for relieving the tension on such surgical wounds and thus improve the aspect of the scars and prevent or reverse (at least partially) the ectropion.

**MATERIALS&METHODS:** We used kinesiologic tapes in case of postoperative scars and ectropion, as it follows:

A. In a lot of 35 patients, aged from 29 to 70, 21 males and 24 females, with recent post excisional scars we applied kinesiologic tapes perpendicularly to the scars. We gave the tapes the maximal extension in the middle half, but left the ends without any tension. We changed the tapes weekly for six months, while also observing the aspect of the scars.

B. In a 2nd lot of 2 patients, both females (aged 48 and 60) with low grade post operative ectropion we applied the tapes from the temple to the front on the healthy skin as described above, with the maximal extension in the middle of the tapes. We used the traction exerted by the tapes in order to lift the lower lid and mechanically correct the ectropion.

**RESULTS:** A. The evolution of the post excisional scars was very good. None of them became hypertrophic or keloid and all of them were thin, linear and soft. Only two patients developed a mild form of contact dermatitis which healed with topical steroids. In these two patients, we discontinued the procedure.

B. The ectropion group achieved complete correction of the ectropion in only several weeks, without any incident.

**DISCUSSION:** The kinesiologic tapes have some unique properties which recommend them for the prevention of the defects due to inappropriate tension or traction on the post excisional skin – either on the wound margins or on the lower eyelid. They have long lasting, good adherence to the skin and also allow for daily hygiene (such as showering or bathing). They are elastic, soft, hypoallergenic and are quite inexpensive. We have empirically estimated the duration of treatment to 6 months, having in view that by that time the scar reaches about 70-80% of its final aspect, but further studies might find a shorter period of time just as efficient. To our surprise and satisfaction, in our patients with ectropion a stable result was achieved quite rapidly (2-3 weeks).

As a mechanism for these good results we suggest the reorientation and stabilisation of the dermal fibers, resulting in a permanent correction of the defects.

**CONCLUSIONS:** Our study brings a novel use to the kinesiological tapes and introduces them in the dermatological, surgical and aesthetical fields of medicine. As many patients are greatly concerned by the aspect of their post operative scars, with this simple and inexpensive strategy we may significantly improve their satisfaction – and ours, as well.

**Keywords:** post excisional scars, ectropion, kinesiologic tapes



# 4<sup>th</sup> INDERCOS

## Dermatology and Cosmetology Congress with International Participants

27 - 30 MARCH, 2019  
HILTON ISTANBUL BOSPHORUS HOTEL  
ISTANBUL, TURKEY



### OP-15

#### COMPARING THE EFFICACY OF METRONIDAZOLE 1% GEL VERSUS LOW-DOSE ORAL ISOTRETINOIN IN THE TREATMENT OF MODERATE TO SEVERE SEBORRHEIC DERMATITIS

*Mohamad Goldust*

*Department of Dermatology, Mazandaran University of Medical Sciences, Sari, Iran*

**BACKGROUND:** Alternative treatments for seborrhoeic dermatitis (SD) are needed because of the increasing risk of anti-fungal resistance to existing therapies. This study aimed at comparing the efficacy of metronidazole 1% gel vs. low-dose oral isotretinoin in the treatment of moderate to severe seborrheic dermatitis.

**METHODS:** In this clinical trial study, 118 patients suffering from moderate to severe SD were studied. The patients were randomly divided into two groups. First group received topical metronidazole 1% gel twice a day for four weeks. In other group, 59 patients were treated with isotretinoin 10 mg every other day. At the beginning and also 2 and 4 weeks after first visit, the patients were examined to control improvement of clinical symptoms. Patient opinion, investigator assessment, scalp pruritus, sebum production, and quality of life (QoL) comprised the efficacy outcomes.

**RESULTS:** The highest level of satisfaction (86.4%) was observed 28 days after isotretinoin consumption since it was 76.2% in metronidazole group. The rate of sebum production significantly decreased in isotretinoin group. Patients' opinion, investigator, and QoL assessments improved in both groups. There were no adverse events related to treatment for either group.

**CONCLUSION:** Either group had a beneficial effect on the clinical condition of the skin of the patients. The results of this study support the efficacy and safety of low-dose oral isotretinoin for the treatment of moderate to severe seborrheic dermatitis.

**Keywords:** Metronidazole 1% gel, Low-dose oral isotretinoin, Seborrheic dermatitis



# 4<sup>th</sup> INDERCOS

## Dermatology and Cosmetology Congress with International Participants

27 - 30 MARCH, 2019  
HILTON ISTANBUL BOSPHORUS HOTEL  
ISTANBUL, TURKEY



### OP-16

#### DERMATOFIBROSARCOMA PROTUBERANS: CLINICAL AND HISTOPATHOLOGICAL FEATURES OF 9 CASES

*Asude Kara Polat<sup>1</sup>, Elif Bal Avcı<sup>1</sup>, Vildan Manav<sup>1</sup>, Mehmet Salih Gürel<sup>2</sup>, Ayşe Esra Koku Aksu<sup>1</sup>, Cem Leblebici<sup>3</sup>*

<sup>1</sup>Department of Dermatology, Health Science University Istanbul Training and Research Hospital, Istanbul, Turkey

<sup>2</sup>Department of Dermatology, Medeniyet University Göztepe Training and Research Hospital, Istanbul, Turkey

<sup>3</sup>Department of Pathology, Health Science University Istanbul Training and Research Hospital, Istanbul, Turkey

**INTRODUCTION:** Dermatofibrosarcoma protuberans (DFSP) is a rare soft tissue tumor in young and middle age adults. It presents as asymptomatic skin-colored nodules and plaques but subcutaneous tissue, muscle and fascia may be invaded. Surgical excision is the first line treatment. In our study, clinical, demographic and histopathological features of patients with DFSP were evaluated.

**MATERIALS-METHODS:** The records of nine patients with clinical and histopathological diagnosis of DFSP who were admitted to the Dermatology Clinic of Istanbul Training and Research Hospital between August 2013 and September 2018 were evaluated retrospectively.

**RESULTS:** The mean age of the patients was  $38.7 \pm 12.1$  years. 66.6% of those lesions were located in trunk, 22.2% were located in the upper extremity and 1 (11.1%) was in the neck. Most of the lesions were in plaque and tumor form. Only one case with DFSP had sternocleidomastoid (SCM) muscle invasion. Histopathological examination revealed tumoral cell infiltration in the dermis and subcutaneous adipose tissue, and tumoral cells showing a short bundle of collagen stroma. CD34 (+) was observed in all of the cases in immunohistochemical examination and FXIII was focal positive in 28.5% of stained case specimens. All patients underwent surgical excision; however, RT was applied as a combined treatment option in 2 patients. The mean follow-up period was 29 months (3-63 months) and none of the patients had recurrence and metastasis during the five-year follow-up period.

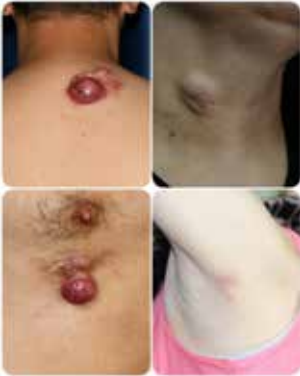**DISCUSSION:** DFSP is usually characterized by pink-purple dermal nodules and plaques and were often encountered in the trunk and extremities, followed by head and neck. In 10% of DFSP has been reported to arise in areas with history of prior trauma, vaccination, burn, surgical scars, however, 33.3% of our cases had a history of trauma. FXIII, which was used to differentiate dermatofibroma and dermatofibrosarcoma, was negative in 33.3% of cases. All patients underwent surgical excision because CD34 immunohistochemical staining provided definitive diagnosis in patients with spindle cell tumors arranged in a storiform pattern.

**CONCLUSION:** Regardless of the size of the lesion in DFSP; it should be kept in mind that there may be muscle invasion, and should be monitored with a multidisciplinary approach.

**Keywords:** Dermatofibrosarcoma protuberans, histopathology, CD34, soft tissue sarcoma



**Figure 1. Clinical photographs of patients with DFSP**



**Demographic, clinical and histopathological features of patients with DFSP**

Case number	Age	Gender	Duration (year)	Localisation	Lesion features	Lesion size (cm)	CD34	F XIII	Treatment
1	36	M	1	Trunk	nodule+tumour	6x6	positive	*	Surgery
2	19	M	0,1	Trunk	tumour	6x8	positive	focal positive	Surgery
3	41	F	2	Neck	tumour	2x2,5	positive	focal positive	Surgery+RT
4	25	F	5	Upper extremity	plaque	2x3	positive	positive	Surgery
5	36	M	7	Trunk	nodule	2x2	positive	negative	Surgery
6	39	M	10	Trunk	nodule+tumour	3x5	positive	*	Surgery
7	43	F	10	Trunk	tumour	10x10	positive	negative	Surgery
8	59	F	7	Trunk	plaque	5x4	positive	weak	Surgery
9	51	M	1	Upper extremity	plaque	5x5	positive	negative	Surgery+RT

\*No FXIII staining F: female, M: male, RT: radiotherapy



# 4<sup>th</sup> INDERCOS

## Dermatology and Cosmetology Congress with International Participants

27 - 30 MARCH, 2019  
HILTON ISTANBUL BOSPHORUS HOTEL  
ISTANBUL, TURKEY



### OP-17

#### LONG-TERM EFFICACY AND SAFETY OF INFLIXIMAB FOR PSORIASIS: TWELVE-YEAR EXPERIENCE IN A SINGLE TERTIARY CENTER

Goncağül Babuna Kobaner, *Armağan Kutlay*

Department of Dermatology, Istanbul University Medical Faculty, Istanbul, Turkey

**INTRODUCTION & OBJECTIVES:** Infliximab (IFX), a chimeric anti-tumor necrosis factor-alpha monoclonal antibody, is widely used to treat psoriasis. We aimed to evaluate the long-term efficacy and safety of IFX therapy in a large group of patients with moderate-to-severe psoriasis.

**MATERIALS & METHODS:** Between 2006 and 2018, a total of 72 patients were treated with IFX in our clinic. Among them, the data of 65 patients who received IFX for  $\geq 3$  months, was retrospectively evaluated regarding the efficacy, adverse events and reasons for discontinuation of therapy.

**RESULTS:** Infliximab induced a reduction of mean Psoriasis Area Severity Index (PASI) by 90.25% at week 12 and 84.14% at year one (50 patients completed one year of treatment). Mean duration of IFX therapy was 42.4 months (3-142 months). Among 19 patients (29.2%) who received IFX for  $>5$  years, mean PASI was 0.44 at year five. Infliximab was discontinued in 51 patients, mainly due to loss of efficacy (n=18), followed by adverse events (n=10) and patient preference (n=9). Adverse events including upper respiratory tract infections (n=19), infusion reactions (n=13) and urinary tract infections (n=13) were observed in a total of 45 patients. Ten (15.4%) experienced severe adverse events that led to drug cessation, most common being severe infusion reactions (n=6), followed by severe infections (pulmonary tuberculosis n=1, viral hepatitis n=1 and other infections n=2).

**CONCLUSIONS:** Although loss of efficacy was the major cause of drug cessation, in nearly 1/3 of our patients, a sustained efficacy with complete or near-complete clearance was achieved with the long-term treatment of IFX. Infections and infusion reactions were the main safety considerations. All severe infusion reactions were seen within the first year of the therapy, suggesting necessity for high vigilance during this period.

**Keywords:** infliximab, anti-TNF, TNF-alpha inhibitor, long-term treatment



# 4<sup>th</sup> INDERCOS

## Dermatology and Cosmetology Congress with International Participants

27 - 30 MARCH, 2019  
HILTON ISTANBUL BOSPHORUS HOTEL  
ISTANBUL, TURKEY



### OP-18

#### IMAGE RECORDING WITH HANDHELD DERMATOSCOPE WITHOUT ADAPTER AND IMPROVING THE QUALITY OF RECORDED IMAGE BY MOBILE PHOTO EDITOR APPLICATION

Erhan Ayhan<sup>1</sup>, Serdar Ferit Toprak<sup>2</sup>

<sup>1</sup>University of Health Sciences Gazi Yaşargil Training and Research Hospital, Department of Dermatology, Diyarbakir, Turkey

<sup>2</sup>University of Health Sciences Gazi Yaşargil Training and Research Hospital, Department of Otorhinolaryngology, Diyarbakir, Turkey

Dermatoscopy allows in vivo examination of pigmented lesions, especially by using light and enlargement systems. In handheld dermatoscopes, the lesions are examined at 10-20X magnification. However, most dermatologists do not have an adapter to record lesions due to technical and financial difficulties. Even with handheld dermatoscopes and computerized digital dermatoscopes with adapter, problems such as recording of the image and uncertainty of the structures of the lesion may occur. Vascular structures seen in dermatoscopy can help diagnose many skin diseases (1). However, vascular structures may not be clearly visible in both digital and handheld dermatoscopes depending on the pressure. The mobile phone camera (Samsung Note 8, 12 megapixel rear camera) is placed on the focus ring on the handheld dermatoscope (Heine Delta 20 Dermoscope; Heineoptotechnik, Herrsching, Germany). The image is then magnified 2x before recording. The recorded image is transferred to the photo editor to improve the resulting image quality (Fig. 1). With the other structures in the picture, adjustments are made on backlight, tone curve, color, luminance, brightness, contrast, saturation and white balance, especially in order to clarify vascular structures and make structures easier to distinguish from each other (Fig.2). Two versions of photos were performed to clarify the vessels. In the first version, the backlight was turned to 100, tone curve to S shaped. Red saturation is increased and luminance is reduced. In version 2, the backlight is set to 100; the brightness was reduced. The exposure and contrast were increased and white balance was set to 6500k. With this method, images with handheld dermatoscopy without adapter are recorded. In addition, it can be seen that the image quality of the pictures can be corrected with the mobile phones that we use frequently in our daily lives. However, it is thought that picture quality can be improved by using photo editor applications before publication of manuscripts related to dermatoscopes.

**Keywords:** dermoscopy, without adaptor dermoscopy, photo editor application, mobil phone, quality of images, improvement of image.

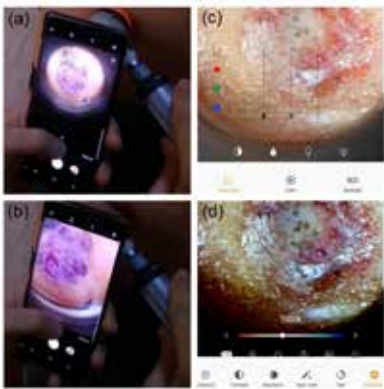


# 4<sup>th</sup> INDERCOS

Dermatology and Cosmetology Congress  
with International Participants  
27 - 30 MARCH, 2019  
HILTON ISTANBUL BOSPHORUS HOTEL  
ISTANBUL, TURKEY

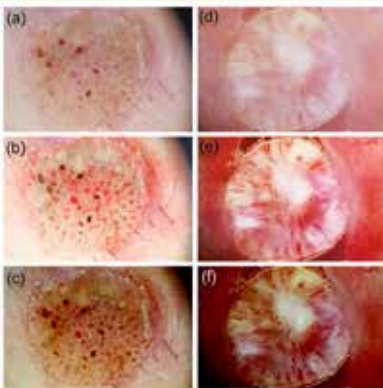

**Figure 1**



*Image of handheld dermatoscope placed on focus ring [a(x1 zoom), b (x2 zoom)], images from the photo editor application (c, d)*

**Figure 2**



*Original (a), edited version 1 (b) and edited version 2 (c) images of inverted follicular keratosis, original (d), edited version 1 (e) and edited version 2 (f) images of mucosal mucocele.*





# 4<sup>th</sup> INDERCOS

## Dermatology and Cosmetology Congress with International Participants

27 - 30 MARCH, 2019  
HILTON ISTANBUL BOSPHORUS HOTEL  
ISTANBUL, TURKEY



### OP-19

#### **THE EFFICACY OF ADDING LOW-LEVEL LIGHT THERAPY TO MINOXIDIL 5% SOLUTION IN THE TREATMENT OF ANDROGENETIC ALOPECIA**

*Mohamad Goldust*

*Department of Dermatology, Mazandaran University of Medical Sciences, Sari, Iran*

**INTRODUCTION:** Androgenetic alopecia (AGA) is the most common form of hair loss in men and in women. Currently, minoxidil and finasteride are the treatments with the highest levels of medical evidence. Over the past several years, there has been great interest in the potential role of laser/light-based treatments for male and female pattern hair loss. The aim of this study was to evaluate adding low-level light therapy (LLLT) to minoxidil topical solution in the treatment of AGA.

**METHODS:** In this clinical trial study, 56 patients with androgenetic alopecia were evaluated. All participants were randomly assigned into two groups. The first group received the investigational LLLT, and the other group received LLLT plus topical minoxidil 5% solution twice per day. LLLT was used 3 times weekly for 30 minutes each, over a 24-week period. Global scalp photography, phototrichogram assessment, the investigator's global assessment (IGA) of hair regrowth, and the subject's assessment of the treatment satisfaction were used for evaluation.

**RESULTS:** The efficacy and safety of both modalities were highlighted with comparable results in all parameters. The percentage of recovery from androgenetic alopecia and the patients' satisfaction with their treatment were significantly higher in the second group compared to the first group. A significantly greater improvement from baseline in hair thickness, hair count, hair coverage, and IGA were also observed in second group at the 12- and 24-week visits. No serious adverse events were observed.

**CONCLUSION:** LLLT represents a potentially effective treatment for both male and female AGA, either as monotherapy or concomitant therapy. Combination treatments with minoxidil, and LLLT may act synergistic to enhance efficacy.

**Keywords:** Low-level light therapy, Minoxidil 5% solution, Androgenetic alopecia



# 4<sup>th</sup> INDERCOS

## Dermatology and Cosmetology Congress with International Participants

27 - 30 MARCH, 2019  
HILTON ISTANBUL BOSPHORUS HOTEL  
ISTANBUL, TURKEY



### OP-20

#### **TREATMENT OF ANGIOKERATOMA OF FORDYCE WITH LONG-PULSE NEODYMIUM-DOPED YTTRIUM ALUMINIUM GARNET LASER**

*Neslihan Fişek İzci, Zehra Aşiran Serdar, Berna Aksoy, Ezgi Aktaş Karabay, Aslı Tatlıparmak  
Department Of Dermatology, Bahçeşehir University, Istanbul, Turkey*

Angiokeratomas are benign vascular tumors with keratotic elements. Angiokeratomas are dark violaceous to black, often keratotic papules or small plaques that are hard upon palpation. There are 5 clinical manifestations of angiokeratoma: 1) Solitary angiokeratoma 2) Angiokeratoma of Mibelli 3) Angiokeratoma of Fordyce 4) Angiokeratoma circumscriptum 5) Angiokeratoma corporis diffusum. Angiokeratoma of Fordyce is the most common variant. The lesions are multiple papules ( $\leq 4$  mm) that are dark red in color and present in quite large numbers. Angiokeratoma of Fordyce can be easily diagnosed by their typical erythra and cured by varied therapeutic methods including surgery, electrocoagulation, cryotherapy, or various laser systems. Herein, we present three female patients have angiokeratomas of Fordyce treated with Nd:YAG laser. The patients received two laser treatment sessions with an interval of 4 weeks. All of the patient's lesions resolved completely after two treatment sessions. We suggest that a long-pulsed Nd:YAG laser is a safe and effective method for the treatment of angiokeratoma of Fordyce.

**Keywords:** angiokeratoma of Fordyce, vulva, Nd:YAG laser



# 4<sup>th</sup> INDERCOs

## Dermatology and Cosmetology Congress with International Participants

27 - 30 MARCH, 2019  
HILTON ISTANBUL BOSPHORUS HOTEL  
ISTANBUL, TURKEY



### OP-21

#### CLINICAL AND DEMOGRAPHIC CHARACTERISTICS OF PEDIATRIC MORPHEA: A STUDY OF 37 CASES

Ayşe Akbaş, Sertac Sener

Ankara Atatürk Training and Research Hospital Department of Dermatology

**INTRODUCTION & OBJECTIVES:** Localized scleroderma, known as morphea is a rare skin disease which causes sclerosis in the dermis and subcutaneous tissue. It's pathogenesis is unknown. There are only a few retrospective studies about pediatric morphea with very limited data. In this study, we aimed to review the clinical and demographic characteristics of patients with morphea under the age of 18.

**MATERIAL-METHODS:** The files of patients who had been diagnosed morphea clinically and histopathologically in our outpatient clinic between 2012-2018 were reviewed. The patients who were younger than 18 years old at the time of the diagnosis were enrolled. Demographic and clinical characteristics, laboratory findings as well as the treatments were analysed retrospectively.

**RESULTS:** There were eight male and 29 female pediatric morphea patients. The mean age was 12.1 years and the mean onset age for the disease was 7.0 years. The mean duration until the time of diagnosis was 3.6 years.

The most common site of anatomic involvement was the body (40%). The most common morphea type was plaque type with 59,4% (n=22); followed by linear type with 21.6% (n=8) and generalize type with 10.8 % (n=4) and mix type with 8.1% (n=3). We did not have deep and pansclerotic type. Twelve patients had antinuclear antibody (ANA) positivity (32%). AntidsDNA antibodies were found higher in two cases and rheumatoid factor was positive in other two. There was iron deficiency in 6 patients (16%) and vitamine B12 deficiency in five (13%).

Ten patients were treated with topical corticosteroid and calcipotriol. Colchicine was used in 10 cases, methotrexate in five cases, systemic steroid in four cases, hydroxyclozolin in two cases and isotretinoin in one case. In two cases narrowband UVB and in one case UVA were administered. Orthopedic complications in the legs occurred in two linear morphea patients.

**CONCLUSION:** Pediatric morphea is a rare disease with an unknown etiology. Most of our findings were consistent with present literature. However, our study showed plaque type morphea was the most frequent form of the disease on the contrary to previous data which presented linear morphea as the most common type. Orthopedic complications rarely occur. Diagnosis and management of the disease is important to avoid complications.

**Keywords:** pediatric morphea, localized scleroderma, linear morphea



# 4<sup>th</sup> INDERCOS

## Dermatology and Cosmetology Congress with International Participants

27 - 30 MARCH, 2019  
HILTON ISTANBUL BOSPHORUS HOTEL  
ISTANBUL, TURKEY



### OP-22

#### LEUKOCYTOCLASTIC VASCULITIS: A RETROSPECTIVE ANALYSIS OF 57 PATIENTS

*Nermin Karaosmanoğlu<sup>1</sup>, Engin Karaaslan<sup>2</sup>*

<sup>1</sup>*Department of Dermatology, Ankara Training and Research Hospital, Ankara, Turkey*

<sup>2</sup>*Department of Dermatology, Nusaybin Government Hospital, Mardin, Turkey*

**INTRODUCTION AND OBJECTIVES:** Leukocytoclastic vasculitis is an inflammatory disease of the small vessels and it usually presents with skin and joint findings. The aim of this study was to analyse the clinical and demographical characteristics of the patients diagnosed as leukocytoclastic vasculitis in the dermatology department.

**MATERIALS-METHODS:** Patients who were diagnosed as leukocytoclastic vasculitis in the dermatology department between 2013-2017 were included in the study. The demographic characteristics, localization and type of cutaneous lesions, etiology, symptoms, presence of extracutaneous symptoms, histopathological evaluation and treatment options were retrospectively detected.

**RESULTS:** Of the 57 patients, 39 (68,4 %) were women and 18 (31,6 %) were men. The median age was 55 (14-86). The median duration of the lesions was 14 (2-120) days. The most frequent localisation of the lesions was the lower extremities (38,6 %, n=22). The lesions were presented mostly as palpable papules or plaques (36,8 %, n=21) followed by purpuric macules or patches (31,6 %, n=18). Most of the patients (45,6 %) were asymptomatic, and pruritus (17,5 %) was the most frequent complaint. Arthralgia (21,1 %, n=12) was the most frequent extracutaneous finding. The lesions were usually found to be idiopathic (43,9 %, n=25), while the most detectable etiological factor was having an infection and drug use together (21,1 %, n=12). Systemic antihistaminics were the most frequently used therapy of choice (19,3 %, n=11).

**CONCLUSIONS:** Leukocytoclastic vasculitis is a benign and self limited disease. It is frequently triggered by drugs or infections. Palpable papules or plaques localized in the lower extremity is the most frequent clinical form. It is important to detect the etiological factor in order to apply the optimal treatment choice. Systemic antihistaminics, topical steroids or systemic steroids are the most preferred and effective treatment options.

**Keywords:** leukocytoclastic vasculitis, etiology, cutaneous findings, systemic findings, treatment, prognosis





# 4<sup>th</sup> INDERCOS

## Dermatology and Cosmetology Congress with International Participants

27 - 30 MARCH, 2019  
HILTON ISTANBUL BOSPHORUS HOTEL  
ISTANBUL, TURKEY



### OP-23

#### **ACCURACY RATES OF INITIAL DIAGNOSIS OF ELEVEN PATIENTS WITH MILKER'S NODULE AFTER RELIGIOUS SACRIFICE FEAST**

*Ecem Zeliha Ergün, Ayşe Esra Koku Aksu, Mehmet Salih Gürel*

*Department of Dermatology, Health Science University Istanbul Training and Research Hospital, Istanbul, Turkey*

**INTRODUCTION:** Milker's nodule is a zoonotic infection caused by parapox virus. Incubation period ranges from 3 to 7 days. It is a rare benign viral infection with six different stages, regresses in six weeks without specific treatment.

**OBJECTIVE:** It is aimed to investigate clinical features, complications and accuracy rates of initial diagnosis of the patients with milker's nodule.

**MATERIALS-METHODS:** 11 patients with milker's nodule were examined according to gender, age, number and location of lesions, the time period after the appearance of the lesions, incubation period, initial diagnosis and complications. The patients were diagnosed along with history and clinical course. Every stage of the disease was photographed.

**RESULTS:** All of the patients were from Istanbul/Turkey. All had a history of direct contact with cattles during the 'Feast of Sacrifice'. 11 patients with 23 lesions were included in the study. 72%(8) of patients were women. Average age of the patients was 40.09, ranged from 14 to 66. The mean incubation period was 4.9 days(Range 1-10 days). The number of the lesions was 1-8. Lesions were localized on the hands in eight patients, the forearm in the two patients and the foot in one patient. The mean time after the appearance of the lesion was 8.5 days(Range 3-15 days).

Four patients were initially misdiagnosed as anthrax and overtreated by specialist of Infectious Disease. Two of them were hospitalized. One was misdiagnosed as abscess by general practitioner. Another one was also misdiagnosed as abscess and incised for drainage by Orthopaedic surgeon. Lymphangitis developed in two patients.

Supportive treatment was applied and all of the lesions healed without scarring.

**CONCLUSIONS:** It is important to note that the lesion could be seen just one day after contact. Also physicians other than dermatologists should be aware of the disease to avoid overtreatment and unnecessary hospitalization.

**Keywords:** Milkers nodule, sacrifice feast, parapoxvirus



# 4<sup>th</sup> INDERCOS

## Dermatology and Cosmetology Congress with International Participants

27 - 30 MARCH, 2019  
HILTON ISTANBUL BOSPHORUS HOTEL  
ISTANBUL, TURKEY



### OP-24

#### A BRIEF REPORT ABOUT TREATMENT COMPLIANCE IN PATIENTS WITH PSORIASIS ACCORDING TO THREE-YEAR DATA OF PSORTAKSIS

*Kemal Özyurt, Ragıp Ertay, Muhammed Reşat Akkuş, Fatmanur Kutlu, Mustafa Atasoy  
Clinic of Dermatology, Education and Research City Hospital, Kayseri, Turkey*

Psoriasis is a common skin disease with many comorbidities and numerous treatment alternatives. Patient registries are convenient to record and analyze data of patients with certain diseases, in a "real-world" setting. Great number of patients can be monitored in registries, which permit for increased generalizability of results to clinical practice. More importantly, these registries consist safety data (serious side effects, etc.) for drug therapies, such as biologic agents. PSORTAKSIS (PSORTAKSIS, abbreviation of "Psoriasis Takip Sistemi" in Turkish), a psoriasis registry, is used for follow-up of patients in Kayseri City Hospital Dermatology Clinic since 2016. PSORTAKSIS consists demographic data, clinical findings, laboratory output, and treatment information of patients. Here, three-year data of PSORTAKSIS will be presented. PSORTAKSIS included 1137 patients with psoriasis, 454 of them had actual medical data no later than 6 months in registry system. Number of patients who were under the treatment with biologic agents were 112, 94 acitretin, 87 methotrexate, 8 ciclosporin and 153 topical agents. Six hundred and eighty-three patients discharged PSORTAKSIS and were without any medical data earlier than 6 months. Twenty-four of 683 patients had biological agent therapy as last treatment, 97 acitretin, 69 methotrexate, 24 ciclosporin and 469 topical agents. Fourteen of 24 patients had adalimumab as the last therapy, who discharged PSORTAKSIS while under the treatment of biological agents, 7 ustekinumab and 3 etanercept. There is a need for further studies investigating the compliance of patients with patient registration systems and treatments.

**Keywords:** psoriasis, patient registry, systemic treatments, biologic treatments



# 4<sup>th</sup> INDERCOS

## Dermatology and Cosmetology Congress with International Participants

27 - 30 MARCH, 2019  
HILTON ISTANBUL BOSPHORUS HOTEL  
ISTANBUL, TURKEY



### OP-25

#### **INVESTIGATION OF LATENT TUBERCULOSIS INFECTION BEFORE TNF INHIBITORS TREATMENT IN PATIENTS WITH PSORIASIS: SIGNIFICANCE OF CLINICAL PROPERTIES, QUANTIFERON-TB GOLD IN-TUBE TEST AND TUBERCULIN SKIN TEST**

*Kemal Özyurt, Ragıp Ertuş, Huzeife Kulu, Sinem Soğancıođlu, Mustafa Atasoy  
Clinic of Dermatology, Education and Research City Hospital, Kayseri, Turkey*

Recently, tumor necrosis factor (TNF) inhibitors have been widely used in the treatment of psoriasis. The significant role of TNF- $\alpha$  in defense to mycobacterial infection in humans is evident. Consequently, reactivation of latent tuberculosis (LTB) and development of active tuberculosis have been reported in patients with psoriasis during treatment with TNF inhibitors. Screening patients before and during therapy is critical. Tools for this purpose are; detailed personal and family anamnesis for tuberculosis (travels, BCG vaccination, etc.), chest graphs, Tuberculin skin test (TST) and QuantiFERON-TB Gold In-Tube test (QFR). In 2016, Turkish Guidelines for the Management of Psoriasis with Biologic Agents was published. Here, detailed scientific data of 180 patients will be presented for screening LTB before treatment with TNF inhibitors, other systemic biologic agents. Demographic features, risk factors about LTB, symptoms suggestive of active TB, BCG vaccination status, TST and/or QFR results of patients will be included.

**Keywords:** anti-tnf treatment, latent tuberculosis infection, tuberculin skin test, quantiferon tuberculosis gold test



# 4<sup>th</sup> Indercos

## Dermatology and Cosmetology Congress with International Participants

27 - 30 MARCH, 2019  
HILTON ISTANBUL BOSPHORUS HOTEL  
ISTANBUL, TURKEY



### OP-26

#### **ONCHOSCOPY IN THE DIAGNOSIS OF THE DISTAL SUBUNGUAL ONYCHOMYCOSIS AND TRAUMATIC ONYCHOLYSIS**

Ömer Faruk Elmas<sup>1</sup>, Handan Bilen<sup>2</sup>

<sup>1</sup>Department of Dermatology, Ahi Evran University, Kırşehir, Turkey

<sup>2</sup>Department of Dermatology, Atatürk University, Erzurum, Turkey

**AIM:** Distal subungual onychomycosis is a common public health problem which composes a large part of nail diseases. The exact diagnosis of the disease is often unfeasible without mycological investigations. In this study, we aimed to reveal sensitivity and specificity of previously described onychoscopic (nail dermoscopic) features that support and facilitate diagnosis of distal subungual onychomycosis.

**MATERIAL-METHODS:** Big toe nail of 53 patients who present with distal onycholysis were examined by digital dermatoscopy and were photographed. Specific dermatoscopic features were recorded. Mycological investigations were performed in all patients and dermatoscopic diagnosis was compared with mycological diagnosis. Three patients were excluded from the study whose final diagnoses were psoriasis.

**RESULTS:** Two specific findings previously described as longitudinal stria and spike were obtained as a result of examination of the dermatoscopic imaging. Sensitivity and specificity of longitudinal stria sign was found as 75.7% and 88.2% respectively. Sensitivity and specificity of spike sign was found as 57.5% and 94.1% respectively. And finally sensitivity and specificity of the presence of at least one of the two signs was found as 96,9% and 88,2%, respectively.

**CONCLUSION:** Dermoscopic examination is very useful and cost-effective method in diagnosis of the distal subungual onychomycosis

**Keywords:** Dermatoscopy, Onychomycosis, Traumatic Onycholysis





# 4<sup>th</sup> INDERCOS

## Dermatology and Cosmetology Congress with International Participants

27 - 30 MARCH, 2019  
HILTON ISTANBUL BOSPHORUS HOTEL  
ISTANBUL, TURKEY



### OP-27

#### **THE ROLE OF BORRELIA BURGdorFERI IN THE ETIOLOGY OF LOCALIZED SCLERODERMA (MORPHEA)**

*Baran Cayhan, Filiz Topalođlu Demir, Zafer Tırkođlu*

*Department of Dermatology, S.B.Ü. Haseki Training and Research Hospital, Istanbul, Turkey*

**BACKGROUND:** Localized scleroderma (morphea); It's a disease that leads to sclerosis of the dermis and subcutaneous tissue. In the etiology of the disease; Although microorganisms, genetic and neurological factors are considered, why not be fully revealed. We aimed to investigate the data of patients with morphea diagnosed in our clinic to determine the role of *Borrelia Burgdorferi* in the development of Morphea.

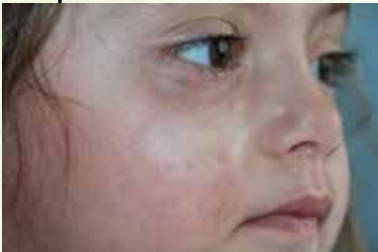**METHODS:** Between 2014 and 2018, a total of 39 patients (29 female and 10 male) with clinical and histopathological diagnosis of morphea were enrolled in the dermatology clinic of Haseki Training and Research Hospital. The data of the patients were analyzed retrospectively and age, sex, lesion localization, tick contact history, with ELISA method *Borrelia* IgM and IgG antibody positivity were evaluated.

**RESULTS:** The mean age of the 39 patients was  $40.9 \pm 23.0$  years. When the data of the patients were examined, it was found that 35.9% of the patients had a history of contact with tick. As a result of the ELISA method, 25.6% *Borrelia Burgdorferi* IgM positivity and 10.3% IgG positivity were detected in the cases. In order to examine the distribution of lesions in the body, the whole body was divided into four regions: head and neck, trunk, lower extremity and upper extremity. All of the lesions of 11 morphea patients with positive *Borrelia* spp antibodies were limited to a single site, whereas in 28 patients with *Borrelia* spp antibodies negative, 16 (57%) had single site involvement and 12 (43%) had more than one region involvement. The difference between the data obtained from patients with positive and negative *Borrelia* spp antibodies was statistically significant ( $p = 0.01$ ).

**CONCLUSION:** *Borrelia* antibody positivity in 28.9% of the cases with morphology and 35.9% of the cases with tick in Morfea revealed that *Borrelia* spp may be one of the factors considered in the etiology of the disease. In addition, there was a statistically significant difference between the *Borrelia* spp antibodies positive and negative groups in terms of multiple site involvement.

**Keywords:** borrelia, tick, morphea, localized scleroderma

#### **a morphea lesion in the face**





# 4<sup>th</sup> INDERCOS

Dermatology and Cosmetology Congress  
with International Participants  
27 - 30 MARCH, 2019  
HILTON ISTANBUL BOSPHORUS HOTEL  
ISTANBUL, TURKEY



**Table 2.**

	Borrelia Burgdorferi antibody positivity	Seropositive patient / Total patient
Aberer et al. (1987)	%53,3	8/15
Svecova and Buchvald (2000)	%34,3	11/32
Breier et al. (1996)	%33,3	13/39
Buechner et al. (1995)	%28,9	13/45
Wojas-Pelc et al. (2002)	%28,0	14/50
Zinchuk et al. (2016)	%18,8	6/32
Tolkki et al. (2018)	%11,4	4/35
Muhlemann et al. (1986)	%27,1	6/22
Wienecke et al. (1995)	%22,2	4/18
Aberer et al. (1991)	%46,6	14/30
Aberer and Stanek (1987)	%53,8	7/13

*Antibody data obtained by ELISA method of morphea patients in the literature*

**Table 3.**

	Single site involvement	Multiple site involvement	Total number of patients	Single site involvement rate
Borrelia antibody (+) patients	11	0	11	%100
Borrelia antibody (-) patients	16	12	28	%57
Total	27	12	39	%69

*Region involvement rates of Morphea lesions*

**Table 1.**

	Number of patients	Mean age (year)
Female	29	39,6
Male	10	44,7
Total	39	40,9

*Demographic data of the patients*



# 4<sup>th</sup> INDERCOS

## Dermatology and Cosmetology Congress with International Participants

27 - 30 MARCH, 2019  
HILTON ISTANBUL BOSPHORUS HOTEL  
ISTANBUL, TURKEY



### OP-28

#### VITILIGO CAMOUFLAGE: EMERGING TREND IN DERMATOLOGY

*Aditya Favade*

*Consultant Dermatologist, Amogh Skin & Hair Clinic, India*

Vitiligo is the most common cause of depigmentation. The paramedical micropigmentation, is responsible for the restoration of areola, scars, and scalp. Here techniques and results of vitiligo micropigmentation are discussed. The paramedical camouflage is obtained through a tattoo using bioresorbable or definitive colors. This technique allows to solve difficult clinical situations, which have not improved with medical or surgical treatments and causing important psychological problems to the patient. At least 3 sessions are required to achieve a good homogeneity of the implanted color.

**Keywords:** Vitiligo, Camouflage, Paramedical Micropigmentation

### OP-29

#### A CASE OF RECALCITRANT LINEAR IGA DERMATOSIS: SUCCESSFULLY TREATED WITH RITUXIMAB

*Zeynep Gizem Kaya İslamoğlu<sup>1</sup>, Fatma Tunçez Akyürek<sup>2</sup>*

*<sup>1</sup>Zeynep Gizem Kaya İslamoğlu, Department of Dermatology, Faculty of Medicine, Selcuk University, Konya, Turkey*

*<sup>2</sup>Fatma Tunçez Akyürek, Department of Dermatology, Faculty of Medicine, Selcuk University, Konya, Turkey*

Linear IgA dermatosis(LABD) is a rare autoimmune bullous skin disease characterized by the formation of subepidermal blisters and linear IgA deposits along the basement membrane zone. The first-line treatment is usually dapsone and systemic steroids. But some patients may be resistant to them. Recently, rituximab, a chimeric IgG1 monoclonal antibody which targets the CD20 molecules have been regarded as a promising treatment of autoimmune bullous diseases. We present a thirty-three year old woman with a severe and refractory LABD. After given rituximab because of unresponsive to conventional treatments, clear improvement of the lesions was observed. Here, we aim to highlight the usefulness and effectiveness of this drug in this disease.

**Keywords:** Linear Ig Dermatitis, Rituximab, Dapsone

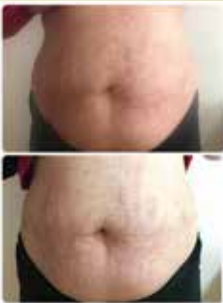

# 4<sup>th</sup> INDERCOS

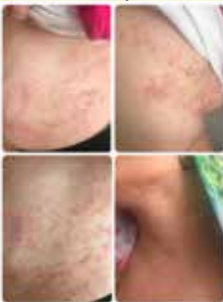**Dermatology and Cosmetology Congress  
with International Participants**  
27 - 30 MARCH, 2019  
HILTON ISTANBUL BOSPHORUS HOTEL  
ISTANBUL, TURKEY



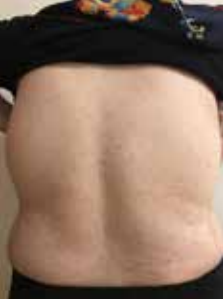**Erythematous lesions, including papules and vesicles involving the neck and body, 451x602mm (72 x 72 DPI)**



**Figure-1: Erythematous lesions, including papules and vesicles involving the neck and body, 451x602mm (72 x 72 DPI)**



**Figure-3: After the treatment, disappearance of lesions on the back. 1066x1422mm (72 x 72 DPI)**







# 4<sup>th</sup> Indercos

## Dermatology and Cosmetology Congress with International Participants

27 - 30 MARCH, 2019  
HILTON ISTANBUL BOSPHORUS HOTEL  
ISTANBUL, TURKEY



### OP-30

### EFFICACY AND SAFETY OF SECUKINUMAB IN THE TREATMENT OF MODERATE-SEVERE PSORIASIS IN OUR CLINIC

*Zeynep Gizem Kaya İslamođlu, Mehmet Unal, Gülcan Saylam Kurtipek  
Selçuk Üniversitesi Tıp Fakültesi, Deri ve Zührevi Hastalıklar Ana Bilim Dalı, Konya*

**INTRODUCTION:** Psoriasis vulgaris is associated with significant comorbidity including depression, increased risk of cardiovascular events, diminished quality of life, as well as overall increased mortality. Furthermore, up to 40% of psoriasis patients have or will develop comorbid psoriatic arthritis in their lifetime. Biologic medications currently approved for the treatment of moderate-to-severe plaque psoriasis include TNF- $\alpha$  inhibitors (adalimumab, etanercept, infliximab), IL-17 pathway inhibitors (ixekizumab, brodalumab, secukinumab), IL-12/IL-23 inhibitors (ustekinumab), and IL-23 inhibitors (guselkumab, tildrakizumab). In 2015, secukinumab, a newly developed biologic targeting the pro-inflammatory IL-17A cytokine, was approved by the European Medicines Agency and the US Food and Drug Administration as first-line systemic therapy for adult patients with moderate-to-severe plaque psoriasis. This agent has demonstrated high levels of clinical efficacy with a favorable safety profile in two phase-III randomized clinical trials. Here, we aim to observed the effectivity, reliability, adwers effects of secukinumab in our patients and commented this results with literature datas.

**MATERIALS & METHODS:** Here, we reported a case of eight patients treated with secukinumab in Selçuk University Department of Dermatology respectively. Secukinumab was given to patients with moderate-severe psoriasis whom previous conventional systemic treatments have failed or conventional systemic treatments are contraindicated. Before treatment Psoriasis Area and Severity Index (PASI) was studied in all patients. Nail involvement, additional diseases and the presence of psoriatic arthritis were recorded. The dose is 300 mg of secukinumab by subcutaneous injection, and the initial doses are 0, 1, 2 and 3 weeks, followed by a 4-month monthly maintenance dose.

**RESULTS:** All patients were well tolerated to treatment. No side effects were observed. Six patient achieved PASI 90 responses. One patient left the treatment at her own request. One of this patients had psoriatic arthritis(PA) and a 50% reduction in PA intensity after induction dose. 4 cases treated with secukinumab unresponsive to previous biological treatments.

**CONCLUSIONS:** These preliminary findings suggest a satisfactory secukinumab efficiency and safety profile, though confirmatory data from large cohorts of secukinumab-exposed patients observed in the long-term in a real-world setting are needed.

**Keywords:** Psoriasis, Secukinumab, Biologic



# 4<sup>th</sup> INDERCOS

## Dermatology and Cosmetology Congress with International Participants

27 - 30 MARCH, 2019  
HILTON ISTANBUL BOSPHORUS HOTEL  
ISTANBUL, TURKEY



### OP-31

#### SECUKINUMAB THERAPY FOR PALMOPLANTAR PUSTULOSIS

*Meltem Turkmen*

*Izmir Bozyaka Training and Research Hospital, Dermatology Department*

**INTRODUCTION & OBJECTIVES:** Palmoplantar pustulosis (PPP) is characterized by a chronic eruption of sterile pustules located on the palms and soles. The levels of anti-interleukin (IL)-17A are increased in PPP lesions and IL-17 may be a central cytokine in the inflammatory process of PPP. In this report secukinumab (anti-IL-17A) therapy found to be effective and well tolerated in PPP. To our knowledge, this is the first report of PPP case successfully treated with secukinumab.

**MATERIALS & METHODS:** A 47 year-old woman presented with severe palmoplantar inflammation characterized by deep-seated pustules with a history of 2 years. Skin lesions were painful and decreased the quality of life of the patient. Initial treatment interventions included topical and systemic steroids, local PUVA, oral retinoid, cyclosporine and methotrexate, but all failed to provide improvement. Based on the clinical and histopathological findings, the patient was diagnosed as PPP. In the treatment of the disease, 300mg secukinumab was administered monthly.

**RESULTS:** Subcutaneous secukinumab was administered and resulted in a rapid regression of the lesions. After the first injection, 70% reduction in pustulas was observed within a week. In the 16th week of the therapy, she is doing well and turned to her work. No side effects were observed during secukinumab treatment.

**CONCLUSIONS:** Palmoplantar pustulosis usually has a chronic and relapsing course and is resistant to treatment. Most of the methods used for the treatment for psoriasis are also used in the management of PPP, however with lower efficacy.

Topical therapy and phototherapy are first-line modalities for the management of PPP. However, the majority of patients require systemic treatment such as oral retinoids, methotrexate, and cyclosporine. But these medications carry risks of adverse effects that may limit their use in clinical practice. Biological treatments are used with changing efficacy in PPP. Data regarding the efficacy of biologic agents in PPP are scarce, being limited to a small number of clinical trials and isolated clinical reports. Anti-TNF- $\alpha$  and anti-IL 12/23 treatment is disappointing. For the treatment of PPP, the results of two small randomized controlled trials (RCTs) suggest that treatment with etanercept and ustekinumab 45 mg may not be more effective than placebo.

Several studies have shown that IL-17 plays a significant role in PPP expression. Thus, biologic agents targeting this cytokine may represent a more effective therapeutic option than anti-TNF and anti-IL-12/23 agents in this group of patients.

In this case, secukinumab therapy found to be effective and well tolerated in PPP. Further clinical trials are needed to further establish the long term effect and safety of the agent in the treatment of PPP, with associated cost-efficacy analyses.

**Keywords:** palmoplantar pustulosis, secukinumab, IL17



# 4<sup>th</sup> INDERCOS

## Dermatology and Cosmetology Congress with International Participants

27 - 30 MARCH, 2019  
HILTON ISTANBUL BOSPHORUS HOTEL  
ISTANBUL, TURKEY



### OP-33

#### IS REALLY ASSOCIATION LICHEN PLANUS AND HEPATITIS-C ?

*Fatma Tunçez Akyürek, Gülcan Saylam Kurtipek*

*Department of Dermatology Selcuk University, Konya, Turkey*

**INTRODUCTION:** Lichen planus (LP) is a T-cell mediated dermatosis with unknown etiology that is affecting the skin, oral mucosa, nail and hair follicle. Although the cause is not known, there are many articles in the literature that show the association between LP and hepatitis-C, especially oral LP.

**MATERIALS-METHODS:** The records of 145 patients who were admitted to our clinic between March 2014 and 2018 and diagnosed clinically and histopathologically as LP were retrospectively reviewed and none of them had anti-HCV positivity.

**DISCUSSION:** The prevalence of chronic hepatitis C in oral LP patients has been reported to vary between geographical regions. Based on the literature and textbook books, hepatitis-C screenings were performed in patients who were followed up with LP clinically and histopathologically in our clinic for a long time. We did not find any association between HCV and LP in our study. This could be attributed to a lower prevalence of HCV in our country or other triggering factors contributing in our cases.

**Keywords:** Lichen planus, Hepatitis C virus, etiology



# 4<sup>th</sup> Indercos

## Dermatology and Cosmetology Congress with International Participants

27 - 30 MARCH, 2019  
HILTON ISTANBUL BOSPHORUS HOTEL  
ISTANBUL, TURKEY



### OP-35

#### A CASE OF ACQUIRED SCROTAL LYMPHANGIOMA CIRCUMSCRIPTUM

Gökhan Çeker<sup>1</sup>, Meral Çeker<sup>2</sup>

<sup>1</sup>Department of Urology, Bülent Ecevit University Medical Faculty, Zonguldak

<sup>2</sup>Department of Infectious Diseases and Clinic Microbiology, Bülent Ecevit University Medical Faculty, Zonguldak

Lymphangioma circumscriptum (LC) is a benign proliferative disorder seen in lymphatic system. They are superficial malformations of dilate lymphatic vessels. It is usually composed of vesicle clusters, which are filled with clear fluid and tend to merge. The proximal boundaries of the extremities that are concentrated in the lymphatic flow are common in areas such as the perianal, inguinal and axillary regions.

**CASE:** A 68-year-old male patient was admitted to our clinic with scrotal lesions continuing for 6 months. There were scrotal edema and transparent colored vesicles with multiple 2-4 mm diameters covering the entire outer surface of the scrotum and continuing at the penile root. It was learned that the patient had a lesion discharge in the left inguinal region 35 years ago, and that tuberculosis was diagnosed as a result of the samples and that the lesion was completely treated after 1 year of treatment. Active tuberculosis was excluded in patient without elevation in acute phase reactants and penoscrotal temperature. A punch biopsy was conducted from the patient's penoscrotal vesicles. Pathology was lymphangioma. After that, when a detailed physical examination was performed, the swelling of the left leg, which had not been reported in the patient's history for about 30 years, was detected.

Deep venous thrombosis was excluded in the radiological images. Radioactive involvement of the lymphatic system was not observed in the left lower extremity in the lymphoscintigraphy. It started to be followed up with a compression stocking due to extensive edema in the lower left extremity. Treatment options for scrotal lesions have been described and the patient has not yet applied to a center for treatment.

**DISCUSSION:** LC may be seen congenital or acquired. Congenital lymphangiomas are caused by defects during vascular development in the prenatal period. It should not be forgotten that acquired lymphangiomas may develop secondary to infections, tuberculosis, filariasis, radiotherapy.

Surgical excision should be considered first in primary treatment of lymphangiomas. Other treatment options include radiotherapy, sclerotherapy, cryotherapy, laser, radiofrequency energy and cauterization. The lowest risk rate is seen in the surgeon and Carbon dioxide laser application. Most of the treatment modalities are more likely to fail due to multifocal placement in the lymphatic bed and failure to affect on deep components.

We think that the lesion seen 35 years ago in the patient may be tuberculous lymphadenitis and lymphadenic obstruction which developed as a secondary to this and subsequent lymphatic insufficiency.

**CONCLUSION:** The patient who applied with scrotal vesicous lesion may have a lesion due to lymphatic insufficiency and therefore a detailed physical examination should be performed to include the lower extremity. Scrotal lymphangioma should be kept in mind in patients presenting with scrotal edema, which is a suspicion of skin involvement of tuberculosis.

**Keywords:** Lymphangioma circumscriptum, tuberculosis, lymphatic system





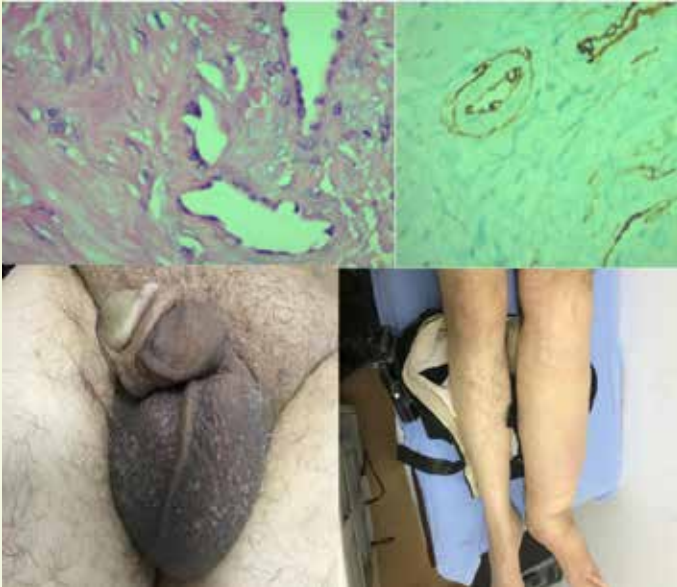# 4<sup>th</sup> Indercos

Dermatology and Cosmetology Congress  
with International Participants

27 - 30 MARCH, 2019  
HILTON ISTANBUL BOSPHORUS HOTEL  
ISTANBUL, TURKEY



## Pathological figures and physical examination photos



*Microscopic picture of lymphangioma circumscriptum with widely spaced vascular channels (figure 1 stained by hematoxylin and eosin, 20 $\times$ , figure 2 stained by D2-40, 20 $\times$ )*



# 4<sup>th</sup> INDERCOS

## Dermatology and Cosmetology Congress with International Participants

27 - 30 MARCH, 2019  
HILTON ISTANBUL BOSPHORUS HOTEL  
ISTANBUL, TURKEY



**OP-36**

### **SURPRISING EVOLUTION IN THE TREATMENT OF A HYPERTROPHIC SCAR**

*Iustin Hancu, Iasmina Maria Hancu, Laurentiu Ilinca, Patricia Cristodor*

*Department of Dermatology, Victor Babes University of Medicine and Pharmacy, Timisoara, Romania*

**INTRODUCTION & OBJECTIVES:** Hypertrophic and keloid scars have always been a great challenge for the surgical specialities: while some regions (such as face) may be expected to heal with minimal scars, others (like the décolletage) are very likely to develop hypertrophic or keloid scars. As their prevention and treatment implies a complex approach, we wanted to observe if botulinum toxin has its place in solving this issue.

**MATERIALS & METHODS:** In a male patient, aged 56, with presternal hypertrophic scars dating for more than ten years, we initiated a complex therapy, as it follows: Careful excision and suture of the defect. Infiltration of the wound edges with Triamcinolone solution, Contractubex gel, silicone sheets and local compression after removing the stitches. Injection of Botulinum toxin in a few points along the scar line when we noticed that, in spite of the above-mentioned treatment, the scar started to thicken. After injecting the botulinum toxin the patient refused to continue any treatment and we only reviewed him after about 4 months.

**RESULTS:** 22 weeks from the surgical excision and 17 weeks after the discontinuation of therapy the scar had a hypertrophic appearance, except for 3 regions where we had injected the botulinum toxin and where the skin had a normal aspect (not even a slight scar line was detectable).

**DISCUSSION:** We believe that the striking regression and healing in several regions of the scar area is somehow connected to the botulinum toxin.

**CONCLUSION:** Our case, though singular, raises the hope for achieving more aesthetic results in wound closure (especially in difficult regions) by the aid of botulinum toxin. Further studies are needed in order to confirm our observation.

**Keywords:** Hypertrophic scars, complex therapy, botulinum toxin



# 4<sup>th</sup> INDERCOS

## Dermatology and Cosmetology Congress with International Participants

27 - 30 MARCH, 2019  
HILTON ISTANBUL BOSPHORUS HOTEL  
ISTANBUL, TURKEY



### OP-38

#### A CASE OF INVERSE KLIPPEL-TRENAUNAY SYNDROME WITH NO MUTATION IN PIK3CA GENE

*Sezin Fiçicioğlu<sup>1</sup>, Selma Demir<sup>2</sup>*

<sup>1</sup>Department of Dermatology, Trakya University Medical Faculty, Edirne, Turkey

<sup>2</sup>Department of Genetics, Trakya University Medical Faculty, Edirne, Turkey

**INTRODUCTION & OBJECTIVE:** Klippel-Trenaunay syndrome (KTS) is one of the congenital angiodysplasias particularly presenting with capillary, venous and sometimes lymphatic malformations and limb overgrowth. And in recent years KTS was thought to belong to a newly described spectrum which is called phosphoinositide-3 kinase (PI3K)-related overgrowth spectrum. Mosaic gain of function mutations in PIK3CA gene leads to clinical manifestations and this kind of activating mutations in PIK3CA gene were disclosed in patients with KTS. But KTS cases with hypotrophic limbs rather than limb overgrowth by the hyperplasia of soft and bone tissue, also have been described so far. The term "inverse KTS" have been proposed for such cases.

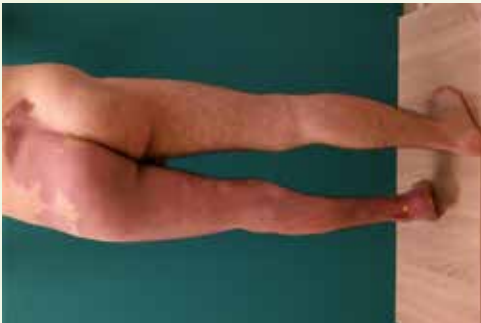**MATERIALS & METHODS:** Here we report a male inverse KTS patient with a vascular malformation and hypotrophy on whole left leg. We checked for any mutation in PIK3CA gene with a hypothesis that loss of function mutations, rather than gain of function mutations, in PIK3CA gene can be detected.

**RESULTS:** We found neither gain of nor loss of function mutations in PIK3CA gene.

**CONCLUSION:** KTS cases can present with hypotrophy of limbs rather than the hypertrophy found in usual cases. Mutations in PIK3CA gene could not be the probable mechanism in the etiopathogenesis of KTS and further investigations are needed.

**Keywords:** Klippel-Trenaunay, hypotrophy, lower extremity

**Figure 1**





# 4<sup>th</sup> INDERCOS

## Dermatology and Cosmetology Congress with International Participants

27 - 30 MARCH, 2019  
HILTON ISTANBUL BOSPHORUS HOTEL  
ISTANBUL, TURKEY



### **"A CLINICAL PHENOTYPE, THE SEVERITY OF DISEASE AND TRIGGER FACTORS OF PATIENTS WITH ROSACEA IN SOUTHEASTERN OF TURKEY"**

*Semahat Alp Erdal*

*Health Sciences University, Gazi Yaşargil Diyarbakır Training and Research Hospital, Dermatology Clinic, Diyarbakır, Turkey*

**INTRODUCTION&OBJECTIVES:** Rosacea is a chronic inflammatory disease of the facial region that affects the psychosocial condition by disrupting the cosmetic appearance, which is mostly characterized by redness on convexity of the face. The prevalence of rosacea is highest among fair-skinned individuals, particularly those of Celtic and northern European descent. Considering the large geographic differences of our country, we aimed to present data including the qualitative and quantitative aspects of clinical phenotypes, the severity of the disease and differences in subtypes in individuals living in our region.

**MATERIAL&METHODS:** The patients with rosacea living in our region who were diagnosed in outpatient clinic between 2012-2018 years were selected retrospectively and those whose recorded detailed information were evaluated. Demographic characteristics, Fitzpatrick skin phototype, triggering factors, the duration and location of disease, disease severity determined by clinician rating scale, ocular findings as a result of ophthalmolog examination were modified in accordance with the classification criteria standardized by American National Rosacea Society in 2017. Rosacea clinical subtypes (Erythematotelangiectatic, Papulopustular, Phymatous and Ocular subtype) were determined by considering diagnostic subtypes, major and secondary phenotypes criteria of this expert committee. In addition to descriptive statistical methods, the comparisons between clinical subtypes were interpreted by chi-square test.

**RESULTS:** A total of 54 patient were 43 female and 11 male patients aged from 23-72 years. The mean age of patient was  $45,61 \pm 11,0$  years, mean disease duration was  $53.2 \pm 60,04$  months. Skin phototypes in all cases were type II (n=37) and type III (n=17). The most common clinical subtype by 48,10% was erythematotelangiectatic rosacea. Both erythematotelangiectatic and papulopustular lesions were present in 31,48% of all subjects with erythematotelangiectatic and papulopustular rosacea. The ratio of patients (7 male and one female) with phymatous rosacea who were all mild or moderate severity of disease was found 14,8%. When evaluated according to the severity of ophthalmic disease, only 2 female had moderate ocular rosacea accompanied by erythematotelangiectatic type facial lesions, Of all cases in the study, 37(68,5%) had mild ocular involvement. According to the clinician's rating scale, rosacea was severe in only 4 (7,4%) individuals, while in others were mild (42,6%) and moderate (50%). Hot bath, emotional stress, exercise and UV light were most common triggering factors.

**CONCLUSION:** This study supports that it should not be ignored the fact that there may be more than one sub-type at the same time, or that might be potential of progression from one sub-type to another. In addition to being different subtypes in the same patient, being mild to moderate components which were observed in the majority of patients is noteworthy. Similar studies are needed from different regions in order to have an idea about status of subtypes and geographical difference of rosacea which its prevalence is unknown in our country.

**Key Words;** rosacea, classification, phenotypes, ocular, phymas.





# 4<sup>th</sup> INDERCOS

Dermatology and Cosmetology Congress  
with International Participants



27 - 30 MARCH, 2019  
HILTON ISTANBUL BOSPHORUS HOTEL  
ISTANBUL, TURKEY

Figure 1. A Female had papulopustular and a male had erythematotelangiectatic subtype rosacea

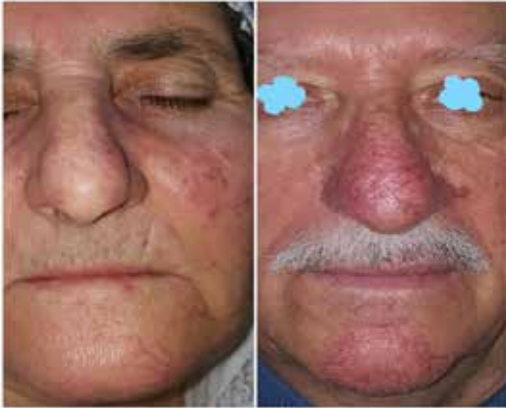

Figure 2. Phymatous rosacea; A male had rhinophyma.

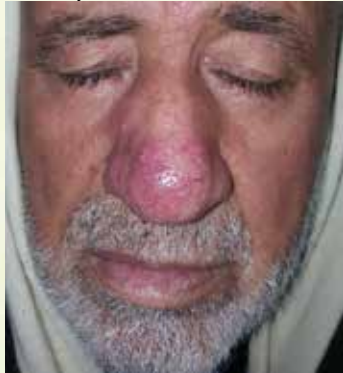

Figure 3.



# 4<sup>th</sup> INDERCOS

## Dermatology and Cosmetology Congress with International Participants

27 - 30 MARCH, 2019  
HILTON ISTANBUL BOSPHORUS HOTEL  
ISTANBUL, TURKEY



**Table1.** Clinical findings of the patients

<b>Features of Cases</b>	n (%)
<b>Gender</b>	
Female	43 (79.6)
Male	11 (20.4)
Total	54 (100)
<b>Skin Phototype</b>	
Type 2	37 (68.5)
Type 3	17 (31.5)
<b>Signs and Symptoms</b>	
Erythema	54 (100.0)
Burning/Stinging	34 (63.0)
Itching	32 (59.3)
Flushing	43 (79.6)
<b>Findings</b>	
Telangiectasia	44 (81.5)
Papules	43 (79.6)
Pustules	30 (55.6)
Odema	8 (14.8)
Nodules/Cysts	4 (7.40)
Rinofima	8 (14.8)
<b>Involving area</b>	
Cheek	51 (94.4)
Nose	44 (81.5)
Forehead	35 (64.8)
Eyebrow	13 (24.1)
Cheek	40 (74.1)
Ears	7 (13.0)
Neck	6 (11.1)
Decollete	1 (1.9)
Scalp	3 (5.6)



# 4<sup>th</sup> INDERCOS

## Dermatology and Cosmetology Congress with International Participants

27 - 30 MARCH, 2019  
HILTON ISTANBUL BOSPHORUS HOTEL  
ISTANBUL, TURKEY



### OP-40

#### LINEAR ATROPHODERMA OF MOULIN: A CASE REPORT

*Betul Macit<sup>1</sup>, Sirin Pekcan Yasar<sup>1</sup>, Pembegul Gunes<sup>2</sup>*

*<sup>1</sup>Department of Dermatology, Haydarpasa Numune Erh, Istanbul, Turkey*

*<sup>2</sup>Department of Pathology, Haydarpasa Numune Erh, Istanbul, Turkey*

Linear atrophoderma of Moulin is a rare and self-limited dermatologic disorder characterized by acquired atrophic band-like skin lesions that consistently follows the lines of Blaschko. Usually it begins in childhood or adolescence and has good prognosis, there is no evidence of any long term progression. Its origin and pathogenesis remain unknown.

We describe a case of 16-year-old boy with clinical and histological features of linear atrophoderma of Moulin. Twenty years after its initial description, there are only 35 cases of linear atrophoderma of Moulin previously reported in the literature. We report this case of LAM because of paucity of its clinical and histopathological description in the literature.

**Keywords:** atrophoderma, linear hyperpigmentation, lines of Blaschko



# 4<sup>th</sup> INDERCOS

Dermatology and Cosmetology Congress  
with International Participants

27 - 30 MARCH, 2019  
HILTON ISTANBUL BOSPHORUS HOTEL  
ISTANBUL, TURKEY



## OP-42

### COMPARISON OF CHANGES IN SERUM IGE LEVELS BEFORE AND AFTER OMALIZUMAB TREATMENT OF 127 PATIENTS WITH CHRONIC SPONTANEOUS URTICARIA

*Mehmet Demirel<sup>1</sup>, Ayça Yazıcı<sup>1</sup>*

*Mersin University, Department of Dermatology<sup>1</sup>*

**BACKGROUND/ OBJECTIVE:** In this study, we aimed to observe the changes in serum IgE levels in patients with chronic spontaneous urticaria after omalizumab treatment.

**SUBJECTS/ METHODS:** 127 patients with chronic spontaneous urticaria were included in the study. Serum IgE levels were measured before and 3 months after treatment with omalizumab and changes were observed.

**RESULTS:** It was observed that mean serum IgE levels were increased after omalizumab treatment. The results were discussed with the literature datas.

**Keywords:** omalizumab, IgE, chronic spontaneous urticaria,





# 4<sup>th</sup> INDERCOS

## Dermatology and Cosmetology Congress with International Participants

27 - 30 MARCH, 2019  
HILTON ISTANBUL BOSPHORUS HOTEL  
ISTANBUL, TURKEY



### OP-43

#### DERMOSCOPY FOR THE DIAGNOSIS OF BOWENOID PAPULOSIS

*Yıldız Gürsel Ürün, Sezin Fiçicioğlu, Mustafa Ürün*

*Department of Dermatology, Trakya University, Edirne, Turkey*

**INTRODUCTION:** Bowenoid papulosis (BP) corresponds to multifocal intraepithelial neoplasia in the anogenital region, seen most frequently in young adults. Clinically, it most commonly presents with multiple, well-demarcated, hyperpigmented, verrucous papules and plaques. Histopathologically, it is characterized by epidermal hyperkeratosis with atypically matured keratinocytes that have hyperchromatic and pleomorphic nuclei, mitotic figures, and epidermal multinucleated giant cells.

The diagnosis of BP can be confusing due to its clinical features. In the differential diagnosis of BP, pigmented melanocytic (melanoma and melanocytic nevi) and pigmented non-melanocytic [genital warts, lichen planus, seborrheic keratosis, Bowen's disease, basal cell carcinoma (BCC), SCC] lesions should be considered. Dermoscopic diagnostic accuracy criteria have not yet developed in diseases such as Bowen disease, pigmented lichen planus, and BP.

The primary aims of this study were: 1) to research the specific and typical features of BP in dermoscopy, 2) to present a case of BP and its clinical findings, along with a corresponding literature review.

**CASE REPORT:** A 46-year-old woman presented with multiple, small, gray-brown papules on the vulva and perianal region with a duration of nearly 2 months (Fig.1). Two skin biopsies were performed from the perianal and vulvar region with the differential diagnosis. Also, a dermoscopic examination was performed, which revealed brown-gray structureless areas with round or lobulated shapes, an linear distributed brown-gray dots and glomerular vessels in these homogenous structures (Fig. 2-3). A microscopic examination disclosed an epidermis with varying degrees of hyperplasia. On the basis of these clinical and histopathologic findings, the patient was diagnosed as having bowenoid papulosis and topical imiquimod treatment was started.

**DISCUSSION:** The natural course of BP is unpredictable: the lesions may increase, decrease, and even disappear spontaneously. Malignant transformation risk is between 1-2.6%; therefore, early diagnosis and follow-up is important. Dermoscopy has recently gained importance in the early and differential diagnosis of BP.

The dermoscopic findings of BP in studies published as case reports and small case series between 2011 and 2018 are summarized in Table 1. Our findings are very similar to previously reported cases. The most common dermoscopic findings are brown-gray dot structures with linear distributed and dotted/coiled vascular structures. However, there are no specifically characterized dermoscopic findings of BP in the literature because clinical BP lesions can be exophytic, warty or papillary structures that are pigmented or skin-colored; the dermoscopic appearance differs in parallel with the clinical appearance. Therefore, the identification of different dermoscopic features in BP are needed and larger case series may help to characterize the dermoscopic features.

**Keywords:** Dermoscopy, Bowenoid Papulosis, Differential diagnosis



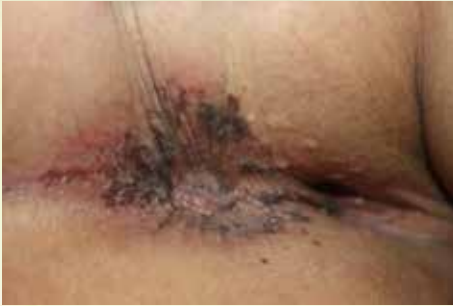# 4<sup>th</sup> INDERCOs

Dermatology and Cosmetology Congress  
with International Participants

27 - 30 MARCH, 2019  
HILTON ISTANBUL BOSPHORUS HOTEL  
ISTANBUL, TURKEY

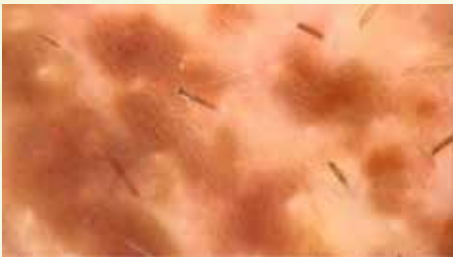

**Fig 1.**



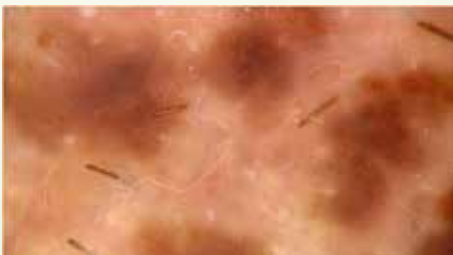*Gray-brown papillary lesions on the perianal region*

**Fig 2.**



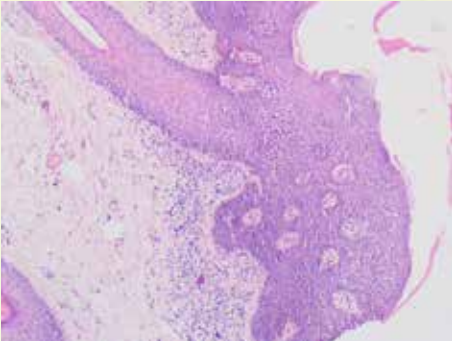
*Brown-gray structureless areas with linear distributed brown-gray dots*

**Fig 3.**



*Brown-gray structureless areas with glomerular vessels*

**Fig 4.**



*Atypical and dyskeratotic keratinocytes with mitotic figures (H&E, x10).*

**Table 1.**

Features	Vázquez-López et al. (9)	Lin et al. (10)	Ferrari et al.(11)	Dong et al. (8)	Tschantl et al. (12)	Marcucci et al. (13)	Vaccari et al. (7)	Our case
Homogenous pattern		+						
Keratosis/Exophytic papillary structures			+	+		+		
White/Brown/Gray structureless areas	+		+		+		+	+
Linear brown-gray dots					+	+	+	+
Dotted/coiled vessels				+	+	+		
Glomerular /Hairpin vessels			+					+

*The most common dermoscopic findings in bowenoid papulosis according to publications*



# 4<sup>th</sup> INDERCOS

## Dermatology and Cosmetology Congress with International Participants

27 - 30 MARCH, 2019  
HILTON ISTANBUL BOSPHORUS HOTEL  
ISTANBUL, TURKEY



### OP-44

#### **INTRALESIONAL TRANEXAMIC ACID IN TREATMENT OF TELANGIECTASIA: REVERSIBLE EFFECT AND RESISTANCE TO THERAPY**

*Erhan Ayhan*

*University of Health Sciences Gazi Yaşargil Training and Research Hospital, Department of Dermatology, Diyarbakır, Turkey*

Telangiectasias or angioectasias are small dilated-blood vessels near the surface of the skin or mucous membranes, measuring between 0.5 and 1 millimeter in diameter. They typically appear as fine pink or red lines and will whiten when under pressure. Treatments for telangiectasias and reticular veins include sclerotherapy, laser therapy, intense pulsed light treatment, microphlebectomy and thermocoagulation. In this report, two patients with telangiectasia in two different regions were treated with intralesional tranexamic acid (Txa).

33-year-old woman (Fig. 1) and 27 year-old male (Fig. 2) patients were admitted with complaints of telangiectasia. The female patient had regular branching in his leg, while male patient had irregular branching telangiectasias, which were located in the nasal root. Both patients administered intralesional Txa three times in one week intervals. In both patients, fading and loss of vessels were observed after 1 week the first application. However, after the next two treatments, the vessels were similar to the pre-treatment appearance.

Txa is a drug used in hemophilia, hereditary angioedema and severity bleeding. Txa is a synthetic lysine analog which has an antifibrinolytic effect through the reversible blockade of lysine-binding sites on plasminogen molecules. It inhibits conversion of plasminogen to plasmin. This amount of plasmin formation is reduced. At the same time plasmin plays an important role in angiogenesis. Plasmin converts extracellular matrix-bound VEGF into freely diffusible forms. Txa, a plasmin inhibitor, prevents angiogenesis by blocking the action of plasmin. It also reduces VEGF and endothelin 1 (ET)-1. Endothelin 1 is a potent vasoconstrictor that is thought to be a key factor in the pathogenesis of PA hypertension. There are two known receptors on which it acts: endothelin A and endothelin B. Endothelin A receptors are present on smooth muscle cells, and agonist action causes vasoconstriction; endothelin B receptors are present on endothelial cells, and agonist action causes both relaxation and vasoconstriction through different pathways. In addition, endothelin B receptors are involved in the clearance of endothelin. Kim et al. In his study, it was found that Txa decreases VEGF and endothelin-1 levels but this decreasing was only significant in the level of endothelin-1.

In our opinion, the success of Txa in the first application has led to vasoconstriction with the activation of endothelin A instead of endothelin B which is normally active and relaxes. However, in repetitive applications, Txa acid was ineffective in two pathways because of the extremely low amount of endothelin-1 and no effect was observed.

In conclusion, we believe that tranexamic acid has a transient effect in the treatment of telangiectasia. We recommend increasing the application intervals for to continue the effect

**Keywords:** telangiectasia, tranexamic acid, antifibrinolytic, treatment, systemic therapy, coagulant agent.





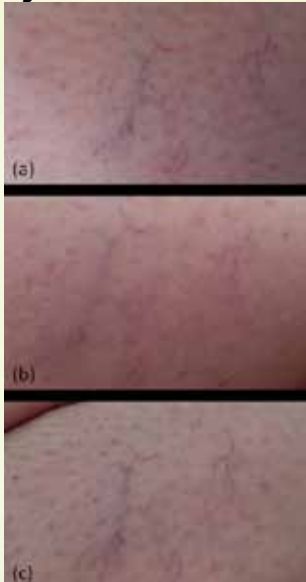
# 4<sup>th</sup> INDERCOS

Dermatology and Cosmetology Congress  
with International Participants



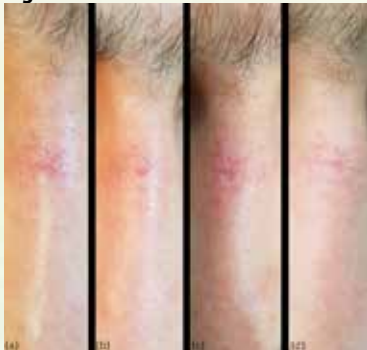27 - 30 MARCH, 2019  
HILTON ISTANBUL BOSPHORUS HOTEL  
ISTANBUL, TURKEY

**Figure 1**



*View of telangiectasia at baseline (A) and after one (B) and three application(C), therapy of intralesional traxenamic acid.*

**Figure 2**



*View of telangiectasia at baseline (A) and after one (B), two (C) and three applications(D), therapy of intralesional traxenamic acid.*



# 4<sup>th</sup> INDERCOS

## Dermatology and Cosmetology Congress with International Participants

27 - 30 MARCH, 2019  
HILTON ISTANBUL BOSPHORUS HOTEL  
ISTANBUL, TURKEY



### OP-45

#### FOVEAL THINNING IN PATIENTS WITH RECURRENT APHTHOUS ULCER

Betül Şerefican<sup>1</sup>, Ümit Doğan<sup>2</sup>

<sup>1</sup>Department of Dermatology, Bolu Abant İzzet Baysal University, Bolu, Turkey

<sup>2</sup>Department of Ophthalmology, Bolu Abant İzzet Baysal University, Bolu, Turkey

**OBJECTIVE:** Recurrent aphthous ulcer (RAU) is the chronic inflammatory disease of the oral mucosa and is characterized by painful recurrent ulcers. Our aim was to compare the foveal thickness in RAU patients and healthy subjects. Although Behçet's disease and concomitant ocular findings are well defined, to the best of our knowledge, there is no study in the literature on ocular findings that can be observed in RAU patients which share similar pathways with Behçet's disease.

**METHODS:** A total of 29 RAU patients and 29 age- and gender-matched controls were evaluated. The foveal thicknesses were measured using optical coherence tomography.

**RESULTS:** The mean foveal thickness in the RAU and control groups was  $213,93 \pm 15,248$  and  $223,48 \pm 15,125$   $\mu\text{m}$ , respectively. Participants with RAU have thinner foveas ( $p = 0.02$ ) than the controls. There was no correlation between foveal thickness and visual acuity.

**CONCLUSION:** Secretion of proinflammatory cytokines have been shown in the development of aphthous ulcers. Vasculitic changes may be observed within the parafoveal vasculature. Foveal thinning may be a complication of intraocular inflammation. It may be meaningful to evaluate foveal thickness in patients with RAU to detect retinal vasculitis in terms of early diagnosis and treatment of foveal atrophy.

**Keywords:** recurrent aphthous ulcer, foveal thickness, foveal thinning



# 4<sup>th</sup> INDERCOS

## Dermatology and Cosmetology Congress with International Participants

27 - 30 MARCH, 2019  
HILTON ISTANBUL BOSPHORUS HOTEL  
ISTANBUL, TURKEY



### OP-46

#### DERMOSCOPIC PROFILE OF PIGMENTED PURPURIC DERMATOSIS: NEW OBSERVATIONS

Mahmut Sami Metin<sup>1</sup>, Ömer Faruk Elmas<sup>2</sup>

<sup>1</sup>Department of Dermatology, Batman Medical Park Hospital, Batman, Turkey

<sup>2</sup>Department of Dermatology, Ahi Evran University, Kırşehir, Turkey

**AIM:** Here we aimed to identify dermoscopic findings of PPD which will make the diagnosis easy by reducing the use of invasive procedures.

**MATERIAL-METHODS:** The study included the patients with histopathologically confirmed cases of pigmented purpuric dermatosis. Demographic, clinical and dermoscopic features of all the cases were retrospectively reviewed.

**RESULTS:** The most common dermoscopic findings were red globules and red dots which were observed in all the cases (100%), followed by coppery brown background (72%), brown lines reticular (40%) and subtle brown dots (40%). The other findings were brown circles (32%), red circles (32%), grey dots (32%), red background (8%), serpentine vessels (8%), thick brown lines (4%), rosette structures (8%) and thick linear vessel (4).

**CONCLUSION:** It can be said that PPD has peculiar dermoscopic findings. Here we identified some features which were not describe previously for PPD: Red circles, rosette structures, light brown background and red background. Dermoscopic examination may facilitate the diagnostic process by reducing the use of invasive methods.

**Keywords:** dermoscopy, pigmented purpuric dermatosis, Schamberg disease



# 4<sup>th</sup> Indercos

## Dermatology and Cosmetology Congress with International Participants

27 - 30 MARCH, 2019  
HILTON ISTANBUL BOSPHORUS HOTEL  
ISTANBUL, TURKEY



### OP-47

#### GIANT CELL TUMOR OF THE TENDON SHEATH: A CLINICOPATHOLOGIC STUDY OF 31 CASES

Asuman Kilitci<sup>1</sup>, Ömer Faruk Elmas<sup>2</sup>

<sup>1</sup>Department of Pathology, Ahi Evran University Faculty of Medicine, Kırşehir, Turkey

<sup>2</sup>Department of Dermatology, Ahi Evran University Faculty of Medicine, Kırşehir, Turkey

**INTRODUCTION:** Giant cell tumor of the tendon sheath (GCTTS) is the second most common benign tumor of the hand after ganglion cysts. Feet, knees and others, can also be involved. It is a slowly growing, usually painless lesion of soft tissues. The most widely accepted etiologic theories include trauma, infection, inflammation, osteoclastic proliferation, metabolic disease, and neoplasia. We describe here a series of 31 cases of GCTTS to try to define the epidemiological and clinicopathologic findings of the disease.

**MATERIAL-METHODS:** The case records of all patients diagnosed to have GCTTS by our pathology department from 2009 to 2018 were analyzed. We introduced 31 cases of GCTTS in this study. Four cases of fibroma of the tendon sheath were excluded from the study. The age of patients, gender, site of occurrence, size of the lesion, presenting symptoms, treatment modality, histopathological reports, and recurrence were investigated, and noted.

**RESULTS:** Ages of patients ranged from 14 to 74 years with most cases occurring in their thirties. There was a female predominance of 11 males to 20 females. The majority of patients had a painless subcutaneous palpable mass which gradually increased in size. The most frequent site of the tumor was the finger in 61.3 % (n=19). The other lesions were detected over the hand in 32.3% of the patients (n=10), foot in 3.2% (n=1), over the right knee (large joint) in 3.2% of patients (n=1). Among the small digit tumors the frequent affected site was the thumb. Single nodules (n=21) were more common than multiple (n=10). One male had maximum lesions on his left little finger with 18 GCTTS. The most common preoperative clinical diagnoses were GCTTS, fibroma, lipoma, schwannoma and epidermal cyst. Complete excision was the treatment in all of the cases. The tumors were firm/elastic, usually encapsulated, regular in shape, with smooth contour varying in size from 0.4 to 2.5 cm (average size 1.25 cm). Cut section of the tumor was grayish white mottled with yellow. Histologic appearance of the tumors consisted of multinucleated giant cells, polygonal histiocytes, foamy histiocytes and hemosiderin laden macrophages. Immunohistochemically, CD68 and ki-67 were applied in some of the patients to support the diagnosis. Local recurrence was not seen.

**CONCLUSIONS:** We must distinguish GCTTS from other similar pathological processes. A different histopathologic variation can be noticed between GCTTS involving the digits and large joints. The location and the strict adherence of the tumor to the tendon or neurovascular bundles may cause difficulties. Early diagnosis and treatment with wide excision prevent local recurrence.

**Keywords:** giant cell tumor, tendon sheath, histopathology





# 4<sup>th</sup> INDERCOS

## Dermatology and Cosmetology Congress with International Participants

27 - 30 MARCH, 2019  
HILTON ISTANBUL BOSPHORUS HOTEL  
ISTANBUL, TURKEY



**OP-48**

### **STOP SWEATING AND START LIVING**

*Prof. Dr K Prem Anand<sup>1</sup>*

<sup>1</sup>Prof Dr K Prem Anand

<sup>2</sup>Director, Anew Aesthetics

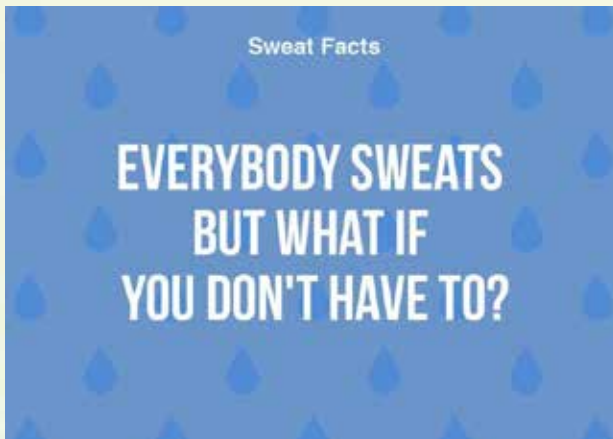Hyperhidrosis, or excessive sweating, is a common disorder which produces a lot of unhappiness. An estimated 2.8% of the world population suffer from excessive sweating. Among this the underarms (axillary hyperhidrosis) is 50.8% and the rest are the palms and soles of the feet (palmoplantar hyperhidrosis). Underarm problems tend to start in late adolescence, while palm and sole sweating often begins earlier, around age 13 (on the average). Untreated, these problems may continue throughout life.

Sweating is embarrassing, it stains clothes, ruins romance, and complicates business and social interactions. Severe cases can have serious practical consequences and even leads to psychological depression as well, making it hard for people who suffer from it to hold a pen, grip a car steering wheel, or shake hands.

Here we discuss in brief about the causes, treatment modalities, current trends and our experience

**Keywords:** hyperhidrosis, underarm sweating, hair reduction, excessive sweating, odor

### **excessive under arm sweating**



*on stop solution for hyperhidrosis - our clinical experience*



# 4<sup>th</sup> INDERCOS

## Dermatology and Cosmetology Congress with International Participants

27 - 30 MARCH, 2019  
HILTON ISTANBUL BOSPHORUS HOTEL  
ISTANBUL, TURKEY



### OP-49

#### CUTANEOUS LEISHMANIASIS IN REPUBLIC OF YEMEN

*Baligha Ahmed Alsalahi<sup>1</sup>*

<sup>1</sup>*Baligha Alsalahi*

<sup>2</sup>*Nhaj Altakwa dental and derma center*

<sup>3</sup>*Dermatology and Aesthetic medicine*

**BACKGROUND:** Cutaneous leishmaniasis is transmitted by the bite of an infected female phlebotomine sandfly. Sandflies are noiseless fliers that rest in moist, dark places and are typically most active in evening and nighttime hours. Other modes of transmission are congenital and parenteral (blood transfusion, needle sharing, and laboratory accident).

**OBJECTIVE:** The objective of the study is to identify the chronic skin disorder.

**PATIENTS AND METHODS:** 30 yemeni males and females patients 5- 40 years old. The presentation of cutaneous disease varies depending on the stage of disease, although it mainly occurs in 2 forms, (1) an oriental sore caused by *L tropica* and (2) American cutaneous leishmaniasis caused by *L brasiliensis*. Lesions are usually found in exposed areas (eg, face, arms, legs). The skin lesion begins as a nontender, firm, red papule several centimeters in size at the site of the sandfly bite. In time, the lesion becomes darker, widens with central ulceration, serous crusting, and granuloma formation. The border often has a raised erythematous rim known as the volcano sign. Skin slit and sceaiping sained with Geimsa stain showed leishmania *Donovani* bodies. Skin biopsy and histopathological findings showed infilamaory granuloma with leishmania bodies. All the patients treated with antimonial drugs injection.

**RESULTS:** The clinical data and the investigations showed that all the patients had cutaneous leishmaniasis

**CONCLUSION:** cutaneous leishmaniasis is very common skin disease in republic of yemen. It is endemic in some areas or regions. The local names of cutaneous leishmaniasis in yemen are Othrah, shoknofah, Ebadah and oufeiah.

**Keywords:** Cutaneous, leishmaniasis, Yemen



# 4<sup>th</sup> INDERCOS

Dermatology and Cosmetology Congress  
with International Participants  
27 - 30 MARCH, 2019  
HILTON ISTANBUL BOSPHORUS HOTEL  
ISTANBUL, TURKEY



## OP-50

### ORAL TOFACITINIB IN THE TREATMENT OF ALOPECIA AREATA: A SINGLE-CENTRE EXPERIENCE OF 4 CASES

*Begüm Ünlü, Ümit Türsen*

*Department of Dermatology, Mersin University Medical School*

Alopecia areata is an autoimmune disease affecting both adults and children. It has a chronic relapsing course. Patients with alopecia areata frequently experience psychiatric impairment and decrement in self esteem. Tofacitinib citrate is a Janus kinase inhibitor has recently been used to treat alopecia areata. It is working by inhibiting JAK and T-cell-mediated inflammatory responses.

We present 1 adolescent and 3 adult patients with alopecia areata successfully treated with oral tofacitinib. One of the patient also had psoriasis vulgaris diagnosis that was also improved with tofacitinib.

There is limited data in the literature about tofacitinib treatment in alopecia areata. We aim to share our experiences on this therapeutic approach.

**Keywords:** oral tofacitinib, alopecia areata, alopecia



# 4<sup>th</sup> INDERCOs

## Dermatology and Cosmetology Congress with International Participants

27 - 30 MARCH, 2019  
HILTON ISTANBUL BOSPHORUS HOTEL  
ISTANBUL, TURKEY



### OP-51

#### USE OF PILATES MATS IN DERMAL FILLER INJECTION TRAINING

*Begüm Ünlü, Gizem Filazi, Ümit Türsen*

*Department of Dermatology, Mersin University Medical School, Mersin, Turkey*

There is a rapid growth in dermal filler use worldwide. Training of dermal filler injection can be challenging for both educator and residents. Because of complex anatomical structure of face, first experience of dermal filler injection on a patient may be risky. There are also expensive cadaver courses all around the world.

We suggest that use of pilates mats can be cheap and easy way to get first experience about dermal fillers for dermatology and plastic surgery residents and medical students. The use of ultrasound gel allows to feel the viscosity of the filling during injection. Pilates mats have similar resistance to injection of gel as human dermal and subcutaneous tissue.

**Keywords:** dermal filler, education, pilates mats, ultrasound gel

**Figure 1**



*The materials are needed for training*

**Figure 2**



*Practice on pilates mat*





# 4<sup>th</sup> INDERCOS

## Dermatology and Cosmetology Congress with International Participants

27 - 30 MARCH, 2019  
HILTON ISTANBUL BOSPHORUS HOTEL  
ISTANBUL, TURKEY



### OP-52

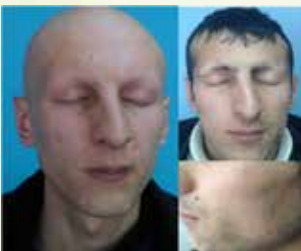#### REGRESSION OF VITILIGO LESIONS AFTER DPCP TREATMENT IN ALOPECIA AREATA

Handan Bilen, Mehmet Melikoğlu, Sevki Ozdemir, Erdal Pala  
Department of Dermatology, Ataturk University, Erzurum, Turkey

Alopecia areata (AA) and vitiligo are common, disfiguring autoimmune diseases of the skin. AA exhibits non-cicatricial patchy hair loss. Vitiligo manifests as white patches on the skin. The chronic relapsing nature of both diseases and their profound effect on physical appearance make the development of this condition a distressing and life-changing event for many affected individuals. AA severity ranges from small patches of alopecia, to complete loss of scalp hair (alopecia totalis), and/or remaining body hair (alopecia universalis). Topical immunotherapy with diphenylcyclopropenone (DPCP) is one of the treatment modality of AA. The exact mechanism of DPCP has not been clearly defined, but it may include antigenic competition and decreased production of anti-hair-follicle antibodies via different T-cell subpopulation to the treated area, which enhances the clearance of the follicular antigen. Side effects of DPCP include local eczema with blistering, regional lymphadenopathy, contact urticaria and rarely hyperpigmentation, hypopigmentation, and vitiligo. A 23-year-old male patient had vitiligo plaques in different parts of his body for about 9 years. He denied alopecia areata on his scalp, after a stressful event about 3 years ago. Areas of alopecia gradually turned to alopecia universalis in the last 7 months. He had been treated many times with corticosteroids (topical, intralesional, and systemic). He stated that when the treatment was discontinued, he gradually lost his hair again. The patient has familial history for AA. Laboratory tests, including complete blood count and biochemical, thyroid auto-antibodies, ANA, thyroid function tests, and other hormonal studies were normal. The dermatological exam showed any hair on his body, scalp and eyebrows. There were vitiligo patches on his cheek, axilla and presternal area. The patient had been started on topical immunotherapy with DPCP. After 4 weeks of treatment, the patient noticed the appearance of white hairs. 5 months later there was complete recovery of the AA. 7 months later vitiligo lesions disappeared spontaneously (Figure 1). We want to present our patient with AA, who was observed to have regressed vitiligo plaques when treated with DPCP, in contrast to literature about the development of vitiligo after DPCP treatment.

**Keywords:** alopecia areata, diphenylcyclopropenone, vitiligo, regression

**Figure 1**



*Spontaneous regression of vitiligo plaques on cheek with re-growth of hairs and eyebrows after DPCP treatment*



# 4<sup>th</sup> INDERCOS

## Dermatology and Cosmetology Congress with International Participants

27 - 30 MARCH, 2019  
HILTON ISTANBUL BOSPHORUS HOTEL  
ISTANBUL, TURKEY



### OP-53

#### THE EFFECTIVENESS OF TWO ORIGINAL LIQUID CRYSTAL FORMULATION WITH RETINOL IN RANDOMIZED PARALLEL CONTROL TRIAL

*Malwina Zasada, Elzbieta Budzisz*

*Department of Cosmetic Raw Materials Chemistry, Medical University of Lodz, Lodz, Poland*

**INTRODUCTION:** Retinol exfoliates the stratum corneum, accelerates the turn-over of epidermal cells, supports cell renewal in the basal layer of the epidermis as well as reduces the number of atypical cells. What is more, it inhibits the transport of melanin to the epidermal cells and affects the even distribution of the dye in the epidermis.

**OBJECTIVE:** We sought to evaluate the efficiency and tolerability of treating signs of aging skin like wrinkles, hyperpigmentations and uneven surface of the skin using a 0.15% and 0.3% retinol in original liquid crystal formulation.

**MATERIALS & METHODS:** Patients at 2 sites (n=20, n=20) applied a novel formulation of retinol respectively 0.15% on the left and 0.3% on the right, daily to their faces for 2 months. Expert blind evaluation of images (VAS, visual analogue scale) occurred at week 4 and week 8. Previously the assessment of original prepared formulation as lipid and lamellar was done (n=30). Tolerability was assessed throughout the study. Positive results of the observed pilot study warranted a follow-up study on the higher concentration and other parallel study. Moreover, it was approved by the Bioethics Committee RESULTS: Most participants showed improvement in overall skin condition, which were graded at week 4 and week 8. Improvements at 56 days were comparable on the left and right side. CONCLUSION: The pilot study was crucial to evaluate the effects of two different concentrations in one original formulation to check if concentration in cosmetic products with retinol indicates visible changes in treatment. By the examinations, we tried to assess if it is possible to conclude that concentration means less than effective cosmetic formulation.

**Keywords:** retinol, liquid crystal formulation, in vivo, anti-aging, VAS, cosmetic formulations

**The VAS (Visual Analogue Scale). Average results of the skin parameters evaluated after 8-weeks of the study, p<0.05.**

Parameter	Left side N=20	Right side N=20	Statistical significance U-Mann Whitney test	Statistical significance t-test
Even of the skin color	39.1±9.0	37.6±11.8	NS (P=0.606)	NS (P=0.671)
Reducing the intensity of discoloration	37.4±15.1	39.6±13.6	NS (P=0.515)	NS (P=0.636)
Improving the condition of the skin	30.2±8.2	31.0±8.8	NS (P=0.765)	NS (P=0.759)
Even the skin surface	38.5±11.9	41.7±9.9	NS (P=0.408)	NS (P=0.366)
Reducing in the number of facial wrinkles	29.1±9.5	32.2±9.2	NS (P=0.308)	NS (P=0.304)

POSTER  
PRESENTATIONS





# 4<sup>th</sup> INDERCOS

## Dermatology and Cosmetology Congress with International Participants

27 - 30 MARCH, 2019  
HILTON ISTANBUL BOSPHORUS HOTEL  
ISTANBUL, TURKEY



### PP-01

#### **BIER SPOTS ON THE FACE: A RARE ENTITY**

*Betul Macit, Sema Aytekin, Sirin Yasar*

*Department of Dermatology, Haydarpasa Numune Training and Research Hospital, Istanbul, Turkey*

Bier spots are asymptomatic, irregular, hypopigmented macules against a background of diffuse erythema, usually found on the arms and legs. We describe the presence of Bier spots on the face. This finding is unusual since, to our knowledge, this is the second case report that presented on the face in the literature.

**Keywords:** bier spots, dermoscopy, etiology

### PP-02

#### **PARTICULARITIES OF ERYTHEMA NODOSUM IN TUNISIA: A DESCRIPTIVE STUDY**

*Amel Rezgui, Wafa Baya, Jihed Anoun, Monia Karmani, Fatma Ben Fredj, Chedia Laouani*

*Internal Medicine Departement, CHU Sahloul, Sousse, Tunisia*

**INTRODUCTION:** Erythema nodosum, a painful disorder of the subcutaneous fat, is the most common type of panniculitis. It may be the first sign of a several diseases. The diagnosis is based on symptoms. We aim to study the features, common causes and treatment of Erythema nodosum

**PATIENTS AND METHODS:** It's a descriptive and retrospective study of clinical and paraclinical features and therapy approach of cases of erythema nodosum seen in the internal medicine department of Sahloul's university Hospital (Tunisia) over a period of 10 years.

**RESULTS:** A total of 95 patients were included in these analyses, with a mean age of 40 years (16-78) and a male-to-female ratio of 1:8. There was a history of erythema nodosum in 26% of cases. The nodules occurred most over on the legs symmetrically (96%). The most common associated symptoms were joint pain (65%) and fever (29%). The triggers of erythema nodosum in this study included streptococcal infection (n=40), medicines (n=11), Behçet's disease (n=7), Sarcoidosis (n=5), tuberculosis (n=5) and pregnancy (n=2). Erythema nodosum was idiopathic in 28% of cases. Under bed rest, anti-inflammatory drugs and treatment of underlying condition, the nodules resolved in an average of 32 days. Recurrences had occurred in 21.4% of cases in a delay of 7 months.

**DISCUSSION:** Causes of erythema nodosum are variable from a country to another. In Tunisia the most common cause is streptococcal infection, while tuberculosis is becoming less frequent.

**Keywords:** erythema nodosum, diagnosis, etiologies, treatment





# 4<sup>th</sup> INDERCOS

## Dermatology and Cosmetology Congress with International Participants

27 - 30 MARCH, 2019  
HILTON ISTANBUL BOSPHORUS HOTEL  
ISTANBUL, TURKEY



### PP-03

#### **SYSTEMIC LUPUS, LOFGREN SYNDROME AND AMYLOIDOSIS**

*Amel Rezgui, Wafa Baya, Jihed Anoun, Monia Karmani, Fatma Ben Fredj, Chedia Laouani  
Internal Medicine Departement, CHU Sahloul, Sousse, Tunisia*

The occurrence Amyloidosis is currently considered exceptional in the course of systemic lupus erythematosus. We report a case of a concomitant SLE and Amyloidosis in a 57 year old female patient with hypothyroidism history, who presented with erythema nodosum, fever, arthralgia and sicca syndrome. Biological findings showed an inflammatory syndrome, renal failure, proteinuria (1g / 24h), positive auto antibodies and anti DNA. Lung radiology revealed medistinal lymphadenopathy, pleural nodules, ground glass infiltrates and pleuritis.

Bronchial biopsy showed non specific inflammation. The salivary gland biopsy showed amyloid deposits. This case report reminds us that lupus and Amyloidosis association, although exceptional remains possible. The occurrence of Lofgren syndrome in this situation make the originality of this report.

**Keywords:** lupus, sarcoidosis, amyloidosis

### PP-04

#### **ATYPICAL LICHEN NITIDUS: A CASE PRESENTATION**

*Zeynep Gizem Kaya Islamoğlu, Abdullah Demirbaş  
Department of Dermatology, Faculty of Medicine, Selcuk University, Konya, Turkey*

**INTRODUCTION:** Lichen nitidus is a rarely seen chronic papulosquamos disease that is seen in genital region, abdomen, chest and extremities, characterized with skin colored papuls. The various clinical variants of lichen nitidus are linear, vesicular, hemorrhagic, spinous follicular, perforan, generalized, palmar and plantar type. The pathogenesis of lichen nitidus is unknown. It is usually healed with postinflammatory hypopigmented or hyperpigmented macules.

**CASE PRESENTATION:** A 7-year-old girl patient was admitted to our clinic with a complaint of skin rash on the front of her right thigh for 2 years. Her dermatologic examination showed bright patches of papules in skin color on the anterior surface of her right thigh. Other dermatological examination was normal. Lichen nitidus was diagnosed clinically and histopathologically,

**CONCLUSION:** Lichen nitidus is a slow-progressive, healing-prone disease and remissions can be seen frequently. Our case is presented because of the rarity of lichen nitidus and its atypical clinical appearance.

**Keywords:** lichen nitidus, atipic, papuloskuamous diseases, postinflammatory.





# 4<sup>th</sup> INDERCOS

## Dermatology and Cosmetology Congress with International Participants

27 - 30 MARCH, 2019  
HILTON ISTANBUL BOSPHORUS HOTEL  
ISTANBUL, TURKEY



PP-05

### ANTIBACTERIAL POTENTIALS OF BIOLOGICALLY SYNTHESIZED COLLOIDAL SILVER NANOPARTICLES FOR A CREAM FORMULATION: AN EFFECTIVE DERMATOLOGICAL APPLICATION

*Saeed Jafarirad, Behzad Taghizadeh, Vartan Simmonds  
Department of Phytochemistry and Biophysics*

**INTRODUCTION:** Nano-cosmeceuticals are potentially fruitful field of nanotechnology in personal care industries. Silver nanoparticles (AgNps) are inorganic nanostructures that are self-cleansing with sever antibacterial properties. Herein, usage of colloidal AgNps as effective bio-nanostructure for a topical cream formulation in respect of dermatological significance is investigated.

**MATERIALS & METHODS:** AgNps were biologically fabricated using environmentally benign *Matricaria Chamomil* extract under microwave irradiation. Then, AgNps were characterized by UV-Vis absorption spectroscopy, Fourier transform infrared spectroscopy (FTIR), X-ray diffraction (XRD), dynamic light scattering (DLS), scanning electron microscopy (SEM) and energy-dispersive X-ray spectroscopy (EDX).

**RESULTS:** The results reveal that the as-synthesized AgNps show an absorption peak at 435 nm. XRD and SEM analyses confirm the face-centered cubic structure of AgNps with roughly spherical in shape and particle size in the range between 35 nm to 40 nm. Elemental analysis by EDX proved the presence of Ag. Surface potential of  $-38.0$  mV confirmed the stability of AgNps. Antibacterial activity against *L.monocytogenes*, *L.monocytogens* and *E.coil* were investigated. Eventually, a cream containing as-synthesized AgNps was produced.

**CONCLUSIONS:** The appearance of nanostructures has offered a novel therapeutic modality to AgNps in treatment of wounds. However, the antibacterial properties of these AgNps in the process of wound healing are yet to be revealed. In the present study we focused on the antibacterial potency of AgNps during in vitro wound healing process. Consequently, this study supported the incorporation of as-synthesized AgNps as ingredient in a cream formulation for therapeutic goals. The obtained data proved that the exploitation of AgNps as promising tools in dermatological field of applications that can significantly alleviate human skin infections in treatment of wounds.

**Keywords:** Nano-cosmeceuticals, *Matricaria Chamomil*, Ag nanoparticles, Dermatological application

**Table 1**

Bacterial strain	Bacteria gram	Inhibition zone (mm) 1000 mg/ml	Inhibition zone (mm) 500 mg/ml
<i>Bacillus pumilus</i>	+	13	8
<i>Escherichia coli</i>	-	7	3
<i>Erwinia amylovora</i>	-	4	2
<i>Pectobacterium carotovorum</i>	-	5	3

*Inhibition zone (mm) of different concentrations against four pathogenic bacteria using disk diffusion method.*



# 4<sup>th</sup> INDERCOS

## Dermatology and Cosmetology Congress with International Participants

27 - 30 MARCH, 2019  
HILTON ISTANBUL BOSPHORUS HOTEL  
ISTANBUL, TURKEY



### PP-06

#### TREATMENT RESISTANT PITYRIASIS VERSICOLOR WITH POLYCYSTIC OVARY SYNDROME: A CASE REPORT AND REVIEW OF LITERATURE

*Zeynep Gizem Kaya İslamoğlu, Mehmet Akyürek, Mehmet Unal*

*Selçuk University, Department of Dermatology, Faculty of Medicine, Konya, Turkey*

**INTRODUCTION:** Pityriasis versicolor is a common superficial fungal infection of the skin. It is more common in the warmer months and tropical climates and most commonly seen in adolescents and young adults. Malassezia yeasts are the type of fungi that cause pityriasis versicolor and they normally live on the skin. It commonly appears on lipid-rich areas of the body. Polycystic ovary syndrome (PCOS) is a disease that characterized by hyperandrogenism, infertility, chronic anovulation and insulin resistance. PCOS usually seen in young women of childbearing age. It causes skin problems such as acne, hirsutism, acanthosis nigricans, androgenetic alopecia. The association of pityriasis versicolor and PCOS has not been published in the literature. Here, we aimed to present this union in our case.

**CASE PRESENTATION:** A seventeen year old female patient had PCOS. She presented with complaint of brown patches on the back, chest, and sacrum for about 7 years. She had not pruritus, erythema and pain. She had received antifungal treatments with these complaints. Lesions were squamous. gave greenish yellow fluorescence on wood light examination. We scraped a small portion of skin from an affected area for examination with a microscope and saw hyphae and spores together. This view resembled spaghetti and meatballs. Biopsy was performed to make differential diagnosis with mycosis fungoides. Mushroom spores and hyphae were observed in histopathological examination. As a result of these examinations, the patient was diagnosed with pityriasis versicolor. We gave ketoconazole shampoo and topical terbinafine treatment for 4 weeks. The patient did not respond to these treatments. And then we gave topical sertaconazol and oral itraconazole. The patient is resistant to this treatment, too. Lastly, topical naftifine and systemic terbinafine was given. She benefited from this treatment in 4 weeks follow-up.

**DISCUSSION:** Pityriasis versicolor is a mild, superficial infection of keratinous skin. It presents hyperpigmented or hypopigmented macule or patch. The clinical appearance of pityriasis versicolor and the presence of the fungus in the native preparation is sufficient for diagnosis. Histopathologic examination is rarely required. Topical and systemic antifungal, selenium sulfide shampoo, topical isotretinoin and phototherapy can be used in the treatment.

PCOS affects 2% to 7% of women in the general population. these criteria require at least 2 of the following findings for diagnosis: oligoanovulation, polycystic ovaries on transvaginal ultrasonography, and clinical signs or biochemical evidence of hyperandrogenism (HA).

**CONCLUSION:** In addition, severe pityriasis versicolor may be seen in patients with PCOS. We have detected resistance to pityriasis versicolor treatment in patients with PCOS. We believe that this information will contribute to the literature.

**Keywords:** Pityriasis versicolor, PCOS, female



# 4<sup>th</sup> INDERCOS

## Dermatology and Cosmetology Congress with International Participants

27 - 30 MARCH, 2019  
HILTON ISTANBUL BOSPHORUS HOTEL  
ISTANBUL, TURKEY



### PP-07

#### ORAL LICHEN PLANUS TREATED WITH LASER

*Kagan Cingoz, Işıl Inanir, Fatmagül Gulbasaran, Gülsüm Gencoglan*

*Department of Dermatology and Venereology, Manisa Celal Bayar University, Manisa, Turkey*

**INTRODUCTION & OBJECTIVES:** Lichen planus is a relatively common, chronic inflammatory mucocutaneous disease with unknown etiology. Oral lichen planus may occur alone or in combination with skin lesions. This chronic inflammatory disease is most commonly seen in the buccal mucosa and is usually bilateral and symmetrical. Topical and intralesional corticosteroids, topical cyclosporin-A and systemic therapies can be used for treatment. Laser treatment has recently been proposed as a treatment without significant side effects.

**CASE REPORT:** A 56-year-old female patient was admitted to our clinic because of burning in the mouth. Dermatological examination revealed hyperkeratotic white plaque with a size of 4x2 cm in both buccal mucosa. Histopathological findings were interpreted in favor of oral lichen planus in biopsy sampling. The patient was offered topical corticosteroid cream for 2 months due to the absence of involvement of the oral mucosa. At the end of the treatment, no change was made and the treatment with azathioprine 100mg / day and acitretin 25mg / day was started. After 2 months of treatment, no clinical regression was applied and local anesthesia was applied to both buccal plaques at 10800nm wavelength CO2 laser 12W 0.50ms, with a 2 ms delay. Nearly regression was detected in the patient's complaints and clinically.

**RESULTS:** The fact that oral lichen planus is resistant to conventional therapies and that topical therapies can not be used effectively in this region due to washing effect of oral secretions and that the use of systemic therapies for such a limited area creates anxiety in terms of physician creates difficulties in treatment. In the literature, the treatment of oral lichen planus with CO2 laser has been reported in a small number of cases. We did not start any systemic antibiotics and no infection was observed. Without requiring sutures or dressings, the site of treatment showed secondary improvement and no function limiting scar formation was observed. After laser treatment, we did not find any evidence of cobnerization in our case.

**CONCLUSIONS:** The use of laser in oral lesions, which is an easy and fast application, seems to be cost-effective and reliable. A larger number of cases and study results are needed.

**Keywords:** laser, lichen planus, oral



# 4<sup>th</sup> INDERCOS

## Dermatology and Cosmetology Congress with International Participants

27 - 30 MARCH, 2019  
HILTON ISTANBUL BOSPHORUS HOTEL  
ISTANBUL, TURKEY



### PP-08

#### GRANULOMA FACIALE: A RARE DISEASE

*Ece Uğurer<sup>1</sup>, Ezgi Özkur<sup>1</sup>, Ilknur Kıvanç Altunay<sup>1</sup>, Cem Leblebici<sup>2</sup>*

*<sup>1</sup>Department of Dermatology, Health Sciences University Şişli Hamidiye Etfal Training and Research Hospital, Istanbul, Turkey*

*<sup>2</sup>Department of Pathology, Health Sciences University Istanbul Training and Research Hospital, Istanbul, Turkey*

Granuloma faciale is an uncommon benign chronic inflammatory dermatosis characterized by asymptomatic reddish-brown to violaceous papules, plaques or nodules. The most common site for granuloma faciale is the face. The pathogenesis of granuloma faciale remains unclear, and it is frequently unresponsive to therapy. A 67 year old female patient presented to our clinic with a history of an asymptomatic erythematous-violaceous papules over the face. The lesion started as a painless reddish papule on the nose that slowly enlarged and spread to right cheek over a 6 months period. She had a history of chronic obstructive lung disease, hypertension. She was on medication with theophylline and calcium channel blockers for chronic obstructive lung disease, hypertension respectively. On dermatological examination there were well defined, indurated, erythematous-violaceous papules measuring 2x2 cm over the tip of the nose and 1x1 cm on the right cheek. Her physical examination was otherwise unremarkable. There was no abnormality in the blood examination. A 4 mm punch biopsy was performed from lesion localised on nose and the histopathology revealed with presence of Grenz zone, diffuse polymorphous, inflammatory infiltrate involving the upper half of the dermis. The inflammatory infiltrate consisted of eosinophils, plasma cells, neutrophils, histiocytes and lymphocytes. There was also minimal fibrinoid necrosis within vessel wall, nuclear debris (leukocytoclasia), endothelial cell swelling. Patient was diagnosed as granuloma faciale with this clinical and histopathological findings. For treatment, intralesional triamcinolone (2.5 mg/ml) performed and also topical tacrolimus 0,1% ointment twice daily were administered. At one month follow up, no further increase in size and slow regression of lesions were observed.

**Keywords:** granuloma faciale, rare, tacrolimus





# 4<sup>th</sup> INDERCOS

## Dermatology and Cosmetology Congress with International Participants

27 - 30 MARCH, 2019  
HILTON ISTANBUL BOSPHORUS HOTEL  
ISTANBUL, TURKEY



### PP-09

#### MORPHEA LICHEN SCLEROSUS OVERLAP IN A PATIENT WITH CONGENITAL DEAFNESS

*Kıymet Handan Keleşçi<sup>1</sup>, Ali Karakuzu<sup>1</sup>, İlgin Aydın<sup>2</sup>*

<sup>1</sup>Department of Dermatology, İzmir Katip Çelebi University and Atatürk Training and Reseaching Hospital, İzmir, Turkey

<sup>2</sup>Department of Pathology, İzmir Katip Çelebi University and Atatürk Training and Reseaching Hospital, İzmir, Turkey

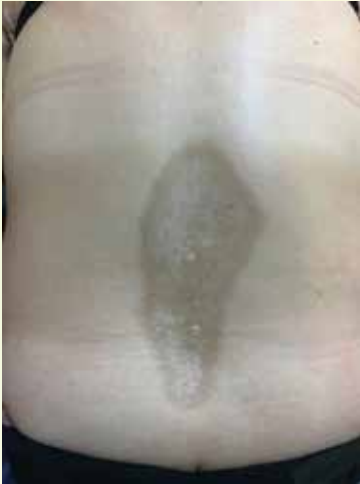**INTRODUCTION:** Morphea is a disease characterized by well-defined plaques with violaceous borders and skin induration. Lichen sclerosus a chronic disease of the skin and mucosa that predominantly affects the genital areas and presents with white shiny papules and plaques with prominent atrophy and telangiectasia. Challenges can occur when trying to distinguish the two conditions histopathologically and clinically. Recently, cases of lichen sclerosus occurring in conjunction with morphea are well documented. However, there have been only a few reports of these two conditions occurring in the same skin lesion. This also shows that that the two conditions may belong to the same disease process. We report a case with overlapping features of both morphea and lichen sclerosus occurring in the same lesion in a patient with congenital deafness.

**CASE:** A 60-year-old female patient complained of whitening on her breast and darkening of waist area of the back and pruritus. Her complain has begun itching and pain whitening on the skin for 3 years ago. Later, the white spot in the waist area of the back was thickened and there was whiteness in the middle. There was hypertension and cholesterol elevation in the history of the patient except congenital deafness. There were implant surgery for deafness and surgical menopause stories. On dermatological examination revealed sclerotic patch on both breasts and white shiny lesions having a peripheral indurated hyperpigmentation lesion in the posterior lumbar region(Figure1,2). Routine examinations were normal except for high cholesterol levels. ANA examination was negative. Punch skin biopsy specimen revealed ortho-hyperkeratosis in epidermis, thinning and vacuole change in basal membran. In the dermis there is perivascular mild density lymphoplasmoid cell infiltration, papillary paleness (mild edema) and infrequent melanophage. Dermal collagen is accompanied by coarsening and hemogenization. Ecrin glands are relatively high level. Some of the biopsy findings were morphea and some of them were compatible with lichen sclerosus. The patient had previously received intralesional steroid, topical steroid, topical calsipotriol treatment with methotrexate treatment for short-term 10mg / week until narrowband UV-B treatment for up to 3 months. The patient discontinued the treatment because he did not get enough benefit from the treatments.

**CONCLUSION:** This article detects rare and interesting case of concomitant morphea and LSA in a in the same plaque 60-year-old female with congenital deafness. The fact that these two diseases can be transformed to each other or if they have different spectrum can be clarified by new researches on this subject.

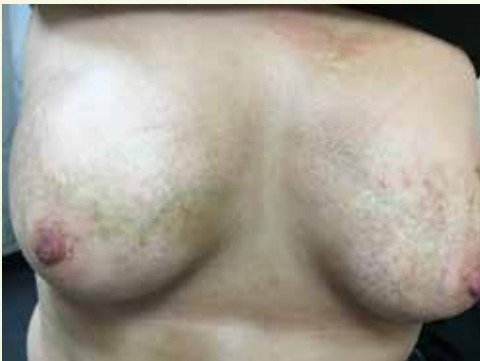**Keywords:** Lichen sclerosus, Morphea, congenital deafness

**Figure 1**



*White shiny lesions and keratotic follicular plugs in the middle of the hyperpigmented indurated lesion in the posterior lumbar region.*

**Figure 2**



*Sclerotic patch having a peripheral hyperpigmentation on both breasts*



# 4<sup>th</sup> INDERCOS

## Dermatology and Cosmetology Congress with International Participants

27 - 30 MARCH, 2019  
HILTON ISTANBUL BOSPHORUS HOTEL  
ISTANBUL, TURKEY



### PP-10

#### **INFLIXIMAB EXPERIENCE IN BEHCET'S DISEASE ASSOCIATED WITH HYDRADENITIS SUPURATIVA: A CASE REPORT**

*Zeynep Gizem Kaya İslamođlu, Abdullah Demirbař, Mehmet Unal, Gzde Ulutař Demirbař  
Seluk University, Department of Dermatology, Faculty of Medicine, Konya, Turkey*

**INTRODUCTION:** Hydradenitis suppurativa is a chronic, recurrent inflammatory disease affecting the subcutaneous follicles in the inguinal, under breasts, perineum and perianal regions. It may be associated with superficial papulopustular lesions and may lead to deep abscesses, sinus tracts and scars.

**CASE:** A 34-year-old male patient was admitted to our clinic with complaints of wounds in both underarms and groin regions for 6 years. The patient's dermatological examination revealed painful, erythematous, suppurative nodules in both axillae and inguinal areas. The patient was treated with systemic, topical antibiotic and systemic isotretinoin but did not benefit. The patient was also suffering from Behet's disease and taking Prednisolone, Salisilazosulfapiridine, Aspirin and Colchicine. Infliximab treatment was planned for the patient who was resistant to topical and systemic therapies. Hemogram, wide biochemistry, PPD and chest X-ray were performed. Despite chest x-ray being normal, PPD test was found 15 mm and depending on that isoniazid treatment was started one month before infliximab treatment for latent tuberculosis. Infliximab treatment was given as 5 mg / kg at 0, 2 and 6 weeks and then one dose infusion at 8 weeks. No obvious adverse effects were observed after the second infusion. In addition, mucocutaneous findings and joint pain due to Behet's disease also declined.

**DISCUSSION:** We present this case to emphasize that infliximab treatment may be an effective alternative option for treatment-resistant hydradenitis suppurative cases and may also be included in the treatment of Behet's disease.

**Keywords:** Hydradenitis suppurativa, Behcet's disease, Infliximab



# 4<sup>th</sup> INDERCOS

## Dermatology and Cosmetology Congress with International Participants

27 - 30 MARCH, 2019  
HILTON ISTANBUL BOSPHORUS HOTEL  
ISTANBUL, TURKEY



### PP-11

#### **BROOKE SPIEGLER SYNDROME: A CASE REPORT**

*Kıymet Handan Kelekçi<sup>1</sup>, Beste Nigar Gök<sup>1</sup>, Ali Karakuzu<sup>1</sup>, Aslı Kahraman Akkalp<sup>2</sup>*

<sup>1</sup>*Department of Dermatology, İzmir Katip Çelebi University and Atatürk Training and Reseaching Hospital, İzmir, Turkey*

<sup>2</sup>*Department of Pathology, İzmir Katip Çelebi University and Atatürk Training and Reseaching Hospital, İzmir, Turkey*

**INTRODUCTION:** Brooke-Spiegler syndrome(BSS)is an inherited autosomal dominant disease characterized by the development of multiple adnexal cutaneous neoplasms including spiradenoma, cylindroma, spiradenocylindroma, and trichoepithelioma. BSS was reported for the first time in 1842 by Ansell. Described in 1892 and 1899 by Brooke and Spiegler. The patients typically present in late childhood and early adolescence. BSS is an inherited predisposition syndrome presenting with multiple adnexal cutaneous neoplasms including spiradenoma, cylindroma, spiradenocylindroma, and trichoepithelioma. Very few cases of BSS are reported in the literature. We report this case because of its rarity.

**CASE:** We report a case of 44-year-old female who presented to our department with the clinical complaint of multiple papulonodular lesions on the her face and scalp since the adolescent. Her father and uncle had similar lesions on their face. She came for cosmetic concerns. On dermatologic examination showed multiple papul and nodular lesions on face and scalp. The average size was 0.5 cm(Figure 1).Rutin blood examination normal. The biopsy from the jaw region of the patient is consistent with trichoepithelioma. Also two the largest lesion was excised on scalp and was sent to histopathology department. These specimens were diagnosed BSS syndrome. Also the excisional biopsy was taken from around the eyebrow. The histological feature suggestive of eccrine cylindroma. Thus the diagnosis of collision tumor was made and possibility of Brooke-Spiegler syndrome was suggested on the basis of history and histopathological examination. The patient was followed in terms of malignant cylindroma formation development.

**CONCLUSION:** Very few cases of BSS are reported in the literature. Close clinical follow-up is warranted to identify these changes. BSS is a devastating condition with no widely accepted standard of treatment. Close follow-up is essential to monitor for malignant transformation.

**Keywords:** Brooke-Spiegler syndrome, trichoepithelioma, eccrine cylindroma





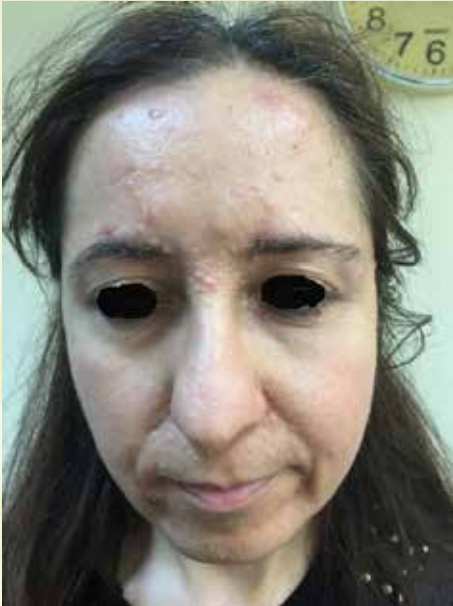# 4<sup>th</sup> INDERCOs

Dermatology and Cosmetology Congress  
with International Participants

27 - 30 MARCH, 2019  
HILTON ISTANBUL BOSPHORUS HOTEL  
ISTANBUL, TURKEY



**Figure 1**



*Multiple papulonodular lesions on the her face and scalp.*



# 4<sup>th</sup> INDERCOS

## Dermatology and Cosmetology Congress with International Participants

27 - 30 MARCH, 2019  
HILTON ISTANBUL BOSPHORUS HOTEL  
ISTANBUL, TURKEY



### PP-12

#### CONTRIBUTION OF DERMOSCOPY IN THE DIAGNOSIS OF ONYCHOMYCOSIS

*Myriam Bouchekoua<sup>1</sup>, Sabine Bouhleb<sup>1</sup>, Nouredine Litaïem<sup>2</sup>, Dorsaf Aloui<sup>1</sup>, Sarra Cheikhrouhou<sup>1</sup>, Sonia Trabelsi<sup>1</sup>, Faten Zeghlaoui<sup>1</sup>, Samira Khaled<sup>1</sup>*

<sup>1</sup>Laboratory of Parasitology-Mycology, Charles Nicolle Hospital, Tunis, Tunisia

<sup>2</sup>Department of Dermatology, Charles Nicolle Hospital, Tunis, Tunisia

**INTRODUCTION & OBJECTIVES:** Onychomycosis is the most common nail disease representing up to 50% of all onychopathies. Mycological examination is still the cornerstone for the diagnosis. Dermoscopy is nowadays used by many dermatologists to facilitate the diagnosis of onychomycosis. The aim of this study was to describe the dermoscopic findings in onychomycosis and to search a link between mycological and dermoscopic features.

**MATERIALS & METHODS:** A cross-sectional study was conducted in the Parasitology-Mycology Laboratory of Charles Nicolle Hospital in collaboration with the Dermatology Department of the same hospital over a period of four months (March - July 2016). It included 148 patients with onychomycosis. The diagnosis was based on mycological exams of nails (confirmed by the positivity of direct examination and/or culture of samples). A dermoscopy was performed when it was available for the dermatologist.

**RESULTS:** Thirty-six patients have benefited from a dermoscopy. Polarized and non-polarized dermoscopy were performed respectively in 25 and 11 patients. The age range of the 36 patients was between 22 and 82 years (mean age was  $48.36 \pm 16.43$  years). Their sex ratio was 0.56. Toenail onychomycosis was recognized in 31 cases, fingernail onychomycosis in 2 and both in 3 cases. Regarding direct examination and/or culture results, dermatophytes were the most incriminated (92%). *Trichophyton rubrum* was the most prevalent species isolated from patients (n=19) followed by *Candida albicans* (n=2) and *Trichophyton interdigitale* (n=1).

On dermoscopic examination, we found subungual keratosis (69%), distal subungual longitudinal striae (69%), 'Spikes' of the proximal margin of an onycholytic area (58%), transverse superficial leukonychia (22%), linear hemorrhage (14%) and chromonychia.

The presence of subungual keratosis was statistically significantly higher with dermatophytic onychomycosis (100%) compared with *Candida* onychomycosis (70%) ( $p=0.017$ ) and with *Trichophyton rubrum* compared to other species (94% versus 43%;  $p=0.012$ ). No correlation was found between the other dermoscopic features and the mycological results.

**CONCLUSION:** As onychomycosis is a frequent complaint, many dermatologists prescribe antifungal treatment without mycological confirmation as these tools usually take a long time to give results. Dermoscopy can be a helpful tool in the diagnosis of onychomycosis.

**Keywords:** onychomycosis, dermoscopy, mycological exam



# 4<sup>th</sup> INDERCOS

## Dermatology and Cosmetology Congress with International Participants

27 - 30 MARCH, 2019  
HILTON ISTANBUL BOSPHORUS HOTEL  
ISTANBUL, TURKEY



PP-13

### DERMATOMYCOSES OF CHILDREN: EPIDEMIOLOGICAL, CLINICAL AND MYCOLOGICAL PROFILE

*Myriam Bouchekoua, Taysir Saidane, Dorsaf Aloui, Sarra Cheikhrouhou, Sonia Trabelsi, Samira Khaled*  
*Laboratory of Parasitology-Myology, Charles Nicolle Hospital, Tunis, Tunisia*

**INTRODUCTION & OBJECTIVES:** Dermatormycoses are fungal infections of skin, hair or nails. In children, their clinical profile may have particular features. The aim of this study was to determine the epidemiological, clinical and mycological profile of these mycoses in children.

**MATERIALS & METHODS:** A cross-sectional study was carried out in parasitology and mycology laboratory of Charles Nicolle Hospital between 2010 and 2016. It concerned mycological samples taken from children under 16 years of age.

**RESULTS:** We collected 526 children referred to our laboratory for suspected dermatormycoses. The diagnosis was confirmed for 45% among them.

Tinea capitis represented the most prevalent form of dermatormycoses (50.6% among suspect lesions of scalp). Boys and children aged between 2 and 6 years were significantly more affected ( $p < 0.001$ ). Contact with animals and presence of similar case in family or school were significantly associated to tinea capitis. Microsporic tinea was the most prevalent (74.2%).

As for tinea corporis and skin candidiasis, their frequency was 35.1%. *Microsporum canis* (30.4%) and *Trichophyton rubrum* (26%) were the most frequent.

Pityriasis versicolor was confirmed in 26.9% of the cases. Children aged between 12 and 16 years were the most affected. Hypopigmented lesions were predominant.

Intertrigo of big skin folds were confirmed in 10 cases over 22 suspect lesions. Inter-glutter fold was the most commonly affected. *Candida albicans* was predominant. In regards to little folds, the mycological origin was confirmed for 11 patients over 19 with suspect lesions. Inter-toe fold was the most commonly affected. *Trichophyton rubrum* was predominant.

Frequency of onychomycosis in fingernails and toenails accounted respectively for 47.8% and 38.2%. Total onychodystrophy was the most frequent in both. *Candida albicans* was predominant in fingernail onychomycoses while *Trichophyton rubrum* was the major fungus of toenail onychomycoses.

**CONCLUSION:** Dermatormycoses are common in children. The major form is represented by tinea capitis, with zoophilic dermatophytes as causative agent. Mycological examination is necessary to confirm the diagnosis, guide the treatment and determine the origin of the infection in order to prevent the recurrence of the infection.

**Keywords:** children, dermatormycoses, mycological exam



# 4<sup>th</sup> INDERCOS

## Dermatology and Cosmetology Congress with International Participants

27 - 30 MARCH, 2019  
HILTON ISTANBUL BOSPHORUS HOTEL  
ISTANBUL, TURKEY



### PP-14

#### DERMATOLOGICAL FINDINGS IN A CASE WITH NLRP1 MUTATION

*Mert Baran, Kıymet Handan Keleşçi, Ali Karakuzu*

*Department of Dermatology, İzmir Katip Çelebi University and Atatürk Training and Researching Hospital, İzmir, Turkey*

**INTRODUCTION:** Inflammasomes are large multiprotein complexes that are key modulators of immune and inflammatory responses. Two different receptor forms of inflammasomes have been described: the NOD-like receptor (NLR) family of proteins such as NLRP1, NLRP3, NLRP6, NLRP12, NLRC4/IPAF; and the ALR-AIM2-like receptors, namely AIM-2. Members of the nucleotide-binding oligomerisation domain-like receptor (NLR) family are the major components of inflammasomes<sup>2</sup>. On infection, they play a critical role by sensing microbial structures called pathogen-associated molecular patterns or endogenous danger molecules released by stressed cells, damage-associated molecular patterns<sup>1</sup>. We report here a case who belong NLRP1 mutation with dermatological skin finding.

**CASE:** A 46-year-old male patient presented with over 40 years, hypo-hiperpigmented areas and acanthotic skin changes on chest, abdomen and extremities (Fig.1). Dermatological examination revealed xerosis, multipl skin tags on neck, poikiloderma and non-follicular papules. On his hand nails are normal but there are distal phalangeal enlargements and acral ulcers. On the right foot, he had rudimentary polydacty and bilateral subungual hyperkeratosis on nails (Fig.2-3). He had chronic bronchitis but no drug intake and arcus senilis on corneal layer. The rest of the physical examination and the routine biochemistry analysis was normal. Radiological examination revealed acro-osteolysis on hands, The histopathological evaluation was reported dermal amiloidosis, hyperkeratosis with papillomatosis and acanthosis. He had a consanguineous relationship between his parents and his sister had similar skin changes but no nail disorders. The patient was referred to the genetic department to investigate the genetic syndroms. The result of their investigation revealed us NLRP1 mutation. Because of lack of systemic findings, he followed up at regular intervals to observe skin changes.

**CONCLUSION:** Inflammasomopathies are rare disorders and appear to have a wide spectrum of phenotypes<sup>2</sup>. Our patient's skin disorders are compatible with these inflammasomopathies. To show the role of NLRP1 mutation on skin disorders, we need more cases.

**Keywords:** Inflammasomes, mutation, NLRP1





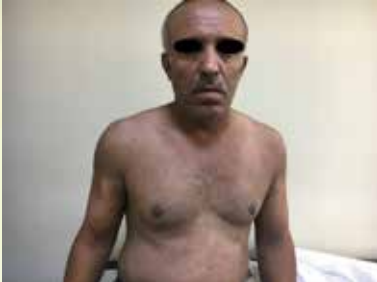# 4<sup>th</sup> INDERCOS

Dermatology and Cosmetology Congress  
with International Participants

27 - 30 MARCH, 2019  
HILTON ISTANBUL BOSPHORUS HOTEL  
ISTANBUL, TURKEY

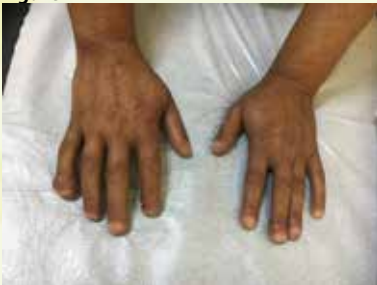

**Figure 1**



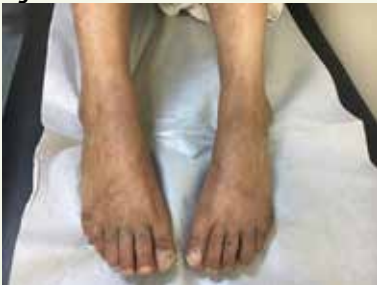*Hypopigmented and hiperpigmented areas and acanthotic skin changes on chest, abdomen and extremities.*

**Figure 2**



*Hyperkeratotic hyperpigmented lesions on the hands with clubbing finger nail.*

**Figure 3**



*On the right foot, he had rudimentary polydactyly and bilateral subungual hyperkeratosis on feet nails.*



# 4<sup>th</sup> INDERCOS

## Dermatology and Cosmetology Congress with International Participants

27 - 30 MARCH, 2019  
HILTON ISTANBUL BOSPHORUS HOTEL  
ISTANBUL, TURKEY



### PP-15

#### GRANULAR CELL TUMOR: AN UNUSUAL LOCALISATION

*Burak Yalcin<sup>1</sup>, Ezgi Ozkur<sup>2</sup>, Ilknur Kivanc Altunay<sup>3</sup>, Deniz Tunçel<sup>4</sup>*

<sup>1</sup>*Dr. Burak Yalçın*

<sup>2</sup>*Dr. Ezgi Ozkur*

<sup>3</sup>*Dr. Ilknur Kivanc Altunay*

<sup>4</sup>*Dr. Deniz Tunçel*

Granular cell tumor is a rare, mostly benign neoplasm, which mainly located on the skin and mucosa. Most commonly located in the head and neck region. First, this tumor was thought to be derived from striated muscles by Abrikossoff and was called as 'granular cell myoblastoma'. Recent ultrastructural studies showed that this tumor stained by S100 and neuron specific enolase (NSE), confirm that this tumor is derived from Schwann cells of the peripheral nerves.

A 48-year-old female patient admitted with the suddenly grew up and expanding mass on her left arm in 2 months. On her dermatological examination; 1.5x1.5 cm sized, dark brown colour nodule was detected. Tumor was hard and tender on palpation. Borders of the tumor were regular. On histopathological examination, increased pigmentation in the dermoepidermal junction, infiltrative development of trabeculae, pseudoepitheliomatous hyperplasia in the epidermis and granular cells in the dermis were detected. Immunohistochemical study showed widespread cytoplasmic staining with S100, staining with vascular structures with CD34, and staining with intracytoplasmic granules with PAS. The histopathological findings suggested a granular cell tumor.

Granular cell tumors are generally benign tumors with good prognosis. A tumor larger than 4 cm, the presence of ulceration, rapid growth and lymphadenopathies are the signs suggesting malign type of granular cell tumor and these features are not seen in our case. The clinical diagnosis of granular cell tumor is difficult and generally depends on the histopathological findings. We presented this case to emphasize atypical locations of granular tumor and also to remind differential diagnosis of benign skin tumors and importance of histopathological examination.

**Keywords:** Granular Cell Tumor, Atypic, Unusual Localisation



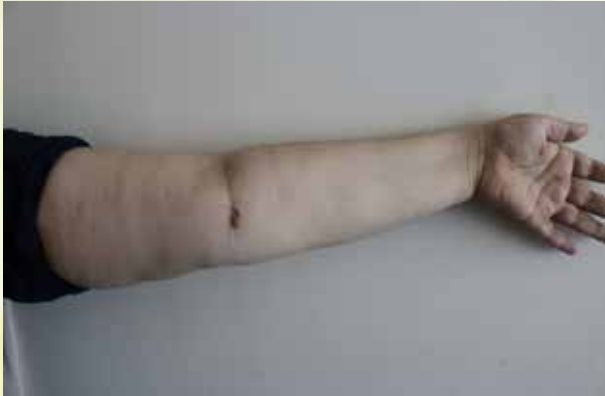# 4<sup>th</sup> INDERCOs

Dermatology and Cosmetology Congress  
with International Participants

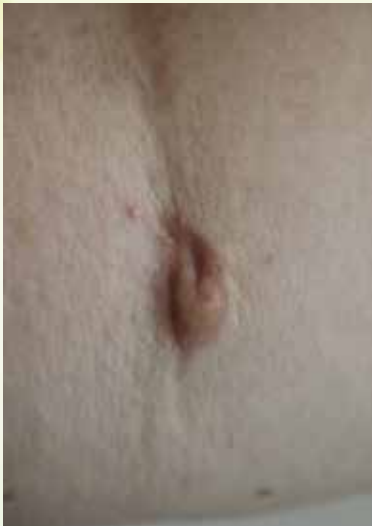27 - 30 MARCH, 2019  
HILTON ISTANBUL BOSPHORUS HOTEL  
ISTANBUL, TURKEY



**Picture-1**



**Picture-2**





# 4<sup>th</sup> INDERCOS

## Dermatology and Cosmetology Congress with International Participants

27 - 30 MARCH, 2019  
HILTON ISTANBUL BOSPHORUS HOTEL  
ISTANBUL, TURKEY



### PP-16

#### **SYMMETRICAL DRUG-RELATED INTERTRIGINOUS AND FLEXURAL EXANTHEMA IS A DISREGARDED SYNDROME: REPORT OF THREE CASES**

*Hazel Ezgi Kaya, Yasemin Erdem, Ilknur Altunay, Ezgi Özkur, Onur Sivaz*

*Dermatology Department, University of Health Sciences, Şişli Hamidiye Etfal Training and Research Hospital, Istanbul, Turkey*

In 1984, Andersen et al. proposed the term Baboon syndrome to describe a systemic contact dermatitis characterized by V-shaped exanthem of gluteal region with involvement of at least one flexural regions after the systemic exposure to contact allergens such as mercury, nickel or ampicillin in sensitized patients. This term renamed as SDRIFE (Symmetrical Drug-Related Intertriginous and Flexural Exanthema) by Hausemann et al. in 2004, because of the situation could be occurred via first exposure. SDRIFE is most commonly associated with  $\beta$ -lactams, particularly amoxicillin. The diagnostic criteria include: 1) history of recent drug intake, 2) sharply demarcated erythema of gluteal/perianal region or V-shaped erythema of the inner thighs, 3) involvement of at least one great flexure, 4) symmetry, 5) absence of organ involvement. The exact immune and pathophysiological mechanisms of SDRIFE have not yet been elucidated; it apparently corresponds to a type IV hypersensitivity immune response. Histopathological examination is nonspecific and shows a superficial perivascular mononuclear cell infiltration with some neutrophils and eosinophils. The postulated reasons for the flexural predilection are mainly due to high density of eccrine sweat glands in body folds where drug excretion precipitates the dermatosis. Since the first description of the syndrome, over 100 cases of SDRIFE was reported. Because of the self-limiting nature of syndrome, none systemic involvement, high incidence of over-the-counter medication usage habits and difficulties in the accessibility to a dermatologist we assumed that the true incidence of SDRIFE is higher than previously thought. Here we represent 3 cases attempted to our clinic and diagnosed as SDRIFE due to ibuprofen, nifuroxazide and ciprofloxacin usage in 1 year period.

**Keywords:** Symmetrical drug-related intertriginous and flexural exanthema, Systemic contact dermatitis, Drug Eruption





# 4<sup>th</sup> INDERCOS

## Dermatology and Cosmetology Congress with International Participants

27 - 30 MARCH, 2019  
HILTON ISTANBUL BOSPHORUS HOTEL  
ISTANBUL, TURKEY



**PP-17**

### **DELAYED DIAGNOSIS OF ANOGENITAL BCC: AN UNUSUAL PRESENTATION**

*Ömer Kutlu<sup>1</sup>, Fatma Nur Kutlu<sup>2</sup>, Yücel Tekin<sup>3</sup>*

*<sup>1</sup>Department of Dermatology and Venereology, Develi Hatice Muammer Kocatürk State Hospital*

*<sup>2</sup>Department of Dermatology and Venereology, Health Sciences University, Kayseri City Hospital*

*<sup>3</sup>Department of Pathology, Health Sciences University, Kayseri City Hospital*

**INTRODUCTION & OBJECTIVES:** Basal cell carcinoma (BCC) is the most common type of skin cancer. Although head and neck regions represent the most common site of BCC, any other site of the body could also be involved by the tumour. BCC existing on non-sun-exposed sites, especially the perianal and genital regions, is very rare. Herein, we reported delayed diagnosis of anogenital BCC.

**MATERIALS & METHODS:** A case report of an unusual presentation of the BCC was presented.

**CASE:** Sixty-two-year-old female patient presented with ulcerated lesion in the anogenital region. The lesion has appeared about 4 years ago progressively. The patient was admitted to the hospital several times due to her lesions. She had received to the combination of topical isoconazole nitrate and diflucortolone valerate, hamamelis virginica and certain drugs for fungal infection during this period. Although the sensation of intense itching arises from lesions decreased with these certain medications, the lesion has been progressively larger. Family history and physical examination of the patient was unremarkable. Dermatological examination revealed an ulcerated lesion diameter of 3.5 cm covered with white pseudomembrane in the inferior of the vulva (figure 1). Routine laboratory examinations including complete blood count, urinalysis, biochemical profile, VDRL, HIV and hepatitis serologies were all within normal limits. Histopathological examination revealed that basaloid epithelial tumour arising from the epidermis. The peripheral cell layer of the tumor plate shows palisading. Based on these clinic finding and histopathological tests final diagnosis of BCC was established. The patient underwent surgical excision of the tumor with four millimeters of peripheral margins.

**CONCLUSION:** Dermatologists should be aware of the unusual presentation of BCC. Therefore, the biopsy should be performed for the recalcitrant ulcerative lesion that involved in any part of the body, especially anogenital region to make the rapid and correct diagnosis. BCC should be considered for the differential diagnosis when a patient is presented with a persistent ulcer on the anogenital lesions.

**Keywords:** Anogenital region, basal cell carcinoma, delayed diagnosis



# 4<sup>th</sup> INDERCOs

Dermatology and Cosmetology Congress  
with International Participants

27 - 30 MARCH, 2019  
HILTON ISTANBUL BOSPHORUS HOTEL  
ISTANBUL, TURKEY



**Figure 1**



*An ulcerated lesion diameter of 3.5 cm covered with white pseudomembrane in the inferior of the vulva.*



# 4<sup>th</sup> Indercos

## Dermatology and Cosmetology Congress with International Participants

27 - 30 MARCH, 2019  
HILTON ISTANBUL BOSPHORUS HOTEL  
ISTANBUL, TURKEY



**PP-18**

### **SOLITARY KERATOACANTHOMA AFTER ALEXANDRITE LASER HAIR REMOVAL THERAPY**

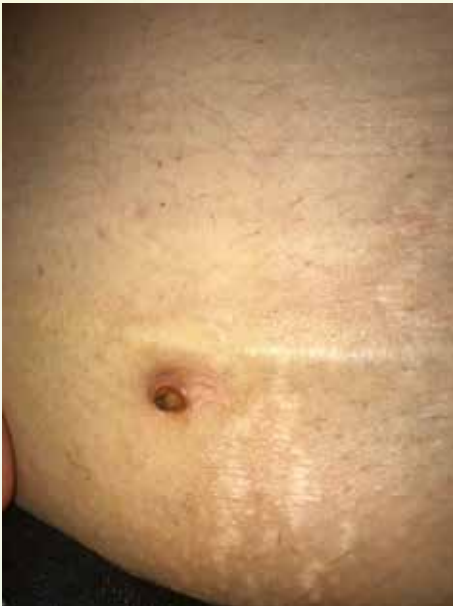*Nagihan Demirpençe, Özgür Gündüz*

*Department of Dermatology and Venereology, Kırıkkale University, Kırıkkale, Turkey*

Keratoacanthoma (KA) is a skin tumor characterized by rapid growth and spontaneous involution. KA typically manifests as an asymptomatic papule with central keratin plugging on sun-exposed skin and iatrogenic factors such as, phototherapy, cryotherapy, surgical procedures and ablative lasers are reported as its possible triggering factors. Since KA's usually tend to regress, surgical intervention is not mandatory. In case of persistent KAs or a clinical doubt of malignant transformation, they can be surgically removed. In this poster, we describe a female-patient who presented our clinic with a CA on her pubic area (Fig.1), after she underwent Alexandrite laser therapy for hair removal.

**Keywords:** keratoacanthoma, alexandrite, laser

**Figure 1.**



*Keratoacanthoma on her pubic area after she underwent Alexandrite laser therapy for hair removal.*



# 4<sup>th</sup> INDERCOS

## Dermatology and Cosmetology Congress with International Participants

27 - 30 MARCH, 2019  
HILTON ISTANBUL BOSPHORUS HOTEL  
ISTANBUL, TURKEY



### PP-19

#### CRYING LEG AFTER SKIN BIOPSY

Gülbahar Saraç<sup>1</sup>, İrem Mantar<sup>1</sup>, İsmail Okan Yıldırım<sup>2</sup>, Yelda Kapıcıoğlu<sup>3</sup>

<sup>1</sup>Department of Dermatology, İnönü University Faculty of Medicine, Malatya, Turkey

<sup>2</sup>Department of Radiology, İnönü University Faculty of Medicine, Malatya, Turkey

<sup>3</sup>Department of Dermatology, Liv Hospital, Istanbul, Turkey

Skin biopsy is a minimally invasive diagnostic method which we frequently use in our daily practice. Lymphocutaneous fistula is a complication especially after cardiovascular surgery. In the literature, we describe the first case of lymphocutaneous fistula after skin biopsy in a 14-year-old girl who was treated by lymphangiography. A 14-year-old girl was admitted to the hospital with a discharge complaint for three weeks in the area where she received a biopsy with the preliminary diagnosis of henoch schonlein purpura. In physical examination, in the left leg pretibial region there is a 3 mm erythematous scar through which a clear fluid. The patient's trousers were wet due to flowing fluid. Right after the region was dried with a sponge, it was observed that there was a new fluid formation on the lesion and it soaked into the leg (Figure 1). There was no reproduction in the fluid culture. A few lymphocytes were seen in the liquid gram stain. After ultrasonography, lymphangiography was performed on the patient by Interventional Radiology. It was demonstrated that the flow was associated to the lymphatic channels via contrast agent (lipiodol) by the percutaneous entry with ultrasound from scar region where the flow was (Figure 2). The lymphocutaneous fistula of the patient was embolized using 20% glue – Lipiodol® (ethiodized oil) tissue adhesive applied by interventional radiology in the same session. Lymphatic duct leaks are caused especially by damage to the lymph channels after surgery. Lymphocutaneous fistula occurs as a result of increasing pressure and continuous lymph fluid leakage in lymphatic channels average for 48 hours (1). It can be demonstrated by lymphangiography and lymphoscintigraphy (2). It increases the risk of wound infection in patients and prolongs the duration of hospitalization (3). Lymphocutaneous fistula occurs as a rare complication after lymph node dissection (2), especially after cardiovascular operations (3). There are cases of lymphocutaneous fistula after plasmapheresis catheter placement (4), after lymph node dissection due to dermatological cancer, and after thyroid surgery (5) in the literature. Lymphangiography provide to show the lymph flow synchronously in radiography. It can also be used for the treatment of fistulas owing to inflammation and fibrosis created by contrast agent, such as patent blue, ethiodized oil (2). In cases that lymphangiography is not adequate for treatment, elevation treatment, pressure dressings, surgical sutures and low-dose radiotherapy can be applied (3). Lymphocutaneous fistulas are often seen after thoracic or abdominal surgery. However, as far as we know, in the literature, it is the first lymphocutaneous fistula case that seen after punch biopsy, which can be considered as relatively less invasive and we frequently prefer when diagnosing dermatological lesions.

**Keywords:** lymphocutaneous fistula, skin biopsy, complication



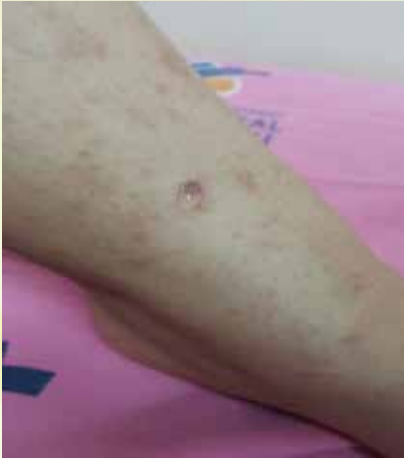# 4<sup>th</sup> INDERCOs

Dermatology and Cosmetology Congress  
with International Participants

27 - 30 MARCH, 2019  
HILTON ISTANBUL BOSPHORUS HOTEL  
ISTANBUL, TURKEY

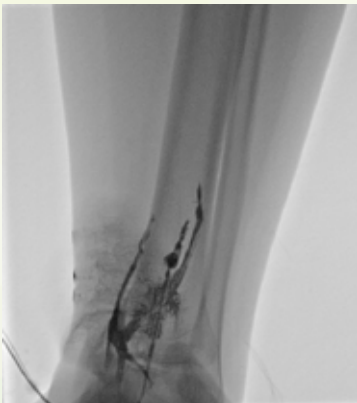

**figure 1**



*Erythematous scar through which a clear fluid*

**figure 2**



*It was demonstrated that the flow was associated to the lymphatic channels*





# 4<sup>th</sup> INDERCOS

## Dermatology and Cosmetology Congress with International Participants

27 - 30 MARCH, 2019  
HILTON ISTANBUL BOSPHORUS HOTEL  
ISTANBUL, TURKEY



### PP-20

#### ZOSTERIFORM GRANULOMATOUS ROSACEA

Irem Mantar<sup>1</sup>, Gülbahar Sarac<sup>1</sup>, Serpil Şener<sup>1</sup>, Hülya Cenk<sup>2</sup>, Saadet Alan<sup>3</sup>

<sup>1</sup>Department of Dermatology, İnönü University Faculty of Medicine, Malatya, Turkey

<sup>2</sup>Department of Dermatology, Malatya Research Hospital, Malatya, Turkey

<sup>3</sup>Department of Pathology, İnönü University Faculty of Medicine, Malatya, Turkey

Granulomatous rosacea is characterized by monomorphic papules located on normal-appearing skin [1]. Granulomatous rosacea, which is distinct from the basic rosacea subtypes, was accepted as a variant due to its histopathological features [2]. Rosacea is characterized by central facial involvement, especially on the nose, cheeks, chin, and forehead midline [1]. Three cases of localized rosacea have been reported in the literature [3–5]. Here, we present a case of granulomatous rosacea with a zosteriform distribution. A 57-year-old male presented to our outpatient clinic with pruritic lesions on his left forehead that had been present for 2 months. A physical examination revealed violaceous-erythematous papules and plaques formed by a combination of papules in a region compatible with the first branch of the left trigeminal nerve. The lesion extended toward the scalp but did not exceed the center line of the forehead (Figure 1). He did not report a cough, sputum, shortness of breath, fever, or weight loss. Blood tests and a chest X-ray produced normal results. A 3 mm punch biopsy was taken from the lesion. In histopathological examinations, granuloma formation and caseous necrosis with giant multinucleate cells were observed in the dermis. The superficial skin biopsy revealed Demodex mites (20/cm<sup>2</sup>). The patient consulted with a pulmonary specialist, but no pulmonary disease was detected. The patient was treated with topical methrin cream and metronidazole (1000 mg/day). At the end of the first month, dramatic improvement was observed. At the end of month 6, the patient's lesions had completely regressed (Figure 2). A superficial skin biopsy was negative for Demodex.

Although noncaseous epithelioid granuloma and inflammatory cell infiltration are observed histopathologically in this disease, caseous granuloma may also be seen [1, 6]. In our case, caseous granuloma was observed and the patient was investigated for the exclusion of skin tuberculosis. However, the Mantoux test and thorax computed tomography showed no significant abnormalities. In the literature, there are three case reports of localized rosacea: papulopustular rosacea in the left half of the face of an 80-year-old patient with same-sided facial paralysis [4], granulomatous rosacea located on the right cheek and jaw of a 65-year-old male patient [5], and granulomatous rosacea presenting with a yellow-crust, erythematous plaque at the same site after a herpes simplex virus infection [3]. A case of demodicosis in a pseudozoster clinic due to long-term topical steroid use after postherpetic neuralgia has also been reported [7]. In our case, there was no history of herpes zoster or zona zoster infection. There was no Bell's palsy or history of it. The patient did not use topical corticosteroids. This is the first case of caseous granuloma accompanied by demodicosis.

**Keywords:** zosteriform, granulomatous rosacea, localized, demodicosis



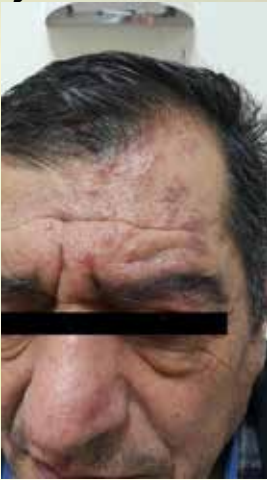# 4<sup>th</sup> INDERCOS

Dermatology and Cosmetology Congress  
with International Participants

27 - 30 MARCH, 2019  
HILTON ISTANBUL BOSPHORUS HOTEL  
ISTANBUL, TURKEY

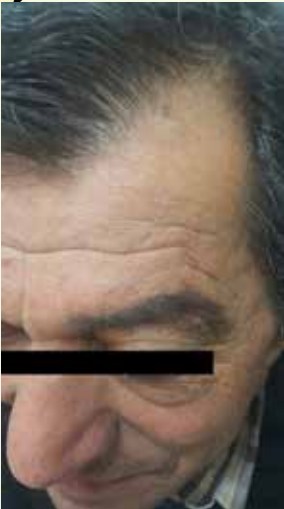

**figure 1**



*Violaceous-erythematous papules*

**figure 2**



*After treatment*



# 4<sup>th</sup> INDERCOS

## Dermatology and Cosmetology Congress with International Participants

27 - 30 MARCH, 2019  
HILTON ISTANBUL BOSPHORUS HOTEL  
ISTANBUL, TURKEY



### PP-21

#### **PSEUDOXANTHOMA ELASTICUM (PXE), A PEDIATRIC CASE**

*Damla Demir<sup>1</sup>, Ebru Zemheri<sup>2</sup>, Ilkin Zindanci<sup>1</sup>*

<sup>1</sup>University of Health Sciences Umraniye Research and Training Hospital, Department of Dermatology

<sup>2</sup>University of Health Sciences Umraniye Research and Training Hospital, Department of Pathology

Pseudoxanthoma elasticum (PXE) is a multisystemic, metabolic and autosomal recessive inherited disorder affecting especially elastic fibers of skin, retina and blood vessels. The prevalence varies from 1:25,000 to 1:100,000. The first clinical sign of PXE is almost always small yellow papules on the nape and sides of the neck and in flexural areas. The papules coalesce, and the skin becomes loose and wrinkled. The mid-dermal elastic fibers are short, fragmented, clumped and calcified. Dystrophic calcification of Bruch's membrane, revealed by angioid streaks, may trigger choroidal neovascularization and, ultimately, loss of central vision and blindness in late-stage disease. Lesions in small and medium-sized artery walls may result in intermittent claudication and peripheral artery disease. Cardiac complications (myocardial infarction, angina pectoris) are thought to be relatively rare but merit thorough investigation. A male patient with 5-year history of yellowish papules on his neck and 1-year history of yellowish papules on his groins and inferior abdominal area, was presented in this case report. This 7-year-old patient received a diagnosis of PXE based on medical story, clinical examination and histopathological findings. This case was presented as PXE is a rare disease and should be diagnosed by the clinician at early ages.

**Keywords:** Child, elastic fibers, Pseudoxanthoma elasticum

### PP-22

#### **MONILETHRIX, A CASE REPORT**

*Damla Demir<sup>1</sup>, Ilkin Zindanci<sup>1</sup>, Ebru Zemheri<sup>2</sup>*

<sup>1</sup>University of Health Sciences Umraniye Research and Training Hospital, Department of Dermatology, Istanbul, Turkey

<sup>2</sup>University of Health Sciences Umraniye Research and Training Hospital, Department of Pathology, Istanbul, Turkey

Monilethrix is a rare mostly autosomal dominant and less frequently autosomal recessive hair shaft disorder. The hair is normal at birth; however, in a few months the patient develops keratotic papules, alopecia and brittle hair. It may be associated with other ectodermal anomalies, most frequently follicular hyperkeratosis. Here, a 4-year-old female child with monilethrix and keratosis pilaris is presented. The diagnosis of monilethrix is established by clinical, dermatoscopy findings and scanning electron microscopy findings.

**Keywords:** Dermatoscopy, hair, monilethrix



# 4<sup>th</sup> INDERCOs

## Dermatology and Cosmetology Congress with International Participants



27 - 30 MARCH, 2019  
HILTON ISTANBUL BOSPHORUS HOTEL  
ISTANBUL, TURKEY

### PP-23

#### GIANT PILOMATRIXOMA, A CASE REPORT

*Damla Demir<sup>1</sup>, Ilkin Zindancı<sup>1</sup>, Ebru Zemheri<sup>2</sup>*

*<sup>1</sup>University of Health Sciences Umraniye Research and Training Hospital, Department of Dermatology, Istanbul, Turkey*

*<sup>2</sup>University of Health Sciences Umraniye Research and Training Hospital, Department of Pathology, Istanbul, Turkey*

Pilomatrixoma (PM) is a benign adnexal tumor emanating from hair matrix-cells, accounting for almost 20% of pilar tumors. It predominantly affects children and young adults and is particularly found on the head and neck and upper extremities. It usually presents as a single, slow-growing subcutaneous or intradermal firm nodule with a general size of less than 3 centimeters (cm) in diameter. Giant pilomatrixomas are more than 5 cm that have been reported infrequently. Since 1974, when Krausen et al. described the first case of giant PM, few similar lesions were described and most of them were reported in male patients during the second and sixth decades of life, mainly located on the head, neck, and upper extremities, being very rare on the back. In this case;

**Keywords:** Child, giant, pilomatrixoma





# 4<sup>th</sup> INDERCOS

## Dermatology and Cosmetology Congress with International Participants

27 - 30 MARCH, 2019  
HILTON ISTANBUL BOSPHORUS HOTEL  
ISTANBUL, TURKEY



PP-24

### FACIAL POROKERATOSIS IN ALA NASI; CASE REPORT

*Burçin Cansu Bozca<sup>1</sup>, Cumhuri İbrahim Başsorgun<sup>2</sup>, Erkan Alpsoy<sup>1</sup>*

<sup>1</sup>Department of Dermatology and Venerology, Akdeniz University School of Medicine, Antalya, Turkey

<sup>2</sup>Department of pathology, Akdeniz University School of Medicine, Antalya, Turkey

**INTRODUCTION AND OBJECTIVES:** Porokeratosis is an epidermal keratinization disorder with an unclear etiopathogenesis. Porokeratosis is characterized by annular plaques with an atrophic center and hyperkeratotic edges clinically. Cornoid lamella is the histopathological characteristic of the disorder and results from the abnormal proliferation of keratinocytes. Porokeratosis usually occurs on the trunk or extremities. Facial lesions have been reported rarely. Here we present a patient with bilateral symmetrical porokeratotic lesions located on both alae nasi of the nose.

**MATERIALS-METHODS:** A 33-year-old female patient presented with a complaint of crusted wounds, slowly growing on both sides of the alae nasi for 4 years. The complaint had begun in the first left ala nasi and developed shortly after the other. Previously used topical antibiotic, topical steroid, topical retinoid, pimecrolimus, and 5-fluorouracil were ineffective. The patient's history had no features other than iron deficiency anemia, and she received long-term iron replacement therapy. Dermatological examination revealed two symmetrical plaques with crusted and elevated sharp margins and relatively atrophic and hypopigmented central regions located on both alae nasi with a diameter of 0.7 cm on the right and 1 cm on the left side. Routine examinations were normal and ANA, anti-desmoglein 1, anti-desmoglein 3 were negative. Histopathological examination showed hyperkeratotic stratum corneum, weakly stained thin layer of parakeratotic cells (Cornoid lamella) and stratum granulosum depletion underneath.

**RESULTS:** The patient was diagnosed as porokeratosis. Diclofenac gel twice a day recommended for treatment.

**CONCLUSION:** Facial porokeratosis has been reported to be more frequent in young women and in patients with UV exposure. Although many areas of the body are exposed to sunlight only the face, mainly the nose and adjacent perinasal area are affected. Therefore, this new variety differs from other varieties related to sunlight exposure. Unlike other porokeratose types, autosomal dominant inheritance could not be demonstrated. Lesions may be superficial or destructive. Malignant transformation has not been reported so far. Facial porokeratosis can mimic annular lesions affecting the face such as actinic keratosis which cornoid lamella can also be seen. Actinic keratosis is differentiated from porokeratosis by the absence of furrowed keratotic rim dermoscopically and by the presence of partial epidermal cytological atypia pathologically. Also atrophic plaques may be confused with facial lesions of discoid lupus erythematosus. Although the age and gender of the presented patient were similar to those previously reported there was no significant history of UV exposure in our patient. Because solar damage can be responsible in the etiology diclofenac gel which has not been tried before has been preferred and a pronounced response has been achieved with 3-month treatment.

**Keywords:** Porokeratosis, Ala Nasi, Diclofenac gel





# 4<sup>th</sup> Indercos

## Dermatology and Cosmetology Congress with International Participants

27 - 30 MARCH, 2019  
HILTON ISTANBUL BOSPHORUS HOTEL  
ISTANBUL, TURKEY



**PP-25**

### **A RARE CASE: BULLOUS EOSINOPHILIC CELLULITIS**

*Fatmanur Kutlu, Kemal Özyurt, Ragıp Ertuş, Mustafa Atasoy*

Wells syndrome is a rare dermatosis characterized by acute erythematous, itchy-induced cellulite-like lesions. It can be presented such as erythematous papules, nodules or bullae. The diagnosis of Wells syndrome may be difficult. It can be confused with common dermatoses consist of bacterial cellulitis, contact dermatitis, urticaria, and drug eruptions. Although approximately half of the cases are presented with peripheral blood eosinophilia during the active disease. It is not necessary for diagnosis. We found worthy to present this case since eosinophilic cellulitis is rare and difficult to diagnose.

**Keywords:** *Wells syndrome, eosinophilic cellulitis, cellulitis*

**Figure 1**

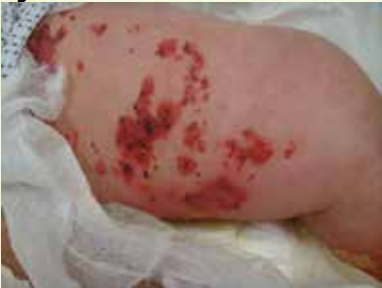

Figure 1: Erythematous edematous plaques with irregular border

**Figure 2**

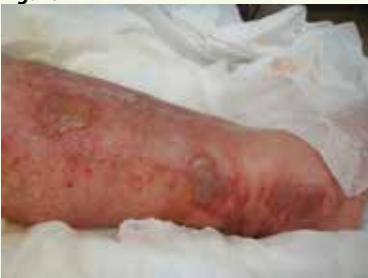

Figure 2: Erythematous indurated plaques with bullae



# 4<sup>th</sup> INDERCOS

## Dermatology and Cosmetology Congress with International Participants

27 - 30 MARCH, 2019  
HILTON ISTANBUL BOSPHORUS HOTEL  
ISTANBUL, TURKEY



### PP-26

#### NEVUS LIPOMATOSUS CUTANEUS SUPERFICIALIS ON THE LEG OF THE BOY PATIENT

*Kyimet Handan Kelekçi, Nurhan Döner, Ali Karakuzu, Erkan Davarcı*

*Department of Dermatology, İzmir Katip Çelebi University and Atatürk Training and Reseaching Hospital, İzmir, Turkey*

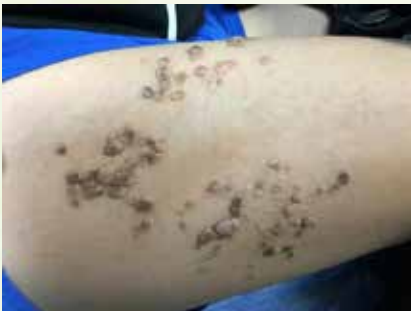**INTRODUCTION:** Nevus lipomatosus cutaneus superficialis(NLCS) is rare benign malformation characterized by derhal deposition of mature adxipose tissue. It's described to two types: classical and solitary form. Classically form is presented with multiple, unilateral, soft, nontender, pediculated, skin colored or yellowish papules, plaques and nodules with smooth or cerebriform surface. The lesions are usually congenital or appear in the first two decades of life. The main location of the classical type is pelvic girdle. Solitary type of nevus lipomatosus cutaneus superficialis usually occurs as a single nodular lesion. We describe a 15-year-old boy with an multiple noduls on his right limb, which he had had since 9-year old.

**CASE :** A15-year-old boy who presented to our out-patient clinic with multiple mass on his leg. The patient's medical history was unremarkable and no family member had experienced a similar lesion. Dermatological examination revealed skin-colored, polypoid, nontender, soft, skin-colored multiple nodules on the anterior his right leg (Figure 1). Histopathological examination showed mature adipose tissue interposed with bundles of collagen in the reticular dermis. Otherwise, body regions were normal. Histopathological findings were consistent with NLCS. He was treated with staged cryotherapy for better cosmetic results.

**CONCLUSION:** We find it appropriate to present a case of classic type NLCS in a boy patient because of its rarity.

**Keywords:** nevus, lipomatosus, leg

#### Figure 1



*Skin-colored, polypoid, nontender, soft, skin-colored multiple nodules on the anterior his right leg.*



# 4<sup>th</sup> INDERCOS

## Dermatology and Cosmetology Congress with International Participants

27 - 30 MARCH, 2019  
HILTON ISTANBUL BOSPHORUS HOTEL  
ISTANBUL, TURKEY



PP-27

### CHONDROID SYRINGOMA OF RIGHT CHEEK OF THE FEMALE PATIENT: REPORT OF A CASE

*Nurhan Döner<sup>1</sup>, Kıymet Handan Keleşçi<sup>1</sup>, Fatma Şule Afşar<sup>1</sup>, Aslı Kahraman Akkalp<sup>2</sup>*

<sup>1</sup>Department of Dermatology, İzmir Katip Çelebi University and Atatürk Training and Reseaching Hospital, İzmir, Turkey

<sup>2</sup>Department of Pathology, İzmir Katip Çelebi University and Atatürk Training and Reseaching Hospital, İzmir, Turkey

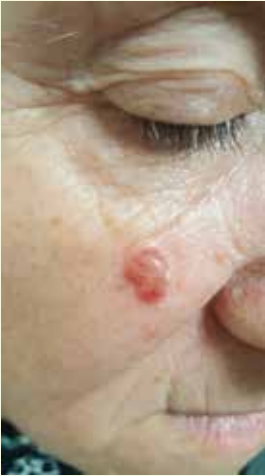**INTRODUCTION:** Chondroid syringoma is a rare benign neoplasm of the sweat glands characterized by a mixture of epithelial and mesenchymal tissues. Chondroid syringoma usually have the apparence of slow-growing, painless swelling, subcutaneous, or intracutaneous nodules in the head and neck region. These lesions appear between the ages of 20-70 years, with a distinct male predominance. We report a case of chondroid syringoma on the right cheek of the female patient.

**CASE:** A 64-year-old female patient, presented with an asymptomatic mass occasionally with itching on the right cheek for one year. The lesion had been present for 3 years before admission with slow rate of growth. Her medical history was unremarkable except for hypertension and diabetes mellitus. On physical examination, it was red, firm, lobulated nodul, measuring 0.5x1x1 cm, painless on palpation, adherent to the surrounding skin but there was no associated skin punctum (Fig. 1). There was no lymphadenopathy in the neck. The dermoscopy of the lesion showed branching arborizing vessels on erythematous ground (Fig. 2). The histopathologic examination of the lesion revealed the superficial dermis which were not related to the epidermis, and chondromyxoid material was selected in the lumens and extracellular areas (Fig.3).

**CONCLUSION:** Chondroid syringoma is a rare sweat gland tumor. It should be kept in mind in the differential diagnosis of skin cancers.

**Keywords:** *pathology, sweat gland, syringoma*

**Figure 1**



*Red, firm, lobulated, painless nodular lesion with arborising telangiectasia*

**Figure**

2



*Dermoscopy of the lesion showed branching arborizing vessels on erythematous ground.*



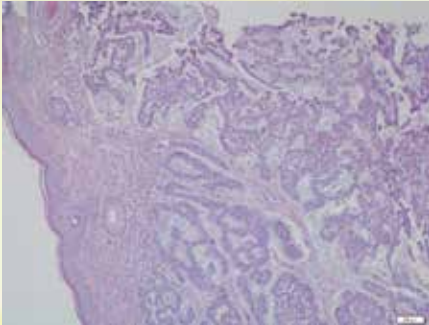
# 4<sup>th</sup> INDERCOs

Dermatology and Cosmetology Congress  
with International Participants

27 - 30 MARCH, 2019  
HILTON ISTANBUL BOSPHORUS HOTEL  
ISTANBUL, TURKEY



**Figure 3**



*Chondromyxoid material was selected in the lumens and extracellular areas.(H&E 10)*





# 4<sup>th</sup> INDERCOS

## Dermatology and Cosmetology Congress with International Participants

27 - 30 MARCH, 2019  
HILTON ISTANBUL BOSPHORUS HOTEL  
ISTANBUL, TURKEY



PP-28

### **BASAL CELL CARCINOMA ARISING WITHIN SEBORRHEIC KERATOSES: A CASE REPORT**

*Nurhan Döner<sup>1</sup>, Kıymet Handan Kelekçi<sup>1</sup>, Fatma Şule Afşar<sup>1</sup>, Aslı Kahraman Akkalp<sup>2</sup>, Ali Karakuzu<sup>1</sup>, Beste Nigar Gök<sup>1</sup>*  
*<sup>1</sup>Department of Dermatology, İzmir Katip Çelebi University and Atatürk Training and Reseaching Hospital, İzmir, Turkey*

*<sup>2</sup>Department of Pathology İzmir Katip Çelebi University and Atatürk Training and Reseaching Hospital, İzmir, Turkey*

**INTRODUCTION:** Basal cell carcinoma (BCC) is the most common cutaneous malignancy. This tumor can extremely rare observed in association with seborrheic keratoses. Seborrheic keratoses, one of the most common epidermal tumours, is frequently encountered skin disease. It is most commonly localized in head and neck region followed by body, upper and lower extremities. The clonal relationship between basal cell carcinoma and seborrheic keratosis is still not clear. Here we presented with basal cell carcinoma arising within seborrheic keratosis in a 74-year-old man with a skin lesion of the right eye around.

**CASE:** A 74-year-old male patient was admitted with flat, brown, warty lesion on skin of his right face region. Seborrheic keratosis was present for 2-years but slowly enlarging in last 5-6 months. His medical history was unremarkable except for hypertension. In physical examination a brown plaque with a 10 x 15 mm diameter, slightly elevated pink lesion from skin was observed (Figure 1). In microscopic evaluation, there was marked hyperkeratosis and proliferation in basaloid cells in lower layers of epidermis showing acanthosis and containing pseudohorn cysts. Histopathology of the lesion revealed keratin pseudocysts and consisting of basal proliferating keratinocytes of seborrheic keratosis and peripheral palisading basaloid cells through papillary dermis with retraction artifact of basal cell carcinoma (Figure 2). Our findings are consistent with basal cell cancer arising within seborrheic keratosis. He was referred to plastic surgery for total excision of the lesion.

**CONCLUSION:** Although other tumors overlying seborrheic keratosis have been reported frequently, here, we present the development of basal cell carcinoma arising within seborrheic keratosis because it is rare.

**Keywords:** *basal cell cancer, pseudocyst, seborrheic keratoses*



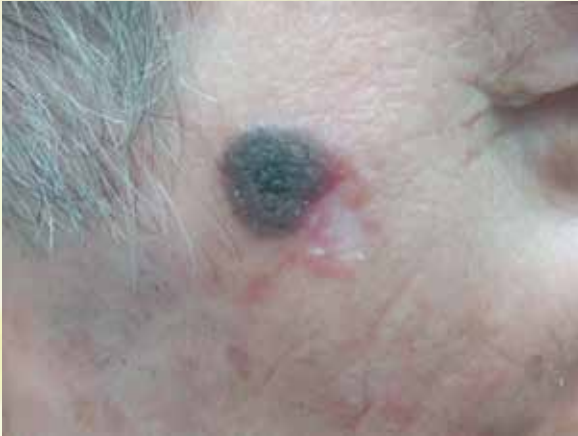# 4<sup>th</sup> INDERCOs

Dermatology and Cosmetology Congress  
with International Participants

27 - 30 MARCH, 2019  
HILTON ISTANBUL BOSPHORUS HOTEL  
ISTANBUL, TURKEY

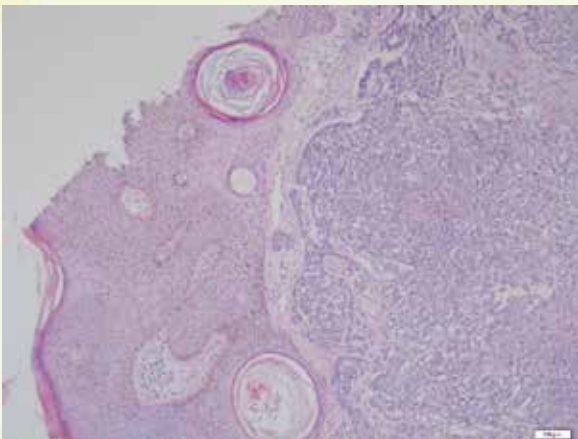


**Figure 1**



*Fat, brown, and warty lesion on skin of his right face region.*

**Figure 2**



*Keratin pseudocysts and consisting of basal proliferating keratinocytes of seborrheic keratosis and peripheral palisading basaloid cells through papillary dermis of basal cell carcinoma. (H&E40)*



# 4<sup>th</sup> INDERCOS

## Dermatology and Cosmetology Congress with International Participants

27 - 30 MARCH, 2019  
HILTON ISTANBUL BOSPHORUS HOTEL  
ISTANBUL, TURKEY



### PP-29

#### **A CASE OF CUTANEOUS METASTASIS OF LUNG ADENOCANCER PRESENTING WITH NECK PAIN**

Mustafa Anıl Yılmaz, *Selen Gökçel*

*Department of Dermatology and Venerology, Mersin University, Mersin, Turkey*

**INTRODUCTION:** Lung cancer is one of the most frequent malignancies, with high mortality rates. [1] It can metastasize in almost all organs, but more often invades hilar nodes, liver, adrenal glands, bones and brain. There are various data on the incidence of lung cancer metastases in the skin. [2,3]. In 1-12% of patients with lung cancer are developed skin metastases. Metastases in the skin may be the first sign of lung cancer. [4].

**CASE PRESENTATION:** Fifty-three years old Turkish male, smoker, was consulted to our department with multiple erythematous nodules localized in the skin of the neck (Figure 1). He also had a history of lung cancer for which he underwent partial lobectomy of the right lower lobe along with radiation two years prior for a T3N1M0 lung tumor non-small-cell type (adenocarcinoma). The nodules measuring 5–15 millimeters in greatest dimension were round and skin-colored, with telangiectasias, firm and tender. They appeared in an eruptive form about four weeks before being admitted at our hospital. Inisional biopsy was performed to one of the neck lesions. Histopathology confirmed metastatic nature of the lesion namely, consistent with adenocarcinoma of lung carcinoma which stained positive expression of TTF-1 and KRAS mutation (Figure 2). Chest X-ray and computed tomography revealed an expansive process in the right sternocleidomastoid muscle to adjacent neck skin. (Figure 3) The patient was referred to the department of radiation oncology for further treatment. The patient passed away three months after the diagnosis of lung cancer first presented with skin metastases.

**DISCUSSION:** Cutaneous metastasis is often painless, nodular, single, or multiple lesions and may be mobile or fixed presentations. Although it is very rare, cutaneous metastases, which may be concurrent with the diagnosis of lung cancer, may be the first sign of the disease. (5) Therefore, patients with suspicious skin lesions should be evaluated with biopsy.

**Keywords:** *Skin metastases, Lung cancer, skin neoplasms*



# 4<sup>th</sup> INDERCOs

Dermatology and Cosmetology Congress  
with International Participants  
27 - 30 MARCH, 2019  
HILTON ISTANBUL BOSPHORUS HOTEL  
ISTANBUL, TURKEY

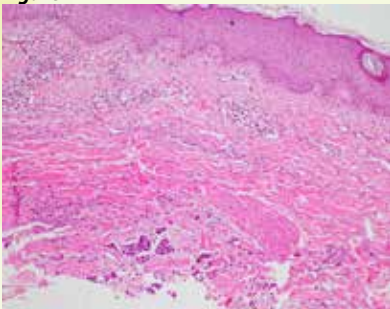


**Figure 1**



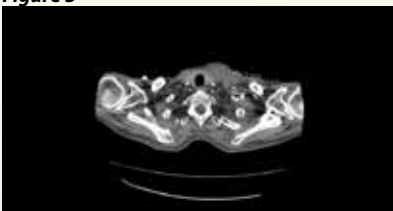
*erythematous metastatic nodules localized in the skin of the neck(Figure 1)*

**Figure 2**



*. Histopathology confirmed metastatic nature of the lesion namely, consistent with adenocarcinoma of lung carcinoma which stained positive expression of TTF-1 and KRAS mutation detected (Figure 2) (Figure 2)*

**Figure 3**



*Increased asymmetrical skin thickness detected by cervical CT*



# 4<sup>th</sup> INDERCOS

## Dermatology and Cosmetology Congress with International Participants

27 - 30 MARCH, 2019  
HILTON ISTANBUL BOSPHORUS HOTEL  
ISTANBUL, TURKEY



### PP-30

#### PAGET DISEASE OF THE NIPPLE: CASE REPORT

*Damla Demir<sup>1</sup>, Ilkin Zindancı<sup>1</sup>, Ebru Zemheri<sup>2</sup>*

*<sup>1</sup>University of Health Sciences Umraniye Research and Training Hospital, Department of Dermatology, Istanbul, Turkey*

*<sup>2</sup>University of Health Sciences Umraniye Research and Training Hospital, Department of Pathology, Istanbul, Turkey*

Mammary Paget's disease (PD) is clinically defined as skin inflammation of the nipple area and is an adenocarcinoma of the epidermis of the nipple. The pathogenesis of mammary PD is relatively unknown; nonetheless, there are two popular theories that support the underlying carcinoma and de novo carcinogenesis. PD has been classified as: (1) Paget disease of the nipple without ductal carcinoma in situ (DCIS), (2) PD associated with DCIS in the underlying lactiferous duct, or (3) PD associated with DCIS in the underlying lactiferous ducts plus a secondary lesion (DCIS or invasive breast cancer elsewhere at least 2 cm from the NAC). Other variants of PD of the nipple include Pigmented and Anaplastic PD. We present a 38-year-old woman who was diagnosed Paget's disease without DCIS with clinical and histopathological findings, presenting with ulcers growing on her breast for 7 years.

**Keywords:** Breast, Nipple, Paget's disease





# 4<sup>th</sup> INDERCOS

## Dermatology and Cosmetology Congress with International Participants

27 - 30 MARCH, 2019  
HILTON ISTANBUL BOSPHORUS HOTEL  
ISTANBUL, TURKEY



### PP-31

#### CONFUSING PRESENTATION OF LYME BORRELIOSIS IN THE COURSE OF CHRONIC URTICARIA: COEXISTENCE OR NOT?

Ragıp Ertas<sup>1</sup>, Kemal Özyurt<sup>1</sup>, Kemal Ero<sup>2</sup>, Şule Ketenci Ertas<sup>3</sup>, Huzeyfe Kulu<sup>1</sup>, Mustafa Atasoy<sup>1</sup>

<sup>1</sup>Department of Dermatology, Kayseri City Hospital, Kayseri, Turkey

<sup>2</sup>Department Rheumatology, Kayseri City Hospital, Kayseri, Turkey

<sup>3</sup>Department of Internal medicine, Division of Rheumatology, Erçiyas University, Kayseri, Turkey

Lyme borreliosis, caused by a spirochete named as *Borrelia burgdorferi*, transmitted by ticks to mammals. This can cause a multi-system disorder affecting a large scale of tissues including skin, joints, heart, nervous system, and some other organs. *Borrelia burgdorferi* is known as a causative agent in some dermatological diseases such as chronic urticaria, urticarial vasculitis, scleroderma circumscripta, lichen sclerosus et atrophicus, granuloma anulare, erythema anulare, erythema nodosum. Chronic urticaria has multifactorial aetiologies including allergic, infectious diseases, and autoimmune diseases.

A 44-year-old woman was admitted to out-patient clinic with a 4-month history of chronic urticaria with angioedema. In her previous medical history, she had taken high dose antihistamines and systemic steroids. She was describing typical urticarial wheals on her face, arms and trunk which persist <24 hours for nearly four months. However, she has described different annular, erythematous, pruritic, indurated lesions on her legs which lasts with pigmentation and persisted several days during the last month. The patient also had arthralgias and angioedema on her lips and eyelids. She was consulted to rheumatology, and a skin biopsy had taken. Laboratory evaluation revealed the following RESULTS: White blood cells, with 75.8% neutrophils, 17% lymphocytes, 6.2% monocytes, 0.6% eosinophils, 0.4% basophils, hemoglobin 12.8g/dl, platelets: 268 103/uL, erythrocyte sedimentation rate: 23 mm/hr, CRP: 11.6 mg/L (normal 0 to 5), BUN, 24.4 mg/dL, creatinine, 0.69 mg/dL, AST:17 IU/L; ALT: 12 IU/L, IgE: 11.64 IU/ml (Normal), IgM: 0.86 g/L, Ig G: 13.56 g/L, Ig A: 1.96 g/L, anti TPO: 9.9 U/ml(normal 0 to 34), antinuclear antibodies: homogenous and granular positive with IFA. ANA profile showed only DFS70 positivity. Anti-Borrelia-Burgdorferi IgM: 0.834 (normal index<0.411). After extensive workup, she was diagnosed with Lyme disease based on the clinical presentation and positive serology. She was started to treat with doxycycline.

Lyme disease is the most common vector-borne infection in West Europe and Northeastern territories of United States. Despite, seroprevalence studies, case reports and widespread epidemiologic studies of Lyme disease are lacking in Turkey as which 80 cases have been reported until now. Erythema chronicum migrans is the hallmark of Lyme disease. However, it is not the only skin lesion that seen during the course of the disease. In particular the early stages of the Lyme disease, with wide variability of the clinical symptomatology, often present a diagnostic challenge. Both in the differential diagnostic consideration of chronic urticaria and urticarial vasculitis, Lyme borreliosis should also considered.

**Keywords:** *Lyme borreliosis, Chronic Urticaria, Urticarial Vasculitis*



# 4<sup>th</sup> INDERCOS

## Dermatology and Cosmetology Congress with International Participants

27 - 30 MARCH, 2019  
HILTON ISTANBUL BOSPHORUS HOTEL  
ISTANBUL, TURKEY



### PP-32

#### **A VERY RARE COINCIDENCE OF ACUTE MYELOBLASTIC LEUKEMIA AND SEVERE CHRONIC SPONTANEOUS URTICARIA: IF IT IS HARD TO MANAGE, ENLARGE YOUR PERSPECTIVE**

*Ragıp Ertaş<sup>1</sup>, Şule Ketenci Ertaş<sup>2</sup>, Kemal Özyurt<sup>1</sup>, Mustafa Atasoy<sup>1</sup>*

<sup>1</sup>*Department of Dermatology, Kayseri City Hospital, Kayseri, Turkey*

<sup>2</sup>*Department of Internal Medicine, Division of Rheumatology, Erciyes University, Kayseri, Turkey*

Chronic spontaneous urticaria (CSU) is a frequent and frustrating disorder. The mechanisms causing CSU, have been tried to be brought to the light. Possible reasons that can be evaluated in the course of the disease are still limited. The association of malignant tumor and CSU remains unclear. Here we present a case of severe and antihistamine-resistant CSU which diagnosed as Acute Myeloblastic Leukemia (AML) after getting one-year treatment for CSU. Interestingly, CSU was completely disappeared once the chemotherapy was initiated. An 18-year-old female was admitted to our out-patient clinic with a 14-month history of chronic urticaria with angioedema. In her previous medical history, she has been taken four-fold antihistamines, montelukast 10 mg/day and omalizumab with a dose of 300mg/month together for 12 months in another tertiary dermatology clinic. Her urticaria scores were poor despite the treatments: urticaria activity score (UAS) was 4 (0 to 6) and urticaria control test score (UCT) was 8 (0-16). The patient was re-evaluated in our out-patient clinic due to the high urticaria scores. During the extensive workup, only mild low platelet levels (first visit: 142000  $\mu$ L, second visit: 100000  $\mu$ L) were detected. She was consulted to hematology. On subsequent follow-up, the platelet values decreased further, and it was decided to perform a bone marrow biopsy. She was diagnosed with AML-M3. She was started to treat with all-trans retinoic acid (ATRA). CSU was completely resolved with the initiation of ATRA.

AML is characterized by proliferation of myeloid blast cells in the bone marrow, peripheral blood, and organs such as the spleen and liver, which cause bone marrow failure. Several cases of malignant tumors have been reported in association with urticaria, such as leukemias and lymphomas, myeloma, testicular cancer, ovarian carcinoma, lung cancer, colon cancer, and thyroid carcinoma. To our knowledge, this is the first report of AML during the course of CSU. As a conclusion, it is very important to re-evaluate the patients with CSU when there is unresponsiveness to the treatment.

**Keywords:** *Chronic Urticaria, Malignancy, AML*



# 4<sup>th</sup> Indercos

## Dermatology and Cosmetology Congress with International Participants

27 - 30 MARCH, 2019  
HILTON ISTANBUL BOSPHORUS HOTEL  
ISTANBUL, TURKEY



PP-33

### A SIMPLE AND EASY WAY TO REMOVE SOLVENT BASED GLUE: A CASE REPORT

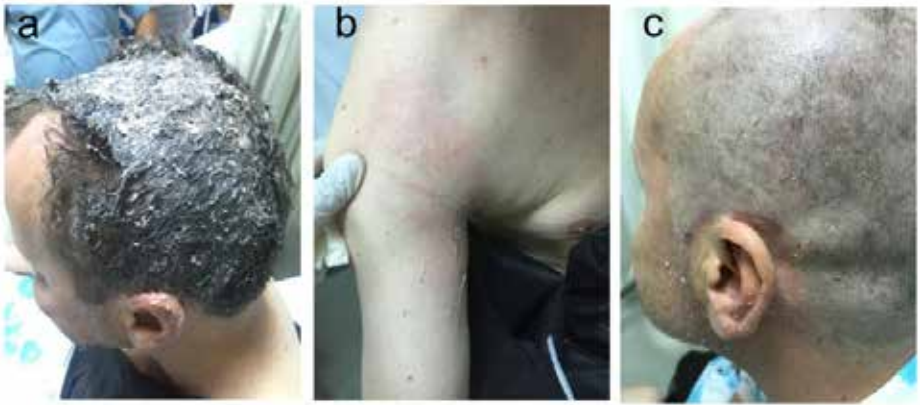Hakan Arslan, Özgür Gündüz

Department of Dermatology and Venerology, Kirikkale University, Kirikkale, Turkey

A 50-year old patient presented to the emergency department of our hospital due to an industrial accident, which left him covered with a industrial type adhesive. At the time of presentation, his scalp, neck and shoulders were covered with adhesive and painful erythematous and exfoliating skin areas on his shoulders were visible. First interventions, such as washing or cutting the hair were unsuccessful. As a last result, we tried to resolve the adhesive with acetone to prevent further chemical damage. We present this case because this easy method may be used to treat such conditions in an efficient and fast way.

**Keywords:** *industrial adhesive, irritant contact dermatitis, acetone*

**Figure 1**



(a) Patient's hair covered with the industrial adhesive. (b) The irritant effect of the adhesive seen more clearly on the patient's right shoulder as a painful, exfoliating dermatitis (c) Patient's hair could be cut only after the removal of the adhesive by the use of acetone



# 4<sup>th</sup> INDERCOS

## Dermatology and Cosmetology Congress with International Participants

27 - 30 MARCH, 2019  
HILTON ISTANBUL BOSPHORUS HOTEL  
ISTANBUL, TURKEY



**PP-34**

### **A CASE OF RESISTANT PEMPHIGUS VULGARIS**

*Melike Kibar Ozturk*

*Department of Dermatology, Umraniye Training and Research Hospital, Istanbul, Turkey*

**BACKGROUND:** Pemphigus vulgaris (PV) is a rare autoimmune skin disease characterized by blistering of the skin and mucous membranes. It has an approximate prevalence of 1 per 1,000,000 population. PV usually presents with oral erosions. PV can be diagnosed either by its clinical features, and by histopathological properties of acanthocytes inside suprabasal vesicles in the epidermis. The mortality rate of PV was around 90% before the usage of corticosteroid therapy; advances in adjuvant therapy have now brought the mortality rate about twenty percent.

**CASE:** A 57-year-old female patient was referred with odynophagia and skin erosions on specific sites of her skin for 2 months that had worsened over the past 1 month. She reported blisters in the oral mucous membranes at the onset, apart from thrush, drooling and dysphagia. She felt her problems were related to her onion rich diet, and gave a history of gastritis. Clinical examination showed mucosal hyperemia, apart from ulcers, thrush and white plaques in the buccal and gingival mucosae and blisters and erosions in the axilla, vulva, labiums and abdomen (figure 1a&b&c). She was prescribed doxycycline, fluconazole, and nystatin without improvement. These skin diseases were considered in the differential diagnosis: Stevens-Johnson syndrome, oral candidiasis, pemphigus vulgaris, pemphigoid, paraneoplastic pemphigus and Behçet's disease. Biopsy of lesions showed suprabasal acantholysis, confirming the diagnosis of pemphigus vulgaris. Initially, the patient was prescribed prednisolone tablets 20 mg, which were to be taken twice daily. Topical application of triamcinolone gel, was recommended to be used twice daily on the mucosae. The patient was also given calcium and Vitamin D supplements. A reduction of the areas of ulcerations and blisters could not be seen with this treatment for 3 weeks. Therefore, methotrexate administration is added to the treatment protocol. After 3 days, no new lesions were noted. Complete epithelization of the mucous membranes and skin lesions were observed after two weeks. After 5 weeks, the corticosteroid dose was tapered to 10 mg, twice daily. Over the past 3 months, prednisolone was gradually tapered down as there was complete regression of the lesions. After 4 months the patient was in remission, controlled with prednisone and methotrexate (figure 1d&e).

**CONCLUSION:** Although most of the PV cases are treated with corticosteroids alone, it is important to use an adjuvant therapy in resistant cases since PV is associated with a high mortality rate if not diagnosed and treated properly. This report work highlights the importance of adjuvant therapy.

**Keywords:** pemphigus, methotrexate, blisters





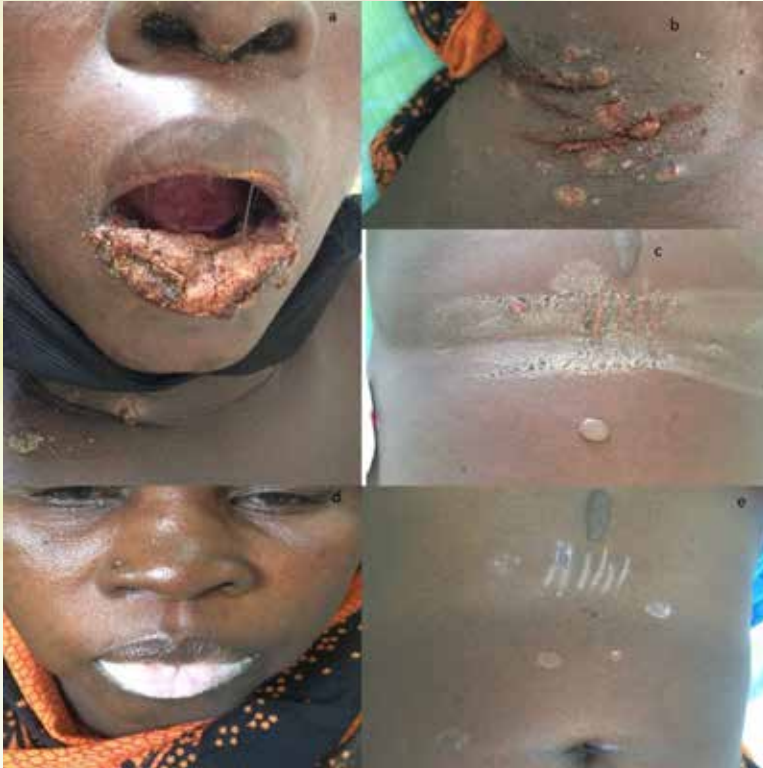# 4<sup>th</sup> INDERCOS

Dermatology and Cosmetology Congress  
with International Participants



27 - 30 MARCH, 2019  
HILTON ISTANBUL BOSPHORUS HOTEL  
ISTANBUL, TURKEY

figure 1



*The clinical pictures of the patient before and after treatment.*





# 4<sup>th</sup> Indercos

## Dermatology and Cosmetology Congress with International Participants

27 - 30 MARCH, 2019  
HILTON ISTANBUL BOSPHORUS HOTEL  
ISTANBUL, TURKEY



### PP-35

#### VANCOMYCIN-ASSOCIATED LINEAR IGA BULLOUS DERMATOSIS MIMICKING TOXIC EPIDERMAL NECROLYSIS

*Gizem Filazi, Begüm Ünlü, Ümit Türsen*

*Department of Dermatology, Mersin University School of Medicine, Mersin, Turkey*

Linear IgA bullous dermatosis is a rare subepidermal autoimmune blistering disease characterized by linear deposition of IgA along the basement membrane zone. In the last five decades many different drugs have been associated with the drug-induced form of the disease, especially vancomycin. Here we report a 65 year old male with a history of infective endocarditis treated with intravenous vancomycin. He presented with a vesiculobullous eruption on his trunk, extremities and oral mucosa, resolved with IVIG therapy.

**Keywords:** bullous dermatosis, vancomycin, ivig

### PP-36

#### PALMOPLANTAR PSORIASIFORM RASH FOLLOWING INFLIXIMAB, CERTOLIZUMAB AND SECUKINIMAB THERAPY FOR ANKYLOSING SPONDYLITIS; A CASE REPORT

*Büşra Deniz, Ümit Türsen*

*Mersin University School of Medicine, Mersin, Turkey*

Paradoxical palmoplantar psoriasiform reactions can be seen during treatment with many biologic agents which are used in rheumatoid arthritis (RA), psoriasis, and inflammatory bowel disease. Paradoxical psoriasis was first described in a patients with ankylosing spondylitis who were treated with infliximab. The most common form of paradoxical psoriasis is pustular psoriasis which is located on the palmoplantar areas. Flexural, guttate psoriasis and erythrodermic psoriasis types have also been reported in literature. We reported 29 old male patient who has palmoplantar pustular psoriasiform rash that was developed after infliximab, certolizumab and secukinimab therapy

**Keywords:** paradoxical psoriasis, palmoplantar psoriasiform rash, biologic agents

### PP-37

#### DIGITAL TOURNIQUET METHOD USING A GLOVE FINGER STRIP IN MATRICECTOMY

*Selen Gökçel, Emin Gündüz, Ümit Türsen*

*Department of Dermatology, Mersin University, Mersin, Turkey*

All digital surgical intervention modalities including matricectomy require a proper pressure and bleeding control and a clean operation field. Many tourniquet types like glove fingers, penrose drains and standart pneumatic tourniquets can be used for these purposes. In this study we shared our preferred digital tourniquet method and material obtained with a cut from a latex glove which is effective and simple to use.

**Keywords:** tourniquet, glove, matricectomy



# 4<sup>th</sup> INDERCOS

## Dermatology and Cosmetology Congress with International Participants

27 - 30 MARCH, 2019  
HILTON ISTANBUL BOSPHORUS HOTEL  
ISTANBUL, TURKEY



### PP-38

#### **ECCRINE NEUTROPHILIC HIDRADENITIS IN A CHILD WITH ACUTE MYELOGENOUS LEUKEMIA**

*Selen Gökçel, Tuğba Tehçi, Melodi Lif, Ümit Türsen*

*Department of Dermatology, Mersin University, Mersin, Turkey*

Neutrophilic eccrine hidradenitis is a rarely seen reactive clinical condition with a benign course appears mainly in patients diagnosed with hematologic malignancies like hodgkin lymphoma and solid tumors and receiving systemic chemotherapy. Clinical appearances can vary in morphology. We report a case of a 9-year-old male patient presenting with erythematous plaques on face after receiving a chemotherapy protocol with cytarabine, etoposide and idarubicine for acute myelogenous leukemia. Our diagnosis is confirmed as neutrophilic eccrine hidradenitis histopathologically. The symptoms were resolved after discontinuation of treatment and appliance of oral steroid therapy.

**Keywords:** Eccrine neutrophilic hidradenitis, chemotherapy, acute myelogenous leukemia

### PP-39

#### **EXTENSIVE TINEA INCOGNITO: A CASE REPORT**

*Fatma Tunçez Akyürek, Nihal Sarı, Gülcan Saylam Kurtipek*

*Department of Dermatology Selcuk University, Konya, Turkey*

Tinea incognito is a dermatophyte infection modified by topical steroids. It is caused by prolonged use of topical steroids and its clinical presentation may vary and mimic the most of dermatoses. A 67-year-old female patient presented with a complaint of pruritic rash on her left wrist that began 3 years ago and gradually spread to her arm. On dermatological examination, there was a large, sharply limited, erythematous, atrophic and telangiectatic plaque with several small nodules on the left arm. Native preparation of the patient's lesions revealed a large amount of hyphae. Although the chronicity of the lesions often leads the clinician to perform invasive histopathological examination, tinea incognito should be kept in mind in the atypical-appearing lesions, which do not regress even though the use of potent topical corticosteroids.

**Keywords:** Tinea incognito, corticosteroids, native preparation



# 4<sup>th</sup> INDERCOS

## Dermatology and Cosmetology Congress with International Participants

27 - 30 MARCH, 2019  
HILTON ISTANBUL BOSPHORUS HOTEL  
ISTANBUL, TURKEY



### PP-40

#### DIGITAL ISCHEMIA AND HYPEREOSINOPHILIA

*Amel Rezgui, Wafa Baya, Jihed Anoun, Monia Karmani, Fatma Ben Fredj, Chedia Laouani  
Internal Medicine Departement, CHU Sahloul, Sousse, Tunisia*

Hypereosinophilic syndrome is characterized by an overproduction of eosinophils that leads to organ damage. Although most cases of this syndrome frequently affect the heart, lungs and gastrointestinal tract, there are a few reported cases of vascular involvement. We report here a case with hypereosinophilia, peripheral artery occlusion, digital ischemia, cutaneous and cerebral vasculitis. A 47-year-old Tunisian man presented to us with purpura on lower extremity, swelling and pain on upper extremity and cyanosis of his fingers. Arterial Doppler revealed occlusion of radial and ulnar arteries. The biopsy specimen showed perivascular and periadnexal dense eosinophilic infiltration in dermis and subcutaneous adipose tissue. Laboratory investigations revealed a persistent hypereosinophilia. He was prescribed prednisolone 80 mg daily with nifedipine and iloprost. His skin lesion, pain and digital ischemia were improved and the eosinophil count was dramatically decreased. After discharge, eosinophil count gradually increased again. Dysarthria and left hemiparesis occurred. The MRI showed lesions of cerebral vasculitis. We prescribed prednisolone, cyclophosphamide and clopidogrel with good result.

**Keywords:** hypereosinophilia, artery occlusion, vasculitis, digital ischemia, necrosis



# 4<sup>th</sup> INDERCOS

## Dermatology and Cosmetology Congress with International Participants

27 - 30 MARCH, 2019  
HILTON ISTANBUL BOSPHORUS HOTEL  
ISTANBUL, TURKEY



PP-42

### ALLOPURINOL-INDUCED TOXIC EPIDERMAL NECROLYSIS: A CASE PRESENTATION AND REVIEW OF THE LITERATURE

*Zeynep Gizem Kaya İslamoğlu, Mehmet Akyürek, Mehmet Unal, Meltem Özasan  
Selçuk University, Department of Dermatology, Faculty of Medicine, Konya, Turkey*

**INTRODUCTION:** Toxic epidermal necrolysis (TEN) is an uncommon, acute and severe adverse drug reaction. This disease is characterized by necrosis of the epidermis. Its incidence is approximately one per million a year and mortality rate is approximately 40 percent. TEN is considered a hypersensitivity reaction and triggered by drugs, infections and malignancies. The most common drugs are allopurinol, antibiotics, anticonvulsants, non-steroid anti-inflammatory drugs (NSAIDs). TEN is characterized by a rapidly progress, it usually begins in the form of a maculopapular rash, followed by atypical, targetoid erythematous or purpuric macules on the skin, this is followed by bullous lesions accompanied by systemic symptoms and mucosal involvement. Fever, mild elevation of hepatic enzymes, intestinal and pulmonary manifestations can be seen. Systemic corticosteroids, intravenous immunoglobulins (IVIg), cyclosporine, plasmapheresis, antitumor necrosis factor drugs can be used in treatment.

**CASE PRESENTATION:** A 85 year old man patient, maculopapular rash and pruritus started in his body a week ago. After 3 days bullous lesions and exfoliation was started. Patient developed lesions two weeks after taking allopurinol. He had maculopapular rash in the extremities, diffuse erythema and exfoliation in the trunk and scalp, large bullous lesions in the palmoplantar region, erosion of the oral and genital mucosa, secondary candida infection in the oral mucosa on dermatological examination. The patient had a history of atrial fibrillation, benign prostatic hyperplasia, hypertension, chronic renal failure and cerebrovascular accident. Allopurinol-induced toxic epidermal necrolysis was considered. Histopathology confirmed TEN. SCORTEN score was 4. Intravenous immunoglobulin (IVIg) 2g/kg and methylprednisolone 1mg/kg/day was started. IVIg treatment divided into 5 consecutive days. Methylprednisolone was given for 24 days. After the treatment, the skin and mucosa findings completely healed. Pneumonia developed during treatment and he died due to septic shock.

**DISCUSSION:** TEN is a rare and serious reaction to life-threatening. The disease is mostly related to drugs. Allopurinol is one of the most common drugs. Good results are obtained with IVIg and high-dose methylprednisolone. The mortality rate is high in patients with elderly and comorbid problems.

**CONCLUSION:** Here, we aimed to present this rare case and the efficacy of high dose systemic steroid with IVIg combination in successful treatment of TEN.

**Keywords:** Toxic epidermal necrolysis, Allopurinol, IVIg, Methylprednisolone





# 4<sup>th</sup> INDERCOS

## Dermatology and Cosmetology Congress with International Participants

27 - 30 MARCH, 2019  
HILTON ISTANBUL BOSPHORUS HOTEL  
ISTANBUL, TURKEY



### PP-43

#### KIKUCHI- FUJIMOTO DISEASE WITH SKIN MANIFESTATION IN YOUNG WOMAN

*Kıymet Handan Keleşçi, Merve Veliöğlü, Ali Karakuzu*

*Department of Dermatology, İzmir Katip Çelebi University and Atatürk Training and Reseaching Hospital, İzmir, Turkey*

**INTRODUCTION:** Kikuchi-Fujimoto disease(KFD) is a self-limiting rare, benign histiocytic necrotising lymphadenitic clinicopathological entity of unknown aetiology that most commonly affects young women. The classical findings are painful lymphadenopathy, leukocytosis and fever. Its diagnosis can be challenging, as the disease must be differentiated from lymphoma and systemic lupus erythematosus. Diagnosis is confirmed by lymph node histology, which reveals paracortical foci of necrosis and a histiocytic infiltrate. Diverse, often nonspecific, cutaneous findings have been described in up to 40% of cases with KFD. Histopathologically, erythematous macules and papules tend to reveal a nonspecific dermatitis, which can complicate the diagnostic process. We report a patient with KFD with scattered partially indurated erythematous papules and plaques.

**CASE:** A 31 years old female patient presented with erythematous rash with pruritus disseminated whole body. The lesions first appeared sixteen months ago on her trunk. Dermatological examination revealed multiple erythematous papules and plaques with mild scaling primarily on upper extremities (Figure 1), neck and trunk and a few on lower extremities. Face lesions had regressed spontaneously leaving postinflammatory hipopigmentation. A skin biopsy performed from the lesions on the hand. Histopatological examination revealed epidermal focal parakeratosis, serum exudation, psoriasiform acanthosis, spongiosis, focal spongiotic microvesiculation, 1-2 necrotic keratinocyte in spinous layer, mild lymphocytic exocytosis and dermal mild edema, dermal mild perivascular lymphocytic infiltration which reported as superficial perivascular spongiotic psoriasiform dermatitis. PAS stain was negative. In her past medical history 3 years ago she had applied to general surgical department with left axillary painful nodules duration of 1 month. Complete blood count, peripheral blood smear, CRP levels were normal. ANA, ENA and protein electrophoresis were negative. Excisional biopsy from axillary lymph nodes showed focal histiocytic proliferation some with plasmocytoid appearance and crescentic nuclei, prominent apoptotic in between, lymphocytes mostly CD3 positive and CD30 positive immunoblasts, focal necrosis. Histiocytes were positive for the marker CD68 and MPO and some for CD123. Findings were consistent with histiocytic necrotising lymphadenopathy and she was in follow-up for Kikuchi Fujimoto disease in hematology department. Patient's skin manifestations treated with topical emollients and steroids.

**CONCLUSION:** The cutaneous clinical findings of Kikuchi Fujimoto disease are often nonspecific hence it can be overlooked. Here, we present a case of Kikuchi Fujimoto disease with skin involvement on the account of its rarity.

**Keywords:** Kikuchi-Fujimoto disease, skin manifestation, young girl





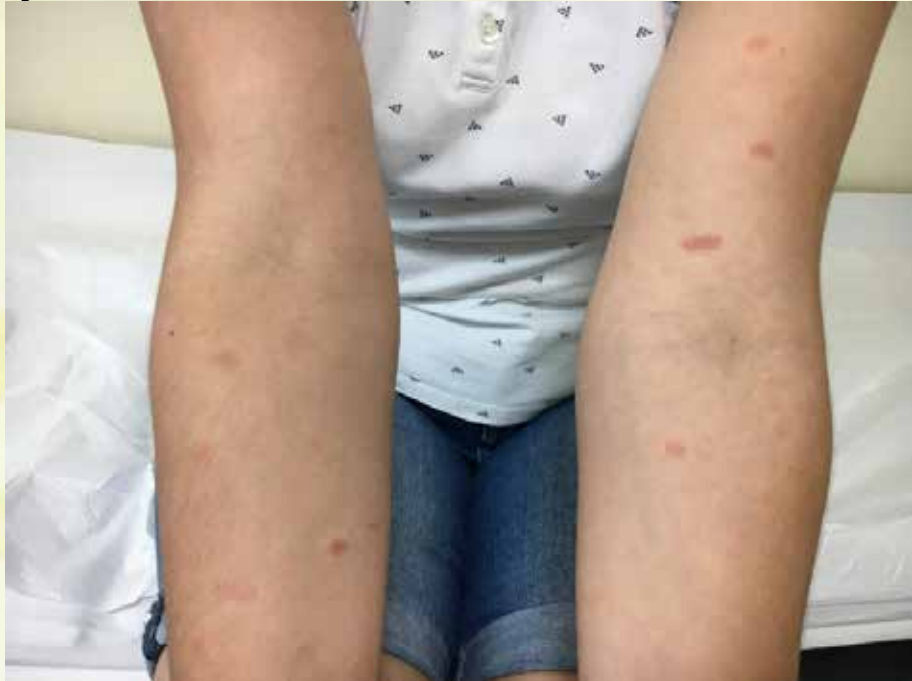# 4<sup>th</sup> INDERCOS

Dermatology and Cosmetology Congress  
with International Participants

27 - 30 MARCH, 2019  
HILTON ISTANBUL BOSPHORUS HOTEL  
ISTANBUL, TURKEY



**Figure**



*Multiple erythematous papules and plaques with mild scaling primarily on upper extremities.*



# 4<sup>th</sup> INDERCOS

## Dermatology and Cosmetology Congress with International Participants

27 - 30 MARCH, 2019  
HILTON ISTANBUL BOSPHORUS HOTEL  
ISTANBUL, TURKEY



### PP-44

#### **GLOMUS TUMOR OF THE NAIL UNIT: A CASE REPORT**

*Damla Demir<sup>1</sup>, Mustafa Demir<sup>2</sup>, Ilkin Zindanci<sup>1</sup>*

*<sup>1</sup>University of Health Sciences Umraniye Research and Training Hospital, Department of Dermatology, Istanbul, Turkey*

*<sup>2</sup>University of Health Sciences Umraniye Research and Training Hospital, Department of Radiology, Istanbul, Turkey*

Glomus tumor is a benign tumor arising from the neuromyoarterial plexus concentrated beneath the nail. This plexus is an arteriovenous anastomosis functioning without the intermediary capillary bed. Etiology is not exactly known. They are mostly located in the subungual region but occur less frequently in other nail unit region and extradigital sites. Characteristic triad of symptoms of temperature sensitivity, severe pain and localized tenderness can be noted in 63-100% of the patients. If a tumor is in nail matrix, it may cause nail deformity because of pressure. In this case; a 56-year-old female who had history of pain in the left thumb since 10 years, present vertical notching and groove in the nail bed.

**Keywords:** glomus tumor, nail deformity, notching



# 4<sup>th</sup> INDERCOS

## Dermatology and Cosmetology Congress with International Participants

27 - 30 MARCH, 2019  
HILTON ISTANBUL BOSPHORUS HOTEL  
ISTANBUL, TURKEY



### PP-45

#### EFFECTIVENESS OF TOPICAL NIGELLA SATIVA FOR VITILIGO TREATMENT

Gülbahar Saraç<sup>1</sup>, Serpil Şener<sup>1</sup>, Yelda Kapıcıoğlu<sup>2</sup>, İrem Mantar<sup>1</sup>, Saim Yoloğlu<sup>3</sup>, Cihat Dündar<sup>4</sup>, Murat Türkoğlu<sup>4</sup>, Erkin Pekmezci<sup>5</sup>

<sup>1</sup>Department of Dermatology, İnönü University, Malatya, Turkey

<sup>2</sup>Department of Dermatology, Liv Hospital, Istanbul, Turkey

<sup>3</sup>Department of Biostatistics, İnönü University Faculty of Medicine, Malatya, Turkey

<sup>4</sup>Biota Laboratories, R&D Center, Sancaktepe, Istanbul, Turkey

<sup>5</sup>Department of Dermatology, Gozde Hospital, Malatya, Turkey

**INTRODUCTION & OBJECTIVES:** Vitiligo is a pigment disease characterized by the disruption of melanocyte number and function. Its etiology is unknown; however, genetic, biochemical factors and neural mechanisms are thought to be effective. Although many agents are being used for its treatment, there is no cure. Insufficient repigmentation provided by the treatment options, long treatment duration and side effects of the drugs have led to research for new treatment modalities. The aim of this study is to evaluate the effectiveness of topical nigella sativa on vitiligo patients.

**MATERIAL-METHOD:** Thirty-three vitiligo patients were included in the study. Forty-seven areas were evaluated in the included patients. Nigella sativa was topically applied to hands, face and genital region 2 times a day for 6 months.

**RESULTS:** There was hand involvement in 16 (48.5%) patients, facial involvement in 23 (69.7%) patients and genital region involvement in 8 (24.2%) patients. In the pre- and post-treatment comparisons of the patients, the treatment was considered as successful in the presence of 50% or more repigmentation in the vitiligo region. Statistical difference was detected in hands, face and genital region, the three treatment areas.

**CONCLUSION:** In conclusion, vitiligo is a disease that does not lead to systemic involvement and internal organ damage. Although there are many conventional treatment methods used for vitiligo (UVB, steroid therapy, calcineurin etc), there is no gold standard treatment yet. Many patients seek herbal treatment agents, thinking herbal treatments as safer. However, many studies tried herbal vitiligo treatment and reported them to be insufficient as sole treatment and advised them to be combined with a conventional agent. In our study, we determined that nigella sativa provides statistically significant repigmentation in the hands, face and genital region. The highest repigmentation ratio was achieved in the genital region. As side effects are more frequent in the genital region, we believe that nigella sativa oil can be an important adjuvant treatment option for this region.

**Keywords:** vitiligo treatment, nigella sativa, herbal



# 4<sup>th</sup> INDERCOS

## Dermatology and Cosmetology Congress with International Participants

27 - 30 MARCH, 2019  
HILTON ISTANBUL BOSPHORUS HOTEL  
ISTANBUL, TURKEY



**Table -1:**

	=>4	<=3	Total	P Value
Number of patients	13 (56,5%)	10 (43,5%)	23 (100,0%)	0.001
Total	13 (56,5%)	10 (43,5%)	23 (100,0%)	

*Score distribution in the face region at month 6 is shown*

**Table -2:**

	=>4	<=3	Total	P Value
Number of patients	9 (56,3%)	7 (43,8%)	16 (100,0%)	0.005
Total	9 (56,3%)	7 (43,8%)	16 (100,0%)	

*Score distribution in the hand region at month 6 is shown.*

**Table -3:**

	=>4	<=3	Total	P Value
Number of patients	1 (12,5%)	7 (87,5%)	8 (100,0%)	0.004
Total	1 (12,5%)	7 (87,5%)	8 (100,0%)	

*Score distribution in the genital region at month 6 is shown.*



# 4<sup>th</sup> INDERCOS

## Dermatology and Cosmetology Congress with International Participants

27 - 30 MARCH, 2019  
HILTON ISTANBUL BOSPHORUS HOTEL  
ISTANBUL, TURKEY



### PP-46

#### CHRONIC WIDESPREAD PAIN IN PATIENTS WITH CHRONIC SPONTANEOUS URTICARIA

Ragıp Ertaş<sup>1</sup>, Kemal Eroğlu<sup>2</sup>

<sup>1</sup>Department of Dermatology, Kayseri City Hospital, Kayseri, Turkey

<sup>2</sup>Department Rheumatology, Kayseri City Hospital, Kayseri, Turkey

**BACKGROUND AND AIMS:** Chronic spontaneous urticaria (CSU) is a chronic, common and debilitating disease and associated with severely impaired quality of life (QoL). The main aims of this study are to explore the presence of Chronic Widespread Pain (CWP) in patients with CSU and to reveal the possible associations between CWP and CSU on the clinical features, laboratory markers and urticaria activity scores with QoL.

**METHODS:** We assessed the 91 patients with CSU for CWP in a tertiary outpatient clinic. CWP (pain in four or more out of five bodily regions, i.e. the four quadrants and axially at least for three months) was assessed in a rheumatology outpatient clinic in patients with CSU. Patients disease activity were assessed by the urticaria control test (UCT), urticaria activity score (UAS) and visual analog scale of physician and patient's global assessment. Furthermore, patients completed a questionnaire to assess the quality of life (QoL) for dermatologic diseases.

**RESULTS:** Of the 91 patients with CSU assessed for CWP, 23 (25.3%) were positive. CWP +ve patients with CSU had significantly higher physician global assessment score ( $p=0.003$ ), Patients global assessment score ( $p=0.005$ ), UAS ( $p=0.046$ ), dermatologic QoL ( $p<0.001$ ) and lower UCT ( $p=0.005$ ) scores. Nine of 23 CWP +ve patients had asthma (39.1%) as a comorbidity ( $p=0.008$ ).

**CONCLUSIONS:** The presence of CWP in patients with urticaria may have a negative impact on the quality of life of the patients and disease scores.

**Keywords:** Chronic Spontaneous Urticaria, Chronic Widespread Pain, Urticaria control test urticaria activity score, Quality of Life (QoL)





# 4<sup>th</sup> INDERCOS

## Dermatology and Cosmetology Congress with International Participants

27 - 30 MARCH, 2019  
HILTON ISTANBUL BOSPHORUS HOTEL  
ISTANBUL, TURKEY



PP-47

### A CASE REPORT OF RHINOPHYMA SUCCESSFULLY TREATED WITH FRACTIONAL CO2 LASER

Tubanur Çetinarşlan<sup>1</sup>, Cemal Bilaç<sup>1</sup>, M. Kürşat Evrenos<sup>2</sup>, Aylin Türel Ermertcan<sup>1</sup>

<sup>1</sup>Department of Dermatology, Manisa Celal Bayar University, Manisa, Turkey

<sup>2</sup>Department of Plastic and Reconstructive Surgery, Manisa Celal Bayar University, Manisa, Turkey

**INTRODUCTION:** Rosacea is a chronic inflammatory disorder characterized by telangiectasia, erythema, papules and pustules on the central face. Rosacea has been classified into the following 4 subtypes: erythematotelangiectatic rosacea, papulopustular rosacea, phymatous rosacea and ocular rosacea. Rhinophyma, a late complication of rosacea (phymatous subtype), is a chronic, progressive dermatological condition. The classic presentation of rhinophyma is nodular, thickened skin over the distal nose, and is often accompanied by underlying erythema secondary to inflammation. Due to the unpleasant aesthetic and disfiguring appearance, rhinophyma may be associated with a significant negative psychosocial impact, resulting in decreased patient quality of life.

**CASE:** A 48-year-old male patient with a history of rosacea and rhinophyma came to our cosmetology clinic. The patient sought treatment for rhinophyma that was causing nasal obstruction and nasal deformity. He did not respond to the previously given topical and systemic treatments. Fractional CO2 laser treatment was started after informing about the general information about the laser therapy, possible side effects, risks and issues. The patient was prepped and draped in a sterile fashion, 1% lidocaine with 1:100,000 dilution of epinephrine was used for anesthesia of the nose. After the local anesthetic injected, the fractional CO2 laser treatment was performed at 8.0-25.0 W, 74 mJ/dot, one pass once a month (surgical mode with YouLaser). Two sessions of laser treatment were performed. As the patient was satisfied with the treatment, no other sessions were applied.

**CONCLUSION:** Rhinophyma cause marked cosmetic and physiologic problems for the patients. Many surgical treatments have been advocated, as well as dermabrasion and laser therapy. However, all treatments have their advantages and disadvantages. Scalpel excision, dermabrasion and cryosurgery are all fast procedures that offer ease in handling, but they provide little to no hemostasis. Also topical and oral antibiotics and retinoids have been shown effective for this purpose. However, there is no conclusive evidence showing that medication alone can cause regression of rhinophyma. Invasive techniques remain the best treatment modality. Fractional CO2 laser treatment could be considered as a treatment option for rhinophyma.

**Keywords:** Rhinophyma, treatment, laser



# 4<sup>th</sup> Indercos

## Dermatology and Cosmetology Congress with International Participants

27 - 30 MARCH, 2019  
HILTON ISTANBUL BOSPHORUS HOTEL  
ISTANBUL, TURKEY



**PP-48**

### **CUTANEOUS METASTASIS OF MICROPAPILLARY BREAST CARCINOMA OF A FEMALE PATIENT; A CASE REPORT**

*Selen Gökçel<sup>1</sup>, Yasemin Yuyucu Karabulut<sup>2</sup>, Ümit Türsen<sup>1</sup>*

<sup>1</sup>*Department of Dermatology, Mersin University, Mersin, Turkey*

<sup>2</sup>*Department of Pathology, Mersin University, Mersin, Turkey*

Invasive micropapillary carcinoma is an aggressive and rarely seen histologic subtype of invasive breast carcinomas in which cohesive tumor cells are seen in clusters and consist of clear intracytoplasmic spaces. This subtype has a considerably high level of tendency to metastasis to lymph nodes. In this case report, we describe a 53-year-old female patient presented with an erythematous papular lesion seen on the previous surgery site 2 years after the right modified mastectomy surgery. Histopathologically in hormone receptor analysis estrogen and progesterone receptors are demonstrated positive, Cerb-B2 was negative.

**Keywords:** breast cancer, skin metastasis, micropapillary variant

**Organization Secretariat**



**FIGÜR CONGRESS & ORGANIZATION**

19 Mayıs Mah. 19 Mayıs Cad. Nova Baran Center No:4 34360 Şişli / İstanbul – Turkey

Phone: 0 212 381 46 00 / Fax: 0 212 258 60 78

E-mail: [indercos@figur.net](mailto:indercos@figur.net)



# UMORFIL®

Beauty Fiber®

## *Sleeping for Beauty*

Umorfil mattress ticking cares your skin throughout sleep with its all natural structure and helps you to reveal the sparkling beauty within you.

Umorfil yatak kumaşı tamamen doğal yapısıyla uyku boyunca cildinize bakım yapar, içinizdeki ışıltılı güzelliği açığa çıkarmanıza yardımcı olur.



Let's Sleep Better



BoyteksTekstil



BoyteksTekstil



BoyteksTekstil



Boyteks

[www.boyteks.com](http://www.boyteks.com)

**BOYTEKS**

UPSIDE

Jacquard Woven & Knitted Mattress Ticking